Ministry of Health

Secretariat General

Office 2

Clinical recommendations in odontostomatology

September 2017

PREFACE

The World Health Organization considers oral health as an essential part, not only of the General State of Health, but also of the quality of life of each individual.

With this in mind, in agreement with and with the support of the professional world and the scientific community of this discipline, the clinical recommendations in odonto-stomatology included in this volume provide indications and define standards of intervention for the prevention and treatment of the most common diseases of the oral cavity as well as for the identification of the appropriate therapeutic paths in support of public and private operators.

Moreover, they constitute a useful tool to maintain a high level of quality of care especially at this time, in which, on the one hand, the technical opportunities for care are increasing as their potential demand, on the other hand the reduction of the economic resources available to the citizens tend to restrict access to private professional care and, at the same time, the processes of rationalization of the allocation of funds in the NHS make access to the public facilities more difficult.

The identification of clearly defined and published clinical recommendations can facilitate sharing of the objectives and protocols between dentists and patients, improving the communication and, lastly, increase trust both in terms of a specific professional figure and more generally in terms of the "system of care". The revision of the "Clinical recommendations in odontostomatology" was necessary in consideration of the change in the scientific evidence, the arrival on the market of new materials and the use of new technologies, especially in the prosthetic area.

As for the previous one, a large group of contributors contributed to this edition teachers and experts of the single dental branches together with the most important and representative Professional associations and members of the National Board of Dentists (CAO).

The Minister of Health

On. Beatrice Lorenzin

This document is the updated edition of the "Clinical Recommendations in odontostomatology "edited by the Ministry of Health in the year 2014.

The Ministry of Health and, in particular, the Technical Group on Dentistry (components: Giovanni Nicoletti - coordinator, Claudio Arcuri, Pio Attanasi, Gianfranco Carnevale, Benedetto Condorelli, Fausto Fiorile, Roberto Gatto, Enrico Gherlone, Giuseppe Marzo, Antonio Federici, Michele Nardone, Gianfranco Prada, Giuseppe Renzo, Laura Strohmenger), operating at the General Secretariat pursuant to the Ministerial Decree of 14 April 2015, considered it necessary to update the contents in consideration of the evolution of the scientific knowledge and of data present in the literature. The preparation of the technical contents has been assigned to the dental scientific societies coordinated by the Italian Federation of Dental Scientific Societies (CIC Odontoiatria- president: Gianfranco Carnevale) who identified the authors of the different chapters. Always on a mandate of the Technical Group on dentistry,the scientific coordination was assigned to the President of the College of dental university professors, Enrico Gherlone, while the verification of ethical and deontological aspects of the content has been delegated to the Commission of the Register of Dentists –CAO (Stefano Almini, Rodolfo Berro, Corrado Bondi, Giovanni Braga, Gaetano Ciancio, Gianpaolo from Milan, Antonio Di Bellucci, Luigi Di Fabio, Andrea Donati, Massimo Gaggero, Roberto Gozzi, Giuseppe Lo Giudice, Giovacchino Raspini,Giuseppe Renzo, Sandro Sanvenero, Andrea Senna, Alessandro Zovi). The document has been revised by delegates of Ministry of Health (Franco Condò, Giovanni Nicoletti, Michele Nardone, Sabrina Ziliardi), of the National Association of Italian Dentists - ANDI - (Nicola Esposito, Massimo Gaggero,Gerardo Ghetti, Alberto Libero, Stefano Mirenghi, Aldo Nobili, Gianfranco Prada, MauroRocchetti), of the Italian Association of Dentists - AIO - (Fausto Fiorile, Pierluigi Delogu,Pierluigi Martini, Denis Poletto, Angelo Raffaele), of the Italian Dentists Association -ADI-(Roberto Gatto, Giuseppe Marzo) and of the public dental specialist union- SUMAI - (Members of the National Dental commeetee coordinated by Pio Attanasi). The recommendations relating to each topic have been drawn on the basis of the scientific evidence obtained by reviewing articles published in good impact factor? journals of the sector while, in absence of scientific evidence, the recommendations were formulated on the basis of discussion among the authors and the results of consensus conference. These procedures guarantee professionals and all the people involved in the management of oral health the most up to date knowledge in terms of odontostomatology, in order to allow the application of correct and adequate diagnostic and therapeutic aids

Authors

Enrico Gherlone – Coordinator-, Silvia Allegrini, Susanna Annibali, Luigi Baggi, Ersilia Barbato, Antonio Barone, Elio Berutti, Giovanni Braga, Roberto Branchi, Franco Brenna, Alfonso Caiazzo, Vincenzo Campanella, Giuseppina Campisi, Guglielmo Campus, Paolo Capparé, Santo Catapano, Francesca Cattoni, Arnaldo Castellucci, Filippo Cazzulani, Marco Cicciù, Leonardo Ciocca, Giancarlo Cordasco, Elisabetta Cotti, Paola Cozza, Luca Dal Carlo, Giulio Del Mastro, Claudio De 4 Nuccio, Federico De Nuccio, Giulio Del Mastro, Roberto Deli, Carlo Di Paolo, Raffaella Docimo, Stefano Eramo, Giampietro Farronato, Pietro Ferrante, Marco Ferrari, Francesco Ferrini, Fausto Fiorile, Pierluigi Floris, Alberto Fonzar, Federica Fonzar, Mario Gabriele, Massimo Gagliani, Giuseppe Gallina, Livio Gallottini, Gabriella Galluccio, Gianfranco Gassino, Giorgio Gastaldi, Claudio Gatti, Roberto Gatto, Michele Giannatempo, Simona Giani, Maria Rita Giuca, Michele Giuliani, Carlo Guastamacchia, Luigi Guida, Gregorio Laino, Luca Landi, Claudio Lanteri, Mario Lendini, Alberto Libero, Giuseppe Lo Giudice, Lorenzo Lo Muzio, Lucio Lo Russo, Guido Maria Macaluso, Marco Magi, Alessandra Majorana, Vito Antonio Malagnino, Augusto Malentacca, Michele Manacorda, Giovanni Manes Gravina, Edoardo Manfredi, Daniele Manfredini, Francesco Mangani, Piero Alessandro Marcoli, Roberto Martina, Sergio Matarasso, Marco Meleti, Costanza Micarelli, Francesco Occipite Di Prisco, Marco Oddera, Giorgio Perfetti, Gabriele Piana, Paolo Picchioni, Andrea Pilloni, Roberto Pippi, Silvia Pizzi, Carlo Poggio, Bruno Pollifrone, Carmelo Pulella, Angelo Putignano, Eugenio Raimondo, Sandro Rengo, Francesco Riccitiello, Sebastiano Rosa, Roberto Rozza, Gilberto Sammartino, Andrea Sardella, Maria Teresa Sberna, Gehrard Konrad Seeberger, Marzia Segù, Roberto Spreafico, Eugenio Tanteri, Fabio Tosolin, Leonardo Trombelli, Mauro Venturi, Paolo Vigolo, Fernando Zarone, Vittorio Zavaglia, Silvia Zovi.

The Italian version of the "Clinical Recommendations in odontostomatology " edited by the Ministry of Health in the year 2017 have been translated in English in order to provide the European dental Community with a document which is missing and can be useful for all European countries.

Cic Odontoiatria (Italian Association of dental Scientific Societies) offered through its President Gianfranco Carnevale, who is a member of the Technical Group on Dentistry, to organize and provide this translation in English.

Most of the Scientific Societies which are united in Cic Odontoiatria participated, i.e.:
Aic (http://www.accademiaitalianadiconservativa.it/),
Aie (https://www.accademiaitalianaendodonzia.it), Aig (http://www.aignatologia.it/),
Aiom (http://aiom-micro.it/), Aiop (http://www.aiop.com/), Aisi (http://www.aisiitalia.com/),

Iao (https://www.iao-online.com/), Sidco (http://www.sidcoinforma.it/), Sido (http://www.sido.it/), Sidp (http://www.sidp.it), Sie (https://www.endodonzia.it/).

Some chapters were translated by: Cduo (http://www.collegiouniversitariodiodontostomatologia.it/), Sipmo (http://www.sipmo.it/), Sioh (https://www.sioh.it) and Siopi (http://siopi.it).

INDEX

NORMATIVE, DEONTOLOGICAL AND COMMUNICATION NOTES

The dental profession is regulated by the laws of the state.

Law of 24 July 1985, no. 409 as subsequently amended - Establishment of the dental profession of dentistry and provisions concerning the right of establishment and the free provision of services by dentists who are citizens of Member States of the European Communities

Art. 1 - *The health profession of dentistry is hereby established, and shall be exercised by those who hold a degree in Dentistry and Dental Prosthetics and the relative qualification for professional practice, obtained after passing a special state examination, as well as by graduates in Medicine and Surgery who are in possession of the relative qualification for professional practice and a diploma specialising in the dental field.*

The following can practice dentistry:

- Graduates in Dentistry and Dental Prosthetics;
- Graduates in Medicine and Surgery qualified for professional practice who began their university education in medicine prior to 28 January 1980;
- Graduates in Medicine and Surgery qualified for professional practice who began their university education after 28 January 1980 and prior to 31 December 1984, provided they have passed the specific aptitude test pursuant to Legislative Decree no. 13 October 1998, no. 386;
- Graduates in Medicine and Surgery qualified for professional practice who began their university education after 28 January 1980 and prior to 31 December 1984 and who hold one of the three-year specialisation diplomas whose titles were indicated in Ministerial Decree 18 September 2000 by the Ministry of Health, namely: Dentistry and Dental Prosthesis; Oral and Dental Surgery; Odonto-stomatology; Orthognathic Surgery.
- Graduates in Medicine and Surgery who began their university education after 31 December 1984 and hold a three-year specialisation degree in the dental field pursuant to the aforementioned Ministerial Decree of 2000, provided, that this specialisation course began prior to 31 December 1994.

Art. 2 - *The object of the dentistry profession includes activities relating to the diagnosis and treatment of diseases and congenital and acquired abnormalities of teeth, mouth, jaws and related tissues, as well as dental prevention and rehabilitation. Dentists can prescribe all the medicines necessary for the exercise of their profession.*

Professional practice requires registration in the Register of Dentists established at the Orders of Surgeons and Dentists of their province of residence, and is possible throughout Italian territory.

The duties of the professional practice of dentistry include compliance with the Code of Medical Ethics, a set of rules inspired by principles of medical ethics.
Within the guidelines contained in the Code of Ethics, particular importance is given to those that regulate the information and communication that the health professional must guarantee to the person being assisted, as well as their consent to the treatment.

Communication is particularly important as an indispensable element for establishing the correct medic/patient behaviour.

Communication represents that set of verbal stimuli aimed at guaranteeing *compliance*, therapeutic alliance, and acceptance of the prevention and/or treatment plan.
The importance of communication in determining human choices and actions is established over time, just the role of language in maintaining behaviour is well noted, even in the presence of adverse or antagonistic external contingencies. Therefore, the recommendation to communicate with the patient should be considered a constant in the teaching of medicine and, implicitly, in dentistry.
The behaviour of the patient is the final outcome, the result of the *management, marketing* and communication activities put in place by the dentist and their *team,* not only within the health facility but also in the patient's life.
The adoption of scientific methods for the management of behaviour now makes it possible to achieve significant therapeutic outcomes, especially in the reduction of "*dental fear* , for example, even in patients with severe cognitive disabilities.
In the present indications, inspired by principles of scientific methodologies and evidence, the (motor, cognitive or emotional) behaviour of the patient is considered to be a variable dependent on the antecedent and consequent stimuli to which the patient is subjected in the relationship with the dentist and their tools. Most of these stimuli are communicational-verbal in nature. Furthermore, the stresses provided by the dental surgery combine to determine the patient's reactions, in combination with the stresses provided by their past and present living environment.
Individual differences in patterns of behaviour that derive from different life stories oblige the dentist to construct a relationship with the patient that is guided by universal principles, laws and paradigms of communication, but with different and unique nuances in their applications for each patient. And this is the deep-seated reason why **no communication can be implemented in a standardised and equal way for everyone.**
Communication with the patient cannot be left to flair or to the improvisation of the moment. As with any medical act, dentistry shall be guided by general laws, which are the result of experimentation,

however words, images and gestures, shall be modulated based on the unique characteristics of the individual patient, in a continuous two-step repetition of the approach to the patient:

- acquisition of information on the current and previous life environments of the person, to get to know the variables on which their behaviour depends;
- identification of the communication methods (i.e. verbal behaviour of the dentist and their delegates) to be adopted in order to obtain the patient behaviours necessary for the choice of treatment plan, *compliance* during treatment, acceptance and satisfaction with the outcomes (therapeutic alliance).

Starting from these traditional and generic settings, a set of operational procedures ("what and how to communicate") are indicated in relation to what is now required, with an integrated approach and peremptory consistency, by the code of ethics, the need for a scientific approach, the purpose of therapeutic efficacy, specific legal obligations and specific suggestions from professional associations. These procedures must be understood as being part of the "treatment time". This concept is widely reported in the code of ethics mentioned above, where article 20 states: *"... in the report, the doctor pursues the care alliance, based on mutual trust and mutual respect for the values and rights, and on comprehensible and complete information, considering the communication time as treatment time."* It appears clear, therefore, that **the time spent communicating with the patient must be considered as treatment time.** Given this ethical prescription, it is necessary to understand what the operational path must be ("how to do what") to pursue the alliance.

According to a first analysis, "mutual trust and mutual respect for values and rights" based on "comprehensible and complete information" appear to be the preliminary instruments for forming the alliance. Subsequently, the remainder of Article 20 specifies how this can be achieved by considering communication time as treatment time.

Time is understood as an instrument for facilitating the alliance with the patient, who must be involved and made a participant. It is necessary to consider that every detail to be explained implies the use of a fraction of time that becomes greater as the more the case proves difficult, or the more the patient is devoid of any specific notion and requires multiple and meticulous clarifications for various reasons.

The method adopted during the first contact with the patient is indispensable for fostering the "alliance", and must demonstrate the attention paid by the professional in considering them a person and not just a "bearer of illness".

The method used in subsequent contacts is of equal importance.

General guidelines for the "first telephone contact"

Operational Aspects

1. ask how they came to hear of the dental surgery;
2. ask the fundamental reason for their request for clinical observation;
3. succinctly describe the ways in which the relationship will be established.

General guidelines for the "first meeting"

Operational Aspects

1. present yourself personally, potentially in a "non-clinical location" such as the studio, the waiting room or the reception room;
2. present any collaborators present, detailing their tasks and characteristics.

General guidelines for "subsequent contact"

Operational Aspects

1. show that you remember details with a cordial tone (revealing them from specific notes taken previously);
2. show that you remember important pathological details (which are also written in detail in the medical record).

It therefore emerges that the "time" factor represents an indispensable resource for the management of the doctor/dentist-patient relationship during every phase, from the case history, to the objective examination, the diagnosis, the prognosis and the treatment.

In particular, **the "active listening technique" is fundamental in the collection of the case history.** This is a relational skill that makes communication an integral part of the diagnostic-therapeutic path. Direct contact *("eye contact")* and undistracted listening favours dialogue, allowing for management of the patient with an overall experience.

Although essential for affirming that communication is treatment time, these aspect described are not sufficient for establishing the alliance relationship that article 20 prescribes, meaning it requires additional resources.

<u>Communication as verbal behaviour: the need for a scientific approach</u>

The human species has become dominant on the planet thanks to its ability to adapt to the environment actively, evolving behaviourally and culturally alongside its genetic evolution. Unlike genetically determined behaviours, commonly defined as innate or instinctive, learned behaviours are selected

from the environment after birth, greatly increasing the *chances* of success and survival for individuals and entire social groups, even in the case of sudden and profound changes in the external environment.
This type of behavioural evolution, which takes place during the life span of the individual, is explained by a scientific paradigm that constitutes the disciplinary matrix of the scientific community concerned with *"behavior analysis*". According to this model of reference, which is known as B.F. Skinner's three-contingency model, behaviour is a function of physical stimuli of the physical environment, according to the formula B = f (A,C), where the term B to the left of the equation represents Behaviour (B), while A and C represent its control variables, namely Antecedents (A) and Consequences (C) respectively.
One peculiar characteristic of *homo sapiens sapiens* is the ability to induce very complex behaviours through a superior activity, commonly defined as communication, or with a more rigorous language, i.e. verbal behaviour, in the Latin sense of *verhunr.* word or thought that finds vocal, written, gestural or mimetic expression. Through this communication activity, it is possible to evoke motor, emotional and cognitive behaviours in a patient. For example, they can be induced to accept the treatment, or to adopt behaviours in *compliance* with the therapist's indications, but also, in case of error, to stop their visits out of fear or to expect unrealistic therapeutic outcomes.
Without going into the merits of complex analyses, it is useful to distinguish the two great classes of verbal stimuli that constitute human communication:

- "Antecedent" verbal stimuli, which precede and evoke the patient's behaviour. This category includes verbalisations commonly called orders, prescriptions, indications, suggestions, exhortations or questions and requests. Examples of antecedents are: "open your mouth!", "try to relax", "why do you think your child won't wear the device?"

  It is important for the dentist to know that the effect of these verbal stimuli, however necessary, is ephemeral. In other words, the therapist cannot be guaranteed that a patient who is prescribed to use an orthodontic device will continue to do so over time. Verbal antecedents evoke behaviours that are already in the patient's repertoire, but do not create them.
- "Consequent" verbal stimuli, which follow the patient's behaviour and modify the probability of future occurrence. This category includes verbalisations commonly called gratifications, compliments, approvals, assents and thanks, or, with adverse effects, offences, denials, reproaches, disagreements, criticisms or disapproval. Other types of verbal consequences have different effects depending on the situation, such as comments and feedback, which can take on a positive or negative value depending on the context. Informing the patient that their "plaque index is 42" will function as a punishment if the previously measured value was lower and will be rewarding if the starting value was higher.

It is important for the dentist to know that the effect of these verbal stimuli depends on their immediacy and their number. In other words, a young patient who is praised by their parents on a daily and immediate basis for using their "Frankel" device will continue to use it over time. If, on the other hand, the same patient were only to receive *feedback* during the monthly check-up, they would almost certainly lose the habit with the passing of time. While antecedents can, at best, only evoke reactions that the patient already has in their repertoire, consequences have the power to profoundly modify the patient's reactions, habits and way of thinking, with significant results. Examples include reducing dental fear, increasing oral hygiene at home, keeping appointment times, establish a relationship of respect with the dentist or accepting a change in the treatment plan with confidence.

According to widespread prejudice, communications with patients mainly have the functions of *marketing,* advertising, persuasion to accept the treatments proposed and to negotiate financial terms. Although this has been established in the dental field for a long time, it should be remembered that communication carries out functions of great importance that also concerns obtaining *compliance* with the treatments on the part of the patient and increasing the clinical success of the interventions.

Communication and therapeutic efficacy.

The functional relationship between communication skills in dentistry and clinical success is well known and has been studied at length. **Listening and persuasive skills can greatly increase the percentages of the proposed therapies that are accepted, and prescribing how to use a device, e.g. an orthodontic device, with authority can greatly increase its effectiveness.** Failure to adopt persuasive verbal measures should be considered a deficiency and a denial of the patient's right to information aimed at encouraging a choice that is truly adequate for solving their clinical and psychological problems. Adopting sterile verbal forms that are not able to guide the patient cognitively and emotionally is negative.

Below are some general rules that are recommended to be followed during all dialogues with the patient. They are capable of bringing about positive effects regardless of the specific circumstances, and are valid in the vast majority of cases.

A particularly delicate role is played by the methods of verbalising the information that requires the patient to give their consent. As is well known, a patient's decision-making process is largely dependent on communication methods, whereas the information-based content of verbal communication only accounts for a small part.

For example, presenting the likelihood of therapeutic failure significantly reduces the likelihood of the intervention being accepted, while looking at the probability of success significantly increases the *chances* of acceptance. Presenting a prognosis with verbal expressions conjugated in the present

indicative will induce a much greater sense of trust in the patient than by presenting the same outcome in the conditional tense. A similar consideration should be made with regard to the frequency of doubtful or irritating forms used, which can be perceived by the patient as a denial of responsibility on the part of the therapist.

List of persuasive forms vs dissuasive forms, presented exclusively by way of non-exhaustive example:

	Persuasive form (*effective)*	Deterrent form (non *effective)*
Diagnostic VS conditional	In the cases of ... you can intervene in two ways; the first has the advantage of ... and ...	In your case, you could act in two ways: the first would allow you to ... or ...
Specific VS generic forms	Over 70% of cases have a completely positive outcome.	Success depends on many variables, which are impossible
Positive VS negative form	Cases like yours have an excellent prognosis	It is not possible to be certain, however much you do this ...
Certain VS uncertain forms	In cases like yours, the optional treatment is ...	When faced with cases like yours, we can attempt to...

Listening to the patient is essential in order to identify the variables that govern their behaviour. The therapist comes to know the predictable reactions to therapeutic, financial and relational proposals, and can acquire information by asking questions and listening with appropriate mimetic and postural activities. Listening activities that include: *looking at the upper part of the face, bringing the torso forward, remaining silent and, above all, nodding.*

The technique used for questions consists of initially posing queries on facts that the patient does not consider confidential *(who, what, where, when)* and only proceeding with the dialogue by asking questions on more personal and reserved topics *(how* or*why)*after having created a climate of trust and confidence.

No patient can accept a treatment or follow an instruction they did not understand. It is obligatory for the therapist to adjust the volume of their voice in order to compensate for background noise or deafness on the part of the interlocutor. Likewise, it is essential to vary tone of voice, lowering it frequently as a sign of closeness and empathy. Speaking slowly is also correlated with the patient's perception of safety, and isolating important phrases or words between silences gives authority.

There is no patient who has not learned to discriminate the relaxing sound of a voice emitted by a mouth with a smile since early childhood. In person or on the phone, the dentist must be able to move their masseter and temporal muscles in such a way that their lips form a smile that reveals the upper incisors symmetrically (a voice produced with a smile that reveals the lower arch goes against ideas of trust and relaxation, consequently compromising the doctor-patient relationship of trust). The habit of smiling while pronouncing words (and not after) when greeting someone on the telephone and in person, during the visit to the dental unit and for the whole presentation of the treatment is the best way to establish a relationship of trust and is a *precondition* for reducing phobic or anxious reactions.
The construction of a relationship of trust based on empathically relating to the patient unfolds through successive phases that are separated in time and space. In general, the following are an example:

Stages	**Purposes and methods of communication**	**Personnel involved**
Telephone call (setting appointment)	• Provide an image of friendliness and efficiency • Make an appointment with a dichotomous choice • Collect preliminary information about the patient • Identify the refferer and the reason for the visit	Administrative/Healthcare Provider staff
Welcome	• Provide an image of friendliness and efficiency • If possible, "be cordial" in relation to the patient's facts • Collect additional information about the patient • Help to complete the medical history form	Administrative/Healthcare Provider staff

Management of the wait	• Put patients and carers at ease • Provide an image of cleanliness and hygiene • Help without the patient having to ask • Guarantee *privacy,* leave the possibility of choice • Prevent anxious/phobic reactions with distracting elements	Administrative/Healthcare Provider staff
Presentation/greetings by the dentist	• Promote an image of professional authority • Give an impression of friendliness and relaxation • Give a sense of competence and preparation	Dentist
Patient management at the dental unit	• "Be cordial" on the patient's personal facts • Smile behind the mask • Maintain eye contact • Collect information on patient reactions • Distract with open questions • Conceal anxiety-causing stimuli (instruments, blood ...) • Provide suggestive stimuli of clinical competence • Indicate technical and technological quality • Evoke emotional responses that decrease anxiety	Dentist and Health Care Provider

Presentation of the treatment plan	• Collect additional information about the patient • Identify expectations • Lay out a brief diagnosis and prognosis • Present all alternative treatment options • Highlight the expected outcomes for each alternative • Argue in terms of the benefits for the patient • State the elected form of therapy without hesitation • Suggest imitative answers • Respond to objections with ad *hoc* techniques • Stress positive decisions in a *soft*way • Say goodbye by "acting cordial" once more, without giving thanks	Dentist
Possible telephone calls to the patient	• Reassure the normality of the *post* operation progress • Collect information on the course *post* operation progress with care (never concern) • Provide or repeat any	Administrative/Healthcare Provider staff
Callbacks for oral hygiene sessions	• Show care (never concern) • Take confirmation of the appointment for granted • Make the importance of the appointment felt • Set a new appointment, if necessary • In the event of a refusal, ascertain the reasons for the no	Administrative staff/any hygienist
Maintaining the relationship over time	• Maintain communication post-intervention • Set up a system of calls and visits for patients who are probably "lost"	Administrative staff and/or team

In the patient's ideal stay within the structure dedicated to the provision of odontostomatological services, **the phase involving the presentation of the treatment represents an important moment, although not the only one, in which the relationship with the patient is consolidated or weakened.** Above all, it is the only phase in which the dentist's role is pre-eminent and unique, while in all the other phases mentioned above communication develops between the patient and the different figures present in the dental structure (secretary, assistant, hygienist and any dentists collaborating with the surgery). Nevertheless, it is absolutely essential to avoid focusing on this phase as the only important step for building the empathic relationship with the patient. The relationship begins with the communication involving all the staff of the surgery/clinic, starting from the first contact.

Implementing all of these behaviours requires a concrete and inexhaustible "ability to perform" on the part of the professional. Indeed, in technical-professional relationships, it is unthinkable to behave with the nonchalance and *relaxation* generally mostly classified as "spontaneity" and which are appreciated on colloquial occasions with family or friends but are inappropriate when dealing with clinical cases, however.

Professional behaviour is a "technical" tool of the profession. Having repeatedly insisted on the concept that communication is an essential component of clinical skills, it follows that the "performance" of behaviours is equivalent to perfect mastery of the tools relating to the manual phase of the activity, such as scalpels, drills or extraction pliers.

It must be kept in mind that none of these approaches has an absolute value if adopted in isolation. It is only their overall integration that will facilitate the perception of the "welcoming" methods up to the alliance.

The alliance can be the primary result of empathy, which is created through the neurological instruments called "mirror neurons". However, it is fundamental that this empathy does not involve the total sharing of problems. In this event, the professional would be overloaded by the same elements that are harmful to the patient, and could even end up hesitating because of so-called professional "*burnout*".

Within the patient-dentist relationship, the acquisition of consent to treatment plays a particularly important role.

According to art. 32 of the Italian Constitution, **nobody can be subjected to medical treatments against their will,** a concept widely reiterated in Article 35 of the Code of Medical Ethics - "*The acquisition of consent or dissent is an act that falls specifically and exclusively with the responsibilities of the doctor, and cannot be delegated. The doctor shall not undertake or continue diagnostic procedures and/or therapeutic interventions without first obtaining informed consent or informed dissent. The doctor shall obtain the patient's consent or dissent in written and signed form, or with*

other methods with equal documentary validity, in the cases provided for by the law and by the Code, and in those foreseeably encumbered by a high risk of mortality or by outcomes that affect psycho-physical integrity in a significant way.

The doctor shall take adequate account of the opinions expressed by minors in all decision-making processes concerning them."

It appears clear that **informed consent is the prerequisite for the legitimacy of every medical act.**

Informed consent must respond to four fundamental principles: it must be explicit, personal, specific and conscious. During the dentist/patient interview, in addition to being concerned with informing the patient about the treatment plan to be implemented, the dentist should also inform them of the alternative options and also why some options are not considered valid, and have therefore been excluded.

The informed consent can be revoked by the patient at any time and must be reacquired in case of a change in the treatment plan. In addition, the health professional has responsibility for errors in diagnosis, therapy or unjustifiably risky technical choices.

When re-informing the patient for the purposes of consent, it is sufficient to outline the complications that are fundamentally and concretely predictable in an exclusive way, avoiding being overly analytical in relation to facts that can only be hypothesised in the abstract. It is advisable to briefly go back over the treatment plan, the expected result and the benefit-risk ratio in relation to alternative techniques. The names of the health professionals at whom the consent is directed and of any other specialists to whom specific interventions will be entrusted must be indicated.

Regarding the form of acquisition of consent, it is currently not mandatory to obtain a written declaration for freelance dental professionals. However, written form is advisable in the presence of complex cases characterised by at least one of the following characteristics: techniques not commonly used in dental practice; treatments not known to most patients or difficult to understand; experimentation with techniques and/or materials; use of biomaterials; care given to minors and special patients.

PAEDIATRIC DENTISTRY

Paediatric dentistry is a branch of odontostomatology concerned with the prevention and treatment of diseases of the oral cavity in individuals of developmental age. In particular:

- primary prevention with regard to assessing the risk of dental caries (low, moderate or high according to the Caries-Risk Assessment Tool (CAT) or Cariogram);
- treatment of early childhood caries (ECC) or baby bottle syndrome, i.e. multiple destructive carious lesions that arise at a very early age and develop quickly, caused by vertical transmission of *Streptococcus mutans* and frequent, long-term sugar intake;
- conservative treatment of milk teeth and immature permanent teeth that are a site of dental caries or lesions;
- early diagnosis and treatment of erosions of milk teeth and permanent teeth based on the presence/absence of associated systemic disease (e.g. gastro-oesophageal reflux, eating disorders, malabsorption and so on), which require an interdisciplinary approach;
- apexification to treat the pulp of milk teeth and immature permanent teeth that are a site of dental caries or traumatic lesions of mineralised tissues;
- early diagnosis and treatment of diseases of soft tissues and oral mucosa;
- early diagnosis and treatment of bad habits (oral respiration, protracted sucking, infantile swallowing pattern) with an interdisciplinary approach;
- minor surgery (extraction of teeth affected by dental caries or irrecoverable lesions of traumatic origin, frenulectomies and supernumerary tooth extraction);
- prosthetic rehabilitation in the case of oligo/anodontia.

Careful examination of the mouth to assess the status of the child's teeth and oral mucosa is an essential part of a specialist paediatric examination. This examination is often difficult and time-consuming in children due to problems that are mainly concerned with developmental changes in the child's mouth during normal growth. Such factors include dental changes that take place between the ages of 6 and 14, mental and physical developments, the fact that children find it difficult to describe and locate painful symptoms and explain timeframes - and the immature status of a child's immune system. Childhood odontostomatological problems must be established and identified at an early stage and managed using a multidisciplinary approach with the aim of starting the child on a targeted programme of preventing, diagnosing and treating oral hard and soft tissue problems. The aim must be to satisfy the ever-changing need to achieve and maintain the child's oral health in accordance with state-of-the-art guidelines and the dictates of society. Close cooperation must be maintained between the paediatrician, dentist, orthodontist and dental hygienist in order to standardise collective, semi-collective and individual actions. Dentists must therefore keep abreast of their field in order to recognise and treat the most common oral diseases. Above all, they must be able to advise and guide,

where possible, effective preventive actions in order to facilitate the information flow and relationship between parents and children.

First visit and behavioural approach

Before embarking on any hands-on work, dentists treating patients of developmental age must be attuned to their young patients' personalities, problems and fears. This will enable them to gain their attention - and the trust of patients and their parents.

It is a good idea to ensure the waiting room is comfortable and child-friendly to allay the child's anxieties. Dentists with patients of developmental age must gear their communication to the individual, paying particular attention to the child's level of maturity. They must use targeted psychological and behavioural strategies designed to encourage full cooperation throughout the dental session.

Strategies must be put in place to allow parents and practitioners to build the therapeutic partnership necessary to achieve common goals. These must set out to resolve the acute stage of the disease but also ensure the introduction of a proper treatment plan. Work necessary to complete the plan must be scheduled and followed up by monitoring oral health practices at home (Smallridge 2000; AAPD 2008).

Appropriate education and preparation is advisable to ensure that the child is psychologically receptive (Werner et al. 2016).

It is a good idea for the child to visit the dentist for the first time at about 18/24 months of age irrespective of whether or not he or she has dental problems (Wolfe et al. 2006, Scottish Intercollegiate Guideline Network 2006)**.**

During the first visit, the child has the opportunity to get to know the operational environment and also the dental staff.

The operating environment should ideally be child-friendly and calming – not anxiety-making.

During the first visit, the dentist must evaluate the health of the child's mouth, hard and soft tissues (gums and oral mucosa) and the temporomandibular joint (TMJ). He or she must check that the dental formula is correct and compatible with the patient's age and that the teeth present are healthy and in a correct occlusal relationship. Bad habits (persistent use of a dummy and thumb-sucking), which can impair the harmonious development of the jaws, must also be checked for.

During the first visit, the child and his or her parents must be taught the fundamental principles of primary prevention and told about the stages of any necessary treatment plan.

Preventing dental caries in milk teeth and permanent teeth

Caries is a disease resulting from a change in the dental plaque biofilm balance leading to a bacterial population that is cariogenic, i.e. acid-producing. This is caused and maintained by frequent intake of easily fermentable carbohydrates (Simonsen, 2002; Mejare et al., 2003). Caries still represents one of the most widespread conditions in the general population and children in particular (Jokovic & Locker 2001, Featherstone 2003, Harris et al. 2004, Guzman-Armstrong 2005, Cleaton-Jones et al. 2006, Hiiri et al. 2006).

Socio-economic and environmental conditions play an important role in the development of dental caries. They also influence oral health habits such as personal oral hygiene and dietary hygiene (Kallestal et al. 2003, Johnson 2004, Whelton 2004, Hugoson et al. 2005, Senna et al. 2005, Nunn 2006).

Since the second half of the 20th century, the prevalence of dental caries has fallen in industrialised countries, including Italy. However, targeted investigations reveal that the disease is still particularly prevalent in Italian children: a disease incidence of approximately 22% was identified at four years of age and approximately 44% at 12 years of age (Nunn et al. 2000, Tinanoff et al. 2002, Campus et al. 2004, Marthaler 2004, Campus et al. 2007b).

In Italy, an almost total absence of local community dental services makes it even more difficult to implement targeted and effective prevention programmes (Strohmenger et al. 2006).

The prevalence of dental caries in Italian children suggests that the entire population may potentially be at risk of caries. Preventive action is therefore required.

Preventive fluoride treatment

The constant presence of sufficient concentrations of fluoride in the oral cavity significantly reduces the risk of caries (Axelsson et al. 2004, Douglass et al. 2004, Petersson et al. 2004, Adair 2006). Fluoride acts:

1. by reinforcing the crystalline structure of enamel through the formation of fluoroapatite;
2. by encouraging the mineralisation of demineralised enamel;
3. by exerting an antimicrobial action, particularly on *Streptococcus mutans*, reducing its ability to adhere to the oral tissues and multiplication times.

Preventive fluoride treatment, meaning the prevention of caries through the use of fluoride, is a cornerstone of caries prevention and necessary in all individuals (Leroy 2003, Weintraub 2003, Twetman et al. 2004, Jones et al. 2005, Kitchens 2005). It may be systemic or topical. Over the years, different means of administering fluoride have been developed. Each of these involves different concentrations, application frequencies and dosages. Methods include fluorinated water, milk, salt, tablets, drops, toothpastes, gels, varnishes and so on (Maturo et al. 2001, Lewis & Milgrom 2003, Marinho et al. 2004, Yeung et al. 2005).

By definition, topical fluoride prophylaxis describes all delivery methods that supply high concentrations of fluoride to the exposed tooth surfaces for a local protective effect. Such methods are not therefore intended to lead to ingestion. Nowadays, the post-eruptive preventive effect of fluoride administered topically is considered more effective than pre-eruptive treatment achieved through systemic administration.

The most commonly used preventive fluoride treatment methods are topical (toothpaste, mouthwashes or gels). This administration method is also able to supply much higher concentrations of fluoride than those contained in drinking water, for example.

The decline in the prevalence of caries recorded in industrialised countries has been mainly attributed to increased use of fluoride toothpastes. Fluoride toothpastes therefore represent a method of administration that is of primary importance in the prevention of caries. However, because children are not yet able to control their swallowing reflex effectively, they tend to involuntarily swallow part of the toothpaste applied during oral hygiene practices at home, which leads to systemic absorption.

Excessive and long-term intake of fluoride (fluorinated water, toothpastes, fluoride supplements and formula milk) during childhood can lead to dental fluorosis. There is also strong evidence that the use of toothpaste containing at least 1000 ppm of fluoride in children up to 5/6 years of age is associated with an increased risk of fluorosis. It is therefore advisable for parents to closely supervise the amount of fluoride toothpaste administered to children during the early years of life (limiting it to a pea-sized amount) to minimise the risk of fluorosis.

To maximise the beneficial effect of fluoride in toothpaste, it is advisable not to rinse or to minimise rinsing after brushing. Fluoride supplements can be used after carefully evaluating the amount of fluoride taken in every day from other sources.

Paediatricians must prescribe fluoride supplements if it is physically difficult to administer fluoride topically through toothpaste or as an additional preventive fluoride treatment method in subjects at risk of caries. This method of preventive fluoride treatment nevertheless requires good compliance by the family.

From 6 months to 6 years of age, preventive fluoride treatment may be administered by using a toothpaste containing at least 1000 ppm of fluoride twice daily in pea-sized doses. If it is physically difficult to use toothpaste as the only method of preventive fluoride treatment and in subjects with a high risk of caries as an additional method to the use of toothpaste:

- from 6 months to 3 years: administer 0.25 mg/day of fluoride in drops;
- from 3 to 6 years: administer 0.50 mg/day of fluoride in the form of drops or tablets.

After 6 years of age, fluoride prophylaxis may be administered by using a toothpaste containing at least 1000 ppm of fluoride twice daily.

Fluoride administration is not currently recommended during pregnancy because its benefits are not satisfactorily supported by the available scientific evidence. With regard to administration method and dosage, it is advisable to consult "*Linee guida nazionali per la promozione della salute orale e la prevenzione delle patologie orali in età evolutiva* [National guidelines for promoting oral health and preventing oral diseases in developmental age]" (Rock et al. 1997, http://www.salute.gov.it 2008) and subsequent revisions (http://www.salute.gov.it 2013)**.**

To sum up, the dentist must prescribe the most appropriate administration method as well as the concentration of fluoride to be used on a case-by-case basis. This must be done after careful assessment of the microbiological risk through the use of appropriate techniques.

Sealing fissures and pits

Sealing fissures and pits of the occlusal surface of teeth is a caries prevention method that has been known and applied throughout the world for many decades (Ahovuo-Saloranta et al. 2004). The method involves mechanically sealing irregularities in dental enamel that are mainly present on the masticatory portion of premolars and, in some cases, on the palatal surface of the anterior teeth. This prevents bacterial colonisation of grooves and fissures.

In children and young people between 5 and 17 years of age, more than 80% of carious lesions arise in irregularities of the enamel located on the masticatory surface; 74% of fissures in permanent molars treated using this method will still be healthy some 15 years later.

Sealing is particularly recommended for the first permanent molars. These teeth are located toward the rear in the mouths of children aged 6-7 and thus not easy to reach with toothbrush bristles.

Sealing is most effective for caries prevention when applied immediately after eruption of the permanent tooth (in the case of the first permanent molars, the ideal time for sealing is between the ages of six and seven). This is because teeth are most susceptible to disease immediately

following eruption and this susceptibility persists for the first two years or so. The sealing remains on the tooth for several years and does not require removal because it wears away over time. If it disappears before two years are up, it should be replaced.

Performing enameloplasty prior to sealing allows any existing carious processes to be identified so that dentists can perform alternative procedures. This may also improve retention of the sealant but does not improve the effectiveness of the preventive procedure.

Fluoride application performed prior to sealing does not seem to have a negative impact on bond strength.

Isolation of the surgical field plays a key role in the clinical success of sealing. Contamination by saliva reduces the strength of the bond between sealant and enamel.

It is essential to follow the guidelines issued by individual sealant manufacturers scrupulously throughout the procedure.

Correct diagnosis can highlight possible contraindications to sealing: pigmented fissures, which must be treated with sealing combined with enameloplasty and minimal carious lesions, for which minimally invasive restorations are recommended.

Prevention of early childhood caries (ECC)

ECC (early childhood caries or baby bottle syndrome) is a particularly severe and rapidly destructive manifestation of dental caries (De Grauwe et al. 2004; Campus et al. 2007a). The main cause of rampant caries lies in prolonged use of a bottle containing sugary substances or milk, even without sugar, taken mainly at night when the saliva flow is greatly reduced.

Clinical symptoms range from enamel demineralisation to complete excision of milk teeth. The clinical location commonly involves the buccal surfaces of the milk teeth in the front sector and quickly spreads to the remaining teeth. The literature reports prevalences ranging from 1% to 12% in industrialised countries and levels in excess of 70% in developing countries and underprivileged population strata, even in high-income countries.The main clinical manifestations of rampant caries are pain, presence of abscesses and fistulas that are often associated with impairment of the child's general state of health, possibly leading to malnutrition. Possible complications of ECC include systemic infections in the form of focal disease and, on a local level, the possibility of developing follicular or root cysts and hypoplasia of the permanent teeth; orthodontic complications including possible loss of canine guidance, loss of space with tooth-socket imbalance affecting permanent teeth and loss of

vertical dimension with an altered profile; functional complications arising due to changes in mandibular kinetics, phonetics and swallowing and, lastly, aesthetic complications due to tooth loss, particularly affecting the frontal group.

This form of caries is often treated by extracting many or all the milk teeth. This is due to the severity of the lesions and the age of affected subjects, who are too young to undergo complicated, long-term conservative treatment with a doubtful prognosis. Endodontic treatment of milk teeth may be more or less complicated depending on the type of lesion and the degree to which the pulp complex is involved. Several variables affect the choice of treatment: patient age, potential pulp involvement with a history of repeated abscesses, the level of root lysis and the presence of any agenesis. Treatments include: pulpotomy, pulpectomy and tooth extraction.

Before choosing the type of treatment, the severity of the lesions, the child's age and behaviour, the risk of caries and the cooperativeness of parents must be considered.

Home prevention measures and clinical measures are highly advisable.

Home prevention includes:

1. controlling transmission of *Streptococcus mutans* between mother and child, e.g. by avoiding sharing the same dishes;
2. not using a sweetened dummy and a bottle containing sugary drinks. It may be useful to advise parents to carry on using a bottle at night for some time if this is an aid to sleep, but it should only contain water;
3. use of home oral hygiene measures from the eruption of the first milk tooth; prior to this it is good practice to clean the child's mouth using a moistened pad whenever sweetened food, drinks or drugs are ingested.

Clinical measures include:

1. topical application of fluoride varnishes or gels;
2. aesthetic and functional rehabilitation of the dental arches (tertiary prevention).

Restoring a milk tooth or young permanent tooth

Total removal of carious tissue

Total removal of carious tissue is a procedure that involves taking out all the carious tissue and replacing it with biocompatible material with physical and chemical properties that enable it to withstand chewing forces and the oral ecosystem (saliva, bacteria and so on). The aim of this treatment

is to carry out minimal interventions with the aim of saving as much healthy tooth tissue as possible while guaranteeing functional recovery rather than considering the appearance of the milk tooth (Banerjee et al 2000; Forgie et al. 2002, Haak et al. 2002, Machiulskiene et al. 2004, Accademia Italiana di Conservativa 2009, Yengopal et al. 2009, Frencken et al. 2012). Final preparation may be performed in two ways:

1. Traditional preparation technique: this involves removing all the carious dentine until all the dentine lining the cavity walls is hard. This technique is now no longer considered necessary and constitutes overtreatment (Fusayama & Kurosaki 1972, Yip & Samaranayake 1998, Boston 2003, Gruythuysen 2010, Innes et al. 2011, Frencken et al. 2012, Schwendicke et al. 2013, Schwendicke et al. 2014, Schwendicke et al. 2014, Schwendicke et al. 2015).
2. Simultaneous non-selective removal of carious dentine: this involves excavating the carious dentine until it is solid in consistency around the pulp.

The consistency of peripheral dentine should be harder (Fusayama & Kurosaki 1972, Kielbassa et al. 2006). Atraumatic Restoration Technique (ART) falls into this category (Kemoli et al. 2009). Simultaneous non-selective removal treatment should be the method of first choice for shallow lesions, if no alternatives are available (milk teeth: non-restorative cavity control technique, sealing, Hall's technique). Using this technique for deep lesions may place the pulp at risk (Banerjee et al. 2000, Boston 2003, Innes et al. 2011, Schwendicke et al. 2013, Schwendicke et al. 2013b, Schwendicke et al. 2014, Schwendicke et al. 2015). Selective removal of carious dentine may be used in such cases. A layer of soft dentine is left near the pulp to avoid accidental pulp exposure while as much dentine as possible is removed in other areas in order to ensure a permanent filling. The consistency of the peripheral dentine must be hard to ensure that the lesion is tightly sealed. Selective removal significantly reduces the risk of pulp exposure.

Composite resins are universally used for anterior and posterior tooth restorations. Several types are commercially available with physical and handling properties suited to different therapeutic indications, even when dental hard tissue has been lost due to trauma and/or dental malformations (Assis et al. 2009).

The use of resin-based material allows a more conservative approach to cavity preparation due to the micro-mechanical and chemical retention guaranteed by enamel etching and dentinal conditioning (Patil et al. 2009). With regard to amalgam use, see Italian Ministry of Health Decree of 10 October 2001 "***Ban on the use, importation and marketing within Italy of dental amalgams not prepared in the form of pre-dosed capsules and precautions and warnings to be included in instructions for the use of dental amalgams marketed in Italy***"

Composite resins are the material of first choice for frontal sectors; successful long-term results have been achieved with such materials for posterior sectors (Unemori et al. 2001, Hickel et al. 2004). Glass ionomer cement can be effectively used for the restoration of milk teeth or as a provisional treatment (Frencken 2010).

At present, there are no definitive guidelines regarding the best filling material for the conservative treatment of milk teeth.

In the conservative treatment of minimally invasive carious lesions, cavity preparation must follow the shape of the lesion (Jacobson & Asgari 2008, Genovese & Olivi 2008) without removing healthy tooth tissue. It is no longer necessary to observe Black's principles, and current guidelines recommend applying minimally invasive techniques (Genovese et al. 2008, Tao & Fried 2009).

Step-by-step preparation of a carious cavity:

1. cavity opening – access to the lesion
2. careful removal of carious tissue
3. assessing cavity size
4. final cavity preparation
5. finishing the margins

Prior to any therapeutic operation, the caries must be properly diagnosed by means of careful physical examination with a speculum and, where necessary, through the use of bite-wing x-rays.

During the working stages it may be advisable to use magnifying optical systems, at the operator's discretion.

Effective isolation of the working field is necessary given the adhesive properties of the filling material and with the aim of preventing bacterial contamination of the exposed dentine.

The extent of the carious process has a directly proportional impact on final cavity size.

During the working stages of restoration, healthy mineralised tooth tissues must be preserved as far as possible given the chosen techniques and materials.

Smooth and seamless cavity edges have a direct impact on the fit of the restoration and its long-term duration.

Use of a turbine handpiece should be limited to initial cavity opening and approximate shaping; the softened dentine should preferably be removed using hand-held instruments or rotary burs fitted to a low/ultra-low speed contra angle handpiece (e.g. green or double green ring).

To avoid damage to the pulp-dentine complex, all operational steps must be carried out under an abundant jet of water.

It is advisable to finalise the shape of the cavity and finish the edges using a medium and/or low speed multiplier handpiece (e.g. green ring).

Before performing the restoration, the pulp must be properly protected to preserve its vitality if the cavity is deep.

If interproximal tooth tissue is lost, cross-sectional or circumferential matrices of appropriate size must be used.

Various materials may be used to restore dental tissue lost due to caries, namely glass ionomer-based cements and composite materials.

Endodontic treatment of milk teeth

The aim of endodontic treatment is to maintain anatomical and functional integrity as well as the health of the tooth and its supporting tissues to prevent possible orthodontic problems and/or infection. Caries and/or the aftermath of dental and alveolar trauma in milk teeth can give rise to abscesses and early loss of space in the arch. This has a negative impact on shedding and formation of the corresponding permanent tooth.

Proper diagnosis of milk tooth pulp condition is essential when formulating the most appropriate treatment (Fuks 2002, American Academy of Pediatric Dentistry 2008). Indications, aims and treatment options depend on whether or not the pulp is vital, based on accurate clinical and radiographic diagnosis. This will make it possible to establish, in particular, the level of pulp involvement, the presence of possible periapical lesions, the degree of root lysis and any involvement of corresponding permanent teeth by inflammatory processes. Milk tooth root formation stage is very important when determining a therapeutic approach. A milk tooth passes through three developmental stages during the time it spends in the mouth:

- stage I - growth and development stage: tooth erupted with root forming;
- stage II - stage of maturation and stabilisation: tooth root is complete;
- stage III - stage of regression: tooth root undergoes resorption (root lysis).

Treatment approach

Milk tooth at stage I	**Milk tooth at stage II**	**Milk tooth at stage III**
1. excavation of caries 2. no pulp exposure: *restoration* 3. pulp exposed: *pulpotomy + restoration* 4. pulp not vital: *partial pulpotomy/pulpectomy + restoration*	1. excavation of caries 2. no pulp exposure: *restoration* 3. pulp exposed: - vital root pulp (no bleeding): *pulpotomy + chamber filling + restoration* - root pulp with inflammation (bleeding present): *pulpectomy + canal filling with resorbable material + restoration* - pulp not vital: *pulpectomy + canal filling with resorbable material + restoration*	1. excavation of caries 2. no pulp exposure: *restoration* 3. pulp exposed: *pulpotomy* - pulp not vital: *partial pulpotomy/pulpectomy or avulsion*

1. Milk tooth pulpotomy

Pulpotomy involves complete removal of chamber pulp tissue if vital tissue is accidentally exposed following trauma, iatrogenic exposure or caries in an asymptomatic tooth (Conti et al. 2009).The aim of treatment is to preserve root pulp in order to guarantee physiological root lysis. Examination must exclude spontaneous pain, sensitivity to percussion or palpation, with a positive response to vitality tests.

Pulpotomy is contraindicated in the presence of swelling, fistulas, abnormal mobility, internal root resorption, pulp calcification or excessive root pulp bleeding (sign of pulp inflammation). When tissue still present within root canals stops bleeding, this clinical sign indicates the absence of pulp inflammation.

Before performing a pulpotomy, it is essential to carry out a preoperative periapical intraoral x-ray, administer anaesthesia and properly isolate the surgical field. After removing all the carious tissue, the pulp chamber is opened using a diamond bur fitted to a turbine handpiece with abundant irrigation, or using a hand-held excavator with a cutting edge. Overheating of root pulp must be avoided. Once all

chamber tissue has been removed using hand-held and/or low/ultra-low speed rotary instruments (green ring or double green ring) the cavity is packed with cotton wool pellets moistened using sterile physiological solution and root pulp haemostasis is established using ferric sulphate-based products (Papagigiannoulis 2002).

Tooth reconstruction using provisional material is preceded by positioning of biocompatible material in the cavity to ensure root pulp integrity without interfering with the physiological process of root lysis. One material used for this purpose is calcium hydroxide. This compound lacks systemic and local toxicity and its basic pH neutralises lactic acid produced by osteoclasts in order to prevent dissolution of the mineral component of dentine (Tronstad et al. 1981, Waterhouse et al. 2000). Calcium hydroxide can also activate alkaline phosphatase, an enzyme that performs a fundamental role in forming hard tooth tissue. It has not yet been scientifically established whether using this compound to treat milk teeth can lead to internal resorption. Calcium hydroxide should in any case be applied to pulp tissue in which good haemostasis has been achieved, though this situation is difficult to establish during the operation. Satisfactory results have also been obtained using Mineral Trioxide Aggregate (MTA) (Ford et al. 1996, Chacko & Kukirose 2006). This is a compound of tricalcium silicate, tricalcium aluminate, tricalcium oxide and silicate oxide that begins to set in hard structures in under three hours, encouraging the formation of hard tissue and promoting rapid cell growth, as seen *in vitro*. The material is placed directly on the root pulp and covered with a moistened cotton pellet to promote setting. Pulp tissue haemostasis is established at this point. The tooth is then reconstructed using provisional material. One week later, the provisional filling and the cotton pellet are removed: if the material has set to a hard consistency, a permanent reconstruction can be performed.

MTA has demonstrated a better ability to maintain pulp tissue integrity than calcium hydroxide. Histological analysis of animal and human pulp tissue shows a lower inflammatory response, lower hyperaemia and less pulp necrosis than with calcium hydroxide. MTA has an antibacterial effect on some facultative bacteria but no specific effect against anaerobic bacteria. It is highly effective in reducing microorganism penetration. It is biocompatible but also bioinductive (Aeinehchi et al. 2003).

Portland cement has been suggested as an alternative to MTA. From a chemical viewpoint, it differs due to the absence of bismuth ions and the presence of potassium ions. It displays similar antibacterial activity and macroscopic properties and offers the advantage of low cost. The available scientific findings, albeit few, are very encouraging and suggest that Portland cement may find extensive uses in clinical practice.

Once pulpotomy has been performed on a milk tooth, if the tooth shows no signs or symptoms of inflammation upon physical examination one week later, permanent reconstruction can be performed using a composite material or glass ionomer cements.

Correct diagnosis of milk tooth pulp condition is essential in order to determine the most appropriate treatment.

Examination must exclude spontaneous pain, sensitivity to percussion or palpation and a history of abscesses. The tooth must be vital.

Before performing a pulpotomy, it is always essential to take a preoperative periapical intraoral x-ray to evaluate the degree of pulp involvement, the presence of possible periapical lesions, the degree of root lysis and any inflammatory involvement of corresponding permanent teeth.

Plexus or truncal local anaesthesia must be performed, with or without adrenaline, depending on the patient's general conditions of health.

During surgical procedures, proper isolation of the surgical field reduces bacterial contamination and protects soft tissues against possible trauma.

Complete removal of carious tooth tissue must precede pulp chamber opening to avoid bacterial contamination.

During operating procedures designed to remove pulp from the chamber, it is important to use abundant irrigation to avoid damaging or overheating root pulp.

Any bleeding from root openings must stop spontaneously within four minutes at most. The next step is to position the chosen material, construct a provisional restoration and carry out a radiographic check.

A permanent restoration must be fitted at least one week later provided there are no signs and/or symptoms of pulp inflammation.

2. Milk tooth pulpectomy

A pulpectomy involves removing all the tooth pulp from the chamber and root in teeth containing pulp that is not vital or irreversibly inflamed as a result of caries or trauma (Tronstad et al. 2000, Hommez et al. 2002, Koshy & Love 2004, Carrotte 2005, Ozalp et al. 2005, American Academy on Pediatric Dentistry 2008, Blanchard & Boynton 2010). This treatment removes the infection and thus controls the bacterial load in the canal system (Bawazir & Salama 2006). Indications for pulpectomy are: necrosis, presence of a fistula, abscesses, spontaneous pain and pain induced by percussion and mobility not connected to tooth shedding.

The factors that influence the endodontic treatment of a tooth mainly include type of root anatomy, difficulty establishing the exact location of the apical foramen due to rearrangement during the physiological process of root lysis and thinness of the chamber floor. During canal instrumentation, special attention must be paid to the adjacent permanent tooth bud.

A periapical intraoral x-ray can establish the possible presence and extent of the periapical lesion, the presence of a bony roof between the milk tooth and corresponding permanent tooth and the degree of root lysis in the tooth to be treated.Thorough diagnosis must be performed to establish whether the tooth must be avulsed if conditions for performing correct endodontic treatment are not met.

After performing local anaesthesia (if the tooth is still partially vital) and proper isolation of the surgical field, treatment involves removal of all carious tissue and creation of correct access to the pulp chamber. Once the root openings have been identified, the canals are initially probed using hand-held files to define the correct working length. An apex locator is of assistance during this stage, used with reference to the preoperative intraoral x-ray.

The next stage is canal pulp removal using hand-held instruments or Ni-Ti instruments fitted to a low/ultra-low speed contra-angle handpiece (e.g. green or double green ring) with torque control according to the required technique. The instrument must work to within 1 mm of the previously measured working length. Canal treatment requires abundant irrigation.

Canal cleaning and shaping must respect tooth root anatomy. Aggressive instrumentation must be avoided because this could damage the permanent tooth buds or could compromise tooth stability by removing too much healthy dentine (Zehnder 2006).

Root canal cleaning is crucial in order to create an environment that is as sterile as possible (Kawashima et al. 2009); this can be carried out using hydrogen peroxide rinses alternating with sodium hypochlorite solutions diluted to 1% (Siqueira et al. 2007). This ensures dissolution of organic matter and cleaning of any side canals, due to their bactericidal action against Gram- and Gram+ bacteria. Because sodium hypochlorite is potentially toxic to tissues, this irrigating solution must be prevented from emerging from the root system. It must be used with particular caution in the event of root lysis or root resorption (Duggal et al. 2005).

Effective canal profiling is important to achieve good contact between the irrigating solution and the root surface. This step is essential to ensure accurate three-dimensional filling of the root system for permanent teeth but not for milk teeth.

Once profiled and cleaned, the canals must be dried using sterile paper cones and then filled with resorbable canal cement. The most commonly used canal cements are iodoform paste combined with calcium hydroxide; zinc oxide eugenol, which has good crown sealing capacity but limited antibacterial activity, is damaging to corresponding permanent teeth and acts as an irritant on periapical tissues;

calcium hydroxide, whose action mechanism seems to be mainly linked to its properties of alkalinity and the presence of calcium ions. It is useful for necrotic teeth with extensive periapical damage; it is more quickly resorbed than zinc oxide eugenol (Mani et al. 2000).
Once the canal system has been filled and provisional obturation has taken place, the patient must be monitored until healing takes place by conducting a series of clinical and radiographic checks. Healing is indicated by the disappearance of signs and symptoms. Permanent filling with composite material or glass ionomer cement is carried out only when healing has taken place.

Thorough diagnosis is necessary to establish whether the tooth must be avulsed if the conditions for performing correct endodontic treatment are not met.

A periapical intraoral x-ray can establish the possible presence and extent of a periapical lesion, the presence of a bony roof between the milk tooth and corresponding permanent tooth and the degree of root lysis in the milk tooth to be treated.

Canal instrumentation must be performed, paying attention to the adjacent permanent tooth bud. It is extremely important to clean root canals thoroughly in order to ensure the environment is as sterile as possible.

It is essential to use resorbable cements that do not damage the permanent tooth in order to fill the canal.

The above recommendations apply to provisional and permanent restorations.

3. Pulp treatment in young permanent teeth with an incompletely formed apex

The main aim of pulp treatment is to maintain the health of the tooth and supporting tissues when the tooth is affected by caries, lesions of traumatic origin or other causes (American Association of Endodontists 1996, 2003, Thompson et al. 2008). Pulp is essential for apicogensis in a newly erupted permanent tooth with roots that are not yet fully formed. Long-term maintenance of a permanent tooth requires a root with a favourable crown/root ratio and dentinal walls that are thick enough to withstand physiological functions. Pulp conservation is therefore a priority in the treatment of newly-erupted permanent teeth, even though a tooth without vital pulp can still remain clinically functional (Bjørndal et al. 1997, Bjørndal & Mjör 2001, Ricketts et al. 2006).
Pulp treatment indications, objectives and type depend on pulp vitality, based on a clinical diagnosis of: - normal pulp (with no symptoms and positive response to pulp sensitivity tests); - reversible pulpitis; - irreversible pulpitis (symptomatic or asymptomatic); - necrotic pulp.

Clinical diagnosis is based on:- full medical history;- past and present dental history, treatments performed, current symptoms and chief complaint, asking the child and his or her parents questions about the characteristics of the pain (location, intensity, duration, spontaneous or induced);- extraoral physical examination, with particular regard to the presence of swelling;- intraoral physical examination of teeth and soft tissues, with particular attention to the presence of swelling and/or fistulas;- x-ray examination (if this can be performed) to diagnose the site and depth of dental caries, root formation stage and presence of periapical problems of endodontic origin (Pereira & Stanley 1981); - clinical tests (palpation, percussion, mobility, pulp sensitivity tests).

Teeth with symptoms such as a history of spontaneous pain and/or signs such as fistulas, swelling that is not of periodontal origin, increased mobility not associated with trauma or exfoliation, radiolucency of the apices or furcation area, radiographic evidence of internal/external resorption are diagnosed as being affected by irreversible pulpitis or necrosis and are appropriate candidates for endodontic treatment.

Teeth affected by short-lived pain attenuated by painkillers, brushing or removal of stimuli in the absence of signs and/or symptoms of irreversible pulpitis are diagnosed as being affected by reversible pulpitis and are appropriate candidates for vital pulp therapy.

It is advisable to document all diagnostic information, therapy and follow-up treatment.

The treatment plan must take into account the patient's clinical history, the value of the tooth in relation to the development and growth of the stomatognathic system, treatment alternatives and the potential for tooth reconstruction.

The option of tooth extraction must be considered when the infectious process cannot be halted using the treatments described in this section, the bony support cannot be recovered, the tooth structure is inadequate to support a restoration or there is excessive abnormal root resorption.

All pulp treatments must be carried out with appropriate isolation of the surgical field in order to minimise bacterial contamination.

Pulp treatment requires regular clinical and radiographic assessment of the treated tooth and its supporting structures. Clinical assessment should be carried out every 6 months. Patients treated for acute dental infection may initially require more frequent clinical reassessment.

Treatment for the pulp of newly-erupted permanent teeth with apices that have not fully formed should be reassessed radiographically six and 12 months after treatment and then at regular intervals, at the practitioner's discretion.

The dentist may be prompted to carry out more frequent reassessments if certain clinical signs and/or symptoms are present in teeth that have undergone pulp treatment

3.a Pulp treatment in teeth diagnosed as having vital pulp and/or reversible pulpitis.

In a tooth with healthy pulp, when all carious tissue is removed, a protective substrate may be positioned in the deepest area of the preparation to minimise pulp damage, promote pulp tissue healing and/or minimise post-operative sensitivity. The protective substrate is a layer of material applied to the dentinal surface adjacent to the pulp in deep cavity preparation. Its aim is to seal exposed dentinal tubules and act as a protective barrier between the filling material or cement and the pulp. Positioning of a thin protective lining is carried out at the discretion of the practitioner, who may use calcium hydroxide, dentinal adhesive or glass ionomer cement. The aim of positioning a protective substrate in the deep area of the preparation is to conserve tooth vitality, promote pulp tissue healing, form tertiary dentine and reduce bacterial microinfiltration. No unfavourable post-treatment clinical signs or symptoms such as pain, sensitivity or swelling should be observed.

- **Indirect pulp treatment**

  Indirect pulp treatment is a procedure performed on a tooth with a diagnosis of reversible pulpitis and deep caries, which would require endodontic treatment if the caries were to be fully removed. Some authors suggest removing the carious tissue closest to the pulp, positioning a protective layer and sealing the tooth without re-entering the cavity to remove affected residual dentine at a later stage. The risk of this approach is accidental pulp exposure or the onset of irreversible pulpitis.

  Other authors suggest a two-stage procedure: removing the dentine at the dentinoenamel junction and the peripheral dentine, leaving the carious dentine overlying the pulp in situ with the aim of changing the environment of the cariogenic bacteria in order to reduce their number; the residual caries is sealed off from the oral biofilm in an attempt to slow or stop the development of caries. The second stage consists of removing the residual caries and positioning a permanent filling. It is most commonly recommended that the interval between both stages should be 3-6 months because this is long enough to ensure formation of tertiary dentine and provide a definitive diagnosis of pulp vitality. Positioning of a restoration with a good marginal seal is essential for both stages.

  The decision over whether to use the one-stage or two-stage technique should be based on individual patient conditions because there is insufficient evidence to establish which approach is best in the long term.

Indirect pulp treatment is indicated in a young permanent tooth with a diagnosis of normal pulp without symptoms of pulpitis or with reversible pulpitis.

The pulp is assessed by means of clinical and radiographic criteria to establish whether it can be considered vital and able to withstand carious attack.

Provisional and/or permanent filling must ensure that the dentine involved is tightly sealed against the oral environment. Tooth vitality should be preserved. After treatment, no signs and/or symptoms should arise such as sensitivity, pain or swelling. There should be no radiographic evidence of abnormal external or internal root resorption or other abnormal changes. Teeth with immature roots must display physiological root development with apicogenesis.

- **Partial pulpotomy for exposure due to caries**

  Partial pulpotomy for exposure due to caries involves removing the inflamed pulp tissue underlying the exposed area to a depth of 1 to 3 mm (or even more) to reach the healthy pulp. Pulp bleeding is controlled by means of bactericidal agents such as sodium hypochlorite (Siqueira et al. 2007) and chlorhexidine before positioning calcium hydroxide (Nosrat & Nosrat 1998) or MTA (Torabinejad & Chivian 1999, Ferris & Baumgartner 2004, Menezes et al. 2004, Holan et al. 2005, El-Meligy et al. 2006, Witherspoon et al. 2006, Bogen et al. 2008). A filling is then performed in order to ensure a tight seal against micro-infiltrations (Rabchinsky & Donly 1993, Loyola-Rodriguez et al. 1994; Duque et al. 2005).

Partial pulpotomy is recommended in a newly-erupted permanent tooth to treat pulp exposure caused by caries where bleeding can be controlled in a few minutes. The tooth must be vital, with a diagnosis of normal pulp or reversible pulpitis.

The residual pulp must remain vital following the partial pulpotomy. After treatment, no signs and/or symptoms should arise such as sensitivity, pain or swelling. There should be no radiographic evidence of abnormal external or internal root resorption, abnormal canal calcification or periapical radiolucency. Tooth with immature roots must display physiological root development with apicogenesis.

- **Partial pulpotomy due to exposure of traumatic origin (Cvek pulpotomy)**

  Partial pulpotomy for pulp exposure of traumatic origin involves removing the inflamed pulp tissue beneath the exposed area to a depth of 1 to 3 mm (or even more) to reach the healthy pulp. Pulp

bleeding is controlled by means of bactericidal agents such as sodium hypochlorite and chlorhexidine before positioning calcium hydroxide or MTA.

White rather than grey MTA is recommended for the anterior teeth in order to reduce the risk of discolouration. Both preparations have demonstrated similar properties.

Pulpotomy is recommended in a vital young permanent tooth with an incomplete apex following traumatic pulp exposure. Bleeding must be controlled after removing the inflamed pulp. Neither the time between the trauma and treatment nor the extent of pulp exposure are critical factors if the inflamed superficial pulp tissue is excised from the healthy pulp.

The residual pulp must remain vital following partial pulpotomy. After treatment, no signs and/or symptoms should arise such as sensitivity, pain or swelling. There should be no radiographic evidence of abnormal external or internal root resorption, abnormal canal calcification or periapical radiolucency. Teeth with immature roots must display physiological root development with apicogenesis.

3.b Treating non-vital pulp

- **Pulpectomy (conventional root canal treatment)**

Pulpectomy in a permanent tooth with a formed apex equates to conventional root canal treatment (endodontic treatment). This must be implemented in the event of pulp exposure, infection or necrosis with the aim of removing infection in the pulp and around the root. In all cases, the entire chamber roof is removed to take out all the coronal pulp tissue and ensure access to the canals. After disinfecting and shaping the root canal system, a three-dimensional filling is performed to tightly seal the canals using a biocompatible, non-resorbable filling material.

Pulpectomy is recommended in permanent teeth with irreversible pulpitis or necrotic pulp in which the root apex is already formed. Specialist treatment is recommended for teeth with roots that have already been treated endodontically with unresolved lesions around the roots and canals that are not accessible by means of an orthograde approach and calcification of the endodontic space (e.g. apicectomy with retrograde treatment).

The x-ray should show correct canal refilling without over-extensions and underfilling. No adverse signs and/or symptoms should arise after treatment (prolonged sensitivity, pain or swelling). There should be evidence that the pre-treatment condition has been resolved without further clinical and/or radiographic damage to tissue around the root.

- **Apexification**

  Apexification is a technique used to bring about closure of the root end in a non-vital permanent tooth with an incompletely formed apex. It involves removal of infected coronal and root tissue and positioning of biocompatible material such as calcium hydroxide in the canals for 2-4 weeks in order to disinfect the endodontic space. Root apex closure is carried out using an apical barrier of MTA. When it is not possible to perform complete closure using MTA, a resorbable collagen-based dressing may be inserted to allow MTA to be positioned in the space at the end of the canal. Gutta-percha is used to fill the residual endodontic space. If the canal walls are thin, the endodontic space can be filled with MTA or composite resin to strengthen the tooth.

Apexification is a technique for non-vital permanent teeth with incompletely formed roots.

After apexification, no signs and/or adverse symptoms should arise (prolonged sensitivity, pain or swelling). There should not be any radiographic signs of external root resorption, root fracture or abnormalities around the root during or after treatment. The root should continue to erupt and the socket should continue to grow (Fairbourn et al. 1980, Mejàre & Cvek 1993, Coll & Sadrian, 1996, Weiner et al. 1996, Katebzadeh et al. 1998, Farooq et al. 2000, Murray et al. 2002, Patino et al. 2002, McDonald et al. 2004, Fuks 2005, Ozalp et al. 2005, Camp et al. 2006, Itota et al. 2006, Oliveira et al. 2006, Zehnder 2006, Mehdipour et al. 2007, Oen et al. 2007).

Paediatric oral surgery

A full medical history must be collected before performing oral surgery on patients of developmental age. Where appropriate, this should be supplemented by specialist consultant visits if there is any concern that emergency intraoperative and/or post-operative situations could arise. An in-depth assessment of the clinical situation is required together with a radiographic analysis. The radiographic evidence can include intra-oral x-rays, orthopantomogram and computed axial tomography (CT scan) (Massler & Savara 1950, Zhu &, King 1995, Whight 1995, Cameron & Widemar 1997, Messner & Lalakea 2000, American Association of Oral and Maxillofacial Surgeons 2001, Cunhaet al. 2001, American Academy of Pediatric Dentistry 1999, 2005, Flaitz 2005).

Special attention must also be devoted to assessing the child's behaviour. In individuals of developmental age, attitudes may change significantly between the preoperative and intraoperative stages. This means that some children may require measures over and above local anaesthesia to control pain and anxiety.

Patient assessment also includes checking for any previous trauma and/or surgical operations in the mouth and jaw region. In the paediatric population, these can have potential adverse effects on growth,

thus significantly increasing risks and complications. Traumatic maxillofacial injuries can have a negative impact on growth and functions. For example, trauma affecting the mandibular condyle region can reduce growth and also limit jaw function due to ankylosis. Surgery required to correct congenital or acquired malformations can also have a negative impact on growth. For example, in cleft palates, palatal scars left after primary palate repair can cause a maxillary growth anomaly.

Due consideration must also be given to the fact that maxillary and mandibular surgery in patients with deciduous and mixed dentition is complicated by the presence of tooth buds. Changes to standard technique may be required to prevent damage to the buds. For example, bone distraction treatment may be a successful way to correct craniofacial anomalies in paediatric patients. However, this technique may be associated with long-term complications (tooth developmental damage, formation of dentigerous cysts caused by positioning pins in the space adjacent to tooth buds) that can cause malocclusion. X-rays and sometimes CT scans may be required to minimise the effects of surgery during tooth development.

Once the medical history is complete, the most appropriate treatment approach for the condition to be treated has been defined and the necessary assessments, as specified above, have been carried out, the dentist must obtain the informed consent of parents/guardians for underage patients.Management of the post-operative period during developmental age is often more complicated than in adults. Particular consideration must be given to calorie intake as well as fluid and electrolyte management. Paediatric patients who need to undergo particularly complex oral and/or maxillofacial surgery must be referred to health facilities with staff who are expert in handling patients of developmental age.

It is important to treat odontogenic infection caused by dental caries, periodontal disease or trauma promptly. If children do not eat due to pain and malaise, they can easily become dehydrated. Infections of the upper facial area often cause facial pain, fever and difficulty in drinking and eating. A differential diagnosis must be carried out to rule out sinusitis because the symptoms and signs of this condition can imitate an odontogenic infection. It is difficult to identify the cause of some infections of the upper facial area. Infections of the lower facial area often cause pain, swelling and lockjaw. They may be linked to the teeth, skin, lymph nodes or saliva glands. Infection of dental origin is often diagnosed if the lower facial area is swollen. Many odontogenic infections are not serious and can be easily managed as an outpatient. Treatments include: endodontic treatment or tooth extraction, incision and drainage. Odontogenic infections associated with systemic signs (high fever, breathing and/or swallowing difficulties, nausea or asthenia) must be treated promptly with antibiotics. In rare cases, complications may arise (e.g. thrombosis of the sinus cavernosus, Ludwig's angina), which must be managed on an in-patient basis.

Anterior maxillary and mandibular milk and erupted permanent teeth (central and lateral incisors and canines), which all have a single conical root, must be extracted using rotational movements (Ericson & Kurol 1988). Care must be taken in order not to apply force to adjacent teeth that could easily become luxated or dislocated due to their root anatomy.

Deciduous molars (van der Schoot et al. 1997)**, which have roots of smaller diameter that are more divergent than permanent molars, should be extracted by applying slow and continuous buccal and palatal/lingual forces.** This allows expansion of alveolar bone and makes space for divergent roots, reducing their risk of fracture. When a mandibular molar is extracted, it is advisable to support the mandible to protect the temporomandibular joint against injury. To avoid extraction or dislocation of the underlying permanent tooth, the relationship between the roots of the milk tooth and the crown of the permanent tooth must be assessed radiographically. It may be advisable to resect the roots of deciduous molars surrounding the crown of permanent premolars to prevent damage to the permanent tooth buds.

When the roots of a milk tooth are fractured, the tooth should be extracted if this is likely to prove an easy process. If the root is very small, located deep down or near to a permanent tooth or invisible despite several attempts to locate it, it is advisable to leave it in situ because it will ultimately be resorbed.

Early diagnosis of an ectopically positioned canine is important to minimise the problem of inclusion. After the third molars, maxillary canines are the second most likely teeth to be affected by inclusion. Periapical x-rays and orthopantomograms are required to locate the potential ectopic position of an included canine. When the cusp of a permanent canine is mesial to or overlies the distal half of the long axis of a permanent lateral incisor root, palatal inclusion of the canine tooth is common. Extraction of the deciduous canine tooth is the treatment of choice when malformation or ankylosis is present. This is done with the aim of correcting palatal inclusion of the permanent canine by creating space and preventing reabsorption of the incisor. One study showed that in 78% of cases, eruption of permanent canine teeth in an ectopic position is corrected 12 months after extraction of the corresponding milk tooth. More specifically, this occurs in 64% of cases when the initial canine position overlaps the lateral incisor by more than half of the root length and in 91% of cases when the initial canine position overlaps the lateral incisor by less than half of the root length. Orthodontic and/or surgical treatment is advisable in cases where there is no improvement in canine tooth position after one year. Consultation with an orthodontist is useful when making a final decision over treatment.

For third molars, an orthopantomogram or periapical x-rays are necessary to determine the presence, position and development of these teeth in late adolescence. The decision to extract or not extract third molars must be taken by halfway through the third decade of life when the probability of disease or abnormalities (dysodontiasis) is highest. If the practitioner decides that the tooth must be extracted, it must be considered that risks associated with early removal are lower than risks of late removal, partly due to the different degree of root maturity. Factors increasing complication risks (coexistence of systemic diseases, location of nerve bundles, history of temporomandibular joint disease) must all be carefully evaluated. It may be necessary to refer patients to other specialists. A review of the literature (1984-1999) nevertheless concluded that there is no evidence to support preventive removal of healthy included third molars. When a decision is taken not to extract a disease-free included third molar, any changes in disease location and/or development must be monitored over time.

Special attention must be paid to the presence, position and development of these supernumerary teeth (Howard 1967, Taylor 1970, Primosch 1981, Russel & Folwarczna 2003)**.** The presence of supernumerary teeth (hyperdontia) seems to be linked to changes in the dental lamina. Some cases of supernumerary teeth can be associated with certain syndromes (e.g. cleidocranial dysostosis) or congenital conditions. In many cases, supernumerary teeth appear as an isolated event. Supernumerary teeth may be present in milk teeth and permanent teeth. In 33% of cases, a supernumerary milk tooth is followed by a corresponding permanent supernumerary tooth. The frequency of supernumerary teeth is greater than 3%, with permanent teeth five times more likely to be affected than milk teeth. Males are twice as likely to be affected as females. Approximately 90% of supernumerary teeth are in the maxillary arch, most commonly in the anterior sector along the median line; in this case the supernumerary tooth is known as a *mesiodens*. A mesiodens must be suspected in the event of asymmetrical eruption or failed eruption of upper incisors, with or without maintenance of the respective milk teeth or in the event of ectopic eruption of an upper incisor. Diagnosis of a mesiodens is confirmed by x-rays (occlusal, periapical and orthopantomagram). Three-dimensional information is required to determine the location of a mesiodens or included tooth. This can be obtained by taking two peri-apical x-rays in two projections at right angles to one another or by means of a tube shift localisation technique (Clark's technique).

Complications determined by supernumerary teeth include delayed and/or failed eruption of permanent teeth, crowding, resorption of adjacent teeth, formation of dental cysts, ossification of the peri-coronal space and crown resorption. Early diagnosis and a prompt treatment plan are important to prevent such complications. Twenty-five percent of mesiodens cases erupt spontaneously and extraction is usually necessary. A mesiodens with a conical, non-inverted shape is more likely to erupt than a mesiodens of

tuberculate and inverted shape. Treatment for a permanent mesiodens that has not erupted involves minimising eruption problems for permanent incisors. Surgical management is affected by the size, shape and number of supernumerary teeth and the patient's dentition stage. Treatment for a non-erupted deciduous mesiodens differs from the treatment of a permanent tooth. Tooth removal is not advised because surgical management could impair underlying bud development. An erupted decidious mesiodens should be left in place, paying attention to eruption of the permanent teeth. Extraction of a non-erupted deciduous or permanent mesiodens is advisable in mixed dentition in order to allow normal eruption of the permanent incisors in the oral cavity. Waiting for at least two thirds of the roots of adjacent incisors to develop means lower risks for developing teeth and still allows spontaneous eruption of incisors. In 75% of cases, extraction of mesiodens in mixed dentition allows spontaneous eruption and alignment of adjacent teeth. Surgical exposure and orthodontic treatment are required if adjacent teeth do not erupt during the next 6-12 months.
If diagnosis is difficult and complex, it is important to draw up a treatment plan after multidisciplinary dental consultation.

In paediatric patients, no treatment is required for lesions such as Epstein pearls (Hays 2000)**, dental lamina cysts and Bohn's nodules**. Such lesions disappear during the first three months of life.
The treatment of choice for congenital epulis is surgical excision; healing normally takes place without complications (Lapid et al. 2001, Marakoglu et al. 2002).
The presence of eruptive cysts (made up of soft tissue that arises following separation of the dental follicle from the crown of an erupting tooth, typical of the mandibular molar region), **require different treatment depending on the amount of blood in the cystic fluid.** The presence of blood is secondary to the trauma. If the trauma is intense, the lesion fills with blood and is known as an eruptive haematoma. The teeth erupt through the lesion: no treatment is therefore required. If the cyst does not rupture spontaneously or if the lesion becomes infected, the cyst roof must be opened surgically.

If mucoceles (derived from the rupture of a minor salivary gland excretory duct and consequent leakage of mucin into surrounding connective tissues, which can subsequently be surrounded by a fibrous capsule) **are present, the situation must be monitored. Though such lesions often regress spontaneously, leaving ulcerative traces that heal in a few days**, **some may require surgical excision with removal of the minor salivary glands closest to the lesion in order to minimise the risk of recurrence.**

Treatment is required for a high or prominent maxillary fraenulum (which may or may not be associated with diastemas between the incisors) only when the attachment exercises a traumatic force on the gum or causes a diastema that persists after eruption of the permanent canines.

Treatment must always be postponed until the permanent incisors have fully erupted and the diastema has had an opportunity to close naturally. When the patient is older, fraenulum removal may be necessary, if the papilla becomes ischaemic when the upper lip is stretched. Frenulectomy may be carried out only when the diastema has been closed as much as possible following the completion of orthodontic treatment (Hicks 1999, Profitt et al. 2000, Christensen et al. 2005). When indicated, maxillary frenulectomy may be carried out as an outpatient.

If the patient is affected by a high fraenulum in the labial surface of the mandibular ridge, in the area between the lower central incisors (common in individuals with a shallow vestibule), early treatment is recommended to prevent consequences such as inflammation, recession, pocket formation and alveolar bone loss.

A short lingual fraenulum often limits tongue movements (total or partial ankyloglossia) and frenulectomy must be considered on a case-by-case basis (Garcia Pola et al. 2002, Ballard et al. 2002). **Surgical treatment should be considered only if this would improve function**, considering that ankyloglossia can cause problems with breastfeeding, language, correct occlusion and periodontal health. During breastfeeding, a short fraenulum can mean that insufficient milk is transferred to the baby's mouth. It can have a negative impact on feeding and cause pain in the mother's nipple Frenuloplasty, when indicated, seems to be a successful technique to help sucking. Language disorders can also often be associated with ankyloglossia and frenulectomy may therefore be the best treatment option to improve tongue mobility. However, this should not be carried out without a full assessment by a qualified speech therapist. Ankyloglossia has also been associated with class 3 malocclusion. Anomalous tongue position also seems to affect skeletal development, although there is no clear scientific evidence for this.

Frequent monitoring is indicated for natal teeth (teeth present at birth) or neonatal teeth (teeth that erupt during the first 30 days of life). If these are not so mobile that they cause ingestion problems, a conservative approach should be adopted as far as possible.
Incorrect diagnosis and/or inappropriate treatment of Riga-Fede disease, a condition caused by natal or neonatal teeth that rub the ventral surface of the tongue causing ulceration (Goho 1996, Slayton 2000), may cause the child to become dehydrated and undernourished. The treatment should be conservative if possible and consist of polishing rough incisal borders or adding resin to the cutting edges of the teeth. If conservative treatment does not correct the condition, extraction is the treatment of choice. During extraction of a natal or neonatal tooth, special attention must be paid to the possible risk of bleeding (Dodson et al. 1989, Kaban 1990, Rushmah 1991, Lindauer et al. 1992, Ceremello 1993, Mukai et al. 1993, Regezi et al. 1993, Goaz et al. 1994, Neville et al. 1995, Davies et al. 1998, Leonard 1998,

Fernandez et al. 1998, Giancotti et al. 2002, Song et al. 2000, Messner & Lalakea 2002, Lalakea et al. 2003, Seow 2003, McDonald et al. 2004, Dummett 2005, Griffen 2005, Wilson & Montgomery 2005).

Bibliography

Accademia Italiana di Conservativa. Odontoiatria Restaurativa: procedure di trattamento e prospettive future. Ed. Elsevier Masson. 2009, 123-15

Adair SM. Evidence-based use of fluoride in contemporary pediatric dental practice. Pediatr Dent. 2006; 28 (2): 133-42

Aeinehchi M, Eslami B, Ghanbariha M, Saffar AS. Mineral trioxide aggregate (MTA) and calcium hydroxide as pulp-capping agents in human teeth: a preliminary report. Int Endod J. 2003;36:225–31

Ahovuo-Saloranta A, Hiiri A, Nordblad A, Worthington H, Makela M. Pit and fissure sealants for preventing dental decay in the permanent teeth of children and adolescents. Cochrane Database Syst Rev. 2004 (3): CD001830

American Academy of Pediatric Dentistry Clinical Affairs Committee-Pulp Therapy Subcommittee; American Academy of Pediatric Dentistry Council on Clinical Affairs. Guideline on pulp therapy for primary and young permanent teeth. Pediatr Dent. 2008-2009; 30 (7 Suppl):170-4

American Academy of Pediatric Dentistry. Dental development, morphology, eruption and related pathologies. In: Nowak AJ, ed. The Handbook: Pediatric Dentistry. 2nd ed Chicago, III; 1999:7-27

American Academy of Pediatric Dentistry. Guideline on informed consent. Pediatr Dent 2005; 27(suppl):182-3

American Academy of Pediatric Dentistry. Guideline on prescribing dental radiographs for infants, children, adolescents, and persons with special health care needs. Pediatr Dent 2005; 27(suppl):185-6

American Academy on Pediatric Dentistry Clinical Affairs Committee; American Academy on Pediatric Dentistry Council on Clinical Affairs. Guideline on periodicity of examination, preventive dental services, anticipatory guidance/counselling, and oral treatment for infants, children, and adolescents. Pediatr Dent. 2008-2009;30:112-8

American Academy on Pediatric Dentistry Clinical Affairs Committee-Pulp Therapy subcommittee; American Academy on Pediatric Dentistry Council on Clinical Affairs, 2008-2009

American Association of Endodontists. Systematic endodontic diagnosis. Insert to the Fall/Winter edition of ENDODONTICS: Colleagues for Excellence; 1996

American Association of Oral and Maxillofacial Surgeons. Parameters and pathways: clinicalpractice guidelines for oral and maxillofacial surgery (AAOMS ParPath01). J Oral Maxillofac Surg. 2001

Assis CP, Moyses MR, Teixeira HM, Ribeiro JC, Ribeiro JG, Dias SC. Fatigue limits for composite restorations with and without glass ionomer cement liners. Gen Dent. 2009 Sep-Oct;57(5):485-9; quiz 490-1, 535-6

Axelsson S, Soder B, Nordenram G, Petersson LG, Dahlgren H, Norlund A, Kallestal C, Mejare I, Lingstrom P, Lagerlof F, Holm AK, Twetman S. Effect of combined caries-preventive methods: a systematic review of controlled clinical trials. Acta Odontol Scand. 2004; 62 (3): 163-9

Ballard J, Auer C, Khoury J. Ankyloglossia: assessment, incidence, and effect of frenuloplasty on thebreast- feeding dyad.Pediatrics. 2002;110(5):e63

Banerjee A, Kidd EA & Watson TF. In vitro evaluation of five alternative methods of carious dentine excavation. Caries Res. 2000, 34, 144-50

Banerjee, A., Kidd, E. A. & Watson, T. F. 2000. In vitro evaluation of five alternative methods of carious dentine excavation. Caries Res, 34, 144-50

Bawazir OA, Salama FS. Clinical evaluation of root canal obturation methods in primary teeth. Pediatr Dent. 2006 Jan-Feb;28(1):39-47

Bjørndal L, Larsen T, Thylstrup A. A clinical and microbiological study of deep carious lesions during stepwise excavation using long treatment intervals. Caries Res. 1997;31(6):411-7

Bjørndal L, Mjör IA. Pulp-dentin biology in restorative dentistry. Part 4: Dental caries-characteristics of lesions and pulpal reactions. Quintessence Int. 2001;32(9):717-3

Blanchard S, Boynton J. Current pulp therapy options for primary teeth. J Mich Dent Assoc. 2010 Jan;92(1):38, 40-1

Bogen G, Kim JS, Bakland LK. Direct pulp capping with mineral trioxide aggregate: an observational study. J Am Dent Assoc. 2008;139(3):305-15

Boston DW. New device for selective dentin caries removal. Quintessence Int. 2003, 34, 678-85

Cameron A. Widemar R. Oral pathology. In: Handbook of Pediatric Dentistry. London:Mosby. 1997:143-78

Camp JH, Fuks AB. Pediatric endodontics: Endodontic treatment for the primary and young permanent dentition. In: Cohen S, Hargreaves KM, eds. Pathways of the Pulp. 9th ed. St. Louis, Mo: Mosby Elsevier. 2006.834-59

Campus G, Cagetti MG, Solinas G, Sacco G, Majori S, Minelli L, Napoli C, Reali D., Castiglia P, Strohmenger L. The Italian Study Group on Children Oral Health. ECC (Early Childhood Caries) in Italy, pattern and severity. Caries Res 2007a; 41: 299-300

Campus G, Lumbau A, Sanna AM, Solinas G, Luglie P, Castiglia P. Oral health condition in an Italian preschool population. Eur J Paediatr Dent. 2004; 5: 86-91

Campus G, Lumbau A, Sanna AM, Solinas G, Luglie P, Castiglia P. Oral health condition in an Italian preschool population. Eur J Paediatr Dent. 2004; 5: 86-91

Campus G, Sacco G, Cagetti MG, Abati S. Changing trend of caries from 1989 to 2004 among 12-year old Sardinian children. BMC Public Health. 2007b; 7: 28 doi: 10.1186/1471-2458-7-28

Campus G, Sacco G, Cagetti MG, Abati S. Changing trend of caries from 1989 to 2004 among 12-year old Sardinian children. BMC Public Health. 2007b; 7: 28 doi: 10.1186/1471-2458-7-28

Carrotte P. Endodontic treatment for children. Br Dent J. 2005 Jan 8;198(1):9-1

Ceremello P. The superior labial frenum and midline diastema and their relation to growth and development of oral structures. Am J Orthod Dentofacial Orthop. 1993;39(2):120-3

Chacko V, Kukirose S. Human pulpal response to mineral trioxide aggregate (MTA): a histologic study. The Journal of Clinical Pediatric Dentistry. 2006; 30: 203-10

Christensen JR, Fields HW Jr. Treatment planning and management of orthodontic problems. In: Pinkham JR, Casamassimo PS, Fields HW Jr. McTigue DJ, Nowak AJ, eds. Pediatric Dentistry: Infancy through Adolescence. 4th ed. St. Louis, Mo: Elsevier Saunders. 2005: 624-6

Cleaton-Jones P, Fatti P, Bonecker M. Dental caries trends in 5- to 6-year-old and 11- to 13-year-old children in three UNICEF designated regions--Sub Saharan Africa, Middle East and North Africa, Latin America and Caribbean: 1970-2004. Int Dent J. 2006; 56 (5): 294-300

Coll JA, Sadrian R. Predicting pulpectomy success and its relationship to exfoliation and succedaneous dentition. Pediatr Dent. 1996;18(1):57-63

Conti TR, Sakai VT, Camolese Fornetti AP, Silveira Moretti AB, Marchini Oliveira T, Neto NL, Moreira Machado MAA, Camargo Abdo RC. Pulpotomies with portland cement in human primary molars. J. Appl. Oral Sci. 2009; 17 (1): 66-9

Cunha RF, Boer FA, Torriani DD, Frossard WT. Natal and neonatal teeth: review of the literature. Pediatr Dent. 2001;23(2):158-62

Davies J, Turner S, Sandy J. Distraction osteogenesis: A review. Br Dent J. 1998; 14(9):462-7

De Grauwe A, Aps JK, Martens LC. Early Childhood Caries (ECC): what's in a name? Eur J Paediatr Dent. 2004; 5 (2): 62-70

Decreto del Ministero della salute del 10 Ottobre 2001, pubblicato su G.U. n. 261 del 9 novembre 2011

DeRouen TA, Martin MD, Leroux BG, Townes BD, Woods JS, Leitão J, Castro-Caldas A, Luis H, Bernardo M, Rosenbaum G, Martins IP. Neurobehavioral effects of dental amalgam in children: a randomized clinical trial. JAMA. 2006 Apr 19;295(15):1784-92.

Dodson T, Perrott D, Kaban L. Pediatric maxillofacial infections: a retrospective study of 113 patients. J Oral Maxillofac Surg. 1989;47(4):327-30

Douglass JM, Douglass AB, Silk HJ. A practical guide to infant oral health. Am Fam Physician. 2004; 70 (11): 2113-20

Duggal MS, Curzon ME, Balmer R, Roberts J. Potential toxicity. Br Dent J. 2005 May 14;198(9):56

Dummett Co Jr. Anomalies of the developing dentition. In: Pinkham JR, Casamassimo PS, Fields HW Jr, McTigue DJ, Nowak AJ, eds. Pediatric Dentistry: Infancy through Adolescence. 4th ed. St. Louis, Mo: Elsevier Saunders. 2005:61-2

Duque C, Negrini Tde C, Hebling J, Spolidorio DM. Inhibitory activity of glass-ionomer cements on cariogenic bacteria. Oper Dent. 2005;30(5):636-40

El-Meligy OAS, Avery DR. Comparison of mineral trioxide aggregate and calcium hydroxide as pulpotomy agents in young permanent teeth (apexogenesis). Pediatr Dent. 2006;28(5):399-404

Ericson S, Kurol J. Early treatment of palatally erupting maxillary canines by extraction of the primary canines. Eur J Orthod. 1988;10(4):283-9

Fairbourn DR, Charbeneau GT, Loesche WJ. Effect of improved Dycal and IRM on bacteria in deep carious lesions. J Am Dent Assoc. 1980;100(4):547-52

Farooq NS, Coll JA, Kuwabara A, Shelton P. Success rates of formocresol pulpotomy and indirect pulp therapy in the treatment of deep dentinal caries in primary teeth. Pediatr Dent. 2000;22(4):278-86

Featherstone JD. The caries balance: contributing factors and early detection. J Calif Dent Assoc. 2003; 31(2): 129-33

Fernandez E, Bravo LA, Canteras M. Eruption of the permanent upper canines: A radiologic study. A radiologic study. Am J Orthod Dentofacial Orthop. 1998;113(4):414-20

Ferris DM, Baumgartner JC. Perforation repair comparing two types of mineral trioxide aggregate. J Endod. 2004;30(6):422-4

Flaitz CM. Differential diagnosis of oral lesions and develomental anomalies. In: Pinkham JR, Casamassimo PS, Fields HW Jr. McTigue DJ, Nowak AJ, eds. Pediatric Dentistry: Infancy through Adolescence. 4th ed. St. Louis, Mo: Elsevier Saunders. 2005:18

Ford TR, Torabinejad M, Abedi HR, Bakland LK, Kariyawasam SP. Using mineral trioxide aggregate as a pulp- capping material. JADA. 1996;127:1491–4

Forgie AH, Pine CM, Pitts NB.The use of magnification in a preventive approach to caries detection. Quintessence Int. 2002 Jan;33(1):13-6

Frencken JE, Peters MC, Manton DJ, Leal SC, Gordan VV & Eden E. Minimal intervention dentistry for managing dental caries - a review: report of a fdi task group. Int Dent J. 2012, 62, 223-43

Frencken Jo E. The ART approach using glass-ionomers in relation to global oral health care Dental Materials 2010; 26: 1-6

Frencken, J. E., Peters, M. C., Manton, D. J., Leal, S. C., Gordan, V. V. & Eden, E. 2012. Minimal intervention dentistry for managing dental caries - a review: report of a FDI task group. Int Dent J, 62, 223-43

Fuks AB. Current concepts in vital primary pulp therapy. Eur J Paediatr Dent. 2002 Sep;3(3):115-20

Fuks AB. Pulp therapy for the primary dentition. In: Pinkham JR, Casamassimo PS, Fields HW Jr, McTigue DJ, Nowak A, eds. Pediatric Dentistry: Infancy Through Adolescence. 4th ed. St. Louis, Mo: Elsevier Saunders Co. 2005, 375-93

Fusayama T & Kurosaki N. Structure and removal of carious dentin. Int Dent J. 1972, 22, 401-11

Garcia Pola M, Gonzalez Garcia M, Garcia Martin J, Gallas M, Leston J. A study of pathology associated with short lingual frenum. J Dent Child. 2002,69(1):59-62

Genovese MD, Olivi G. Laser in paediatric dentistry: patient acceptance of hard and soft tissue therapy. Eur J Paediatr Dent. 2008 Mar;9(1):13-7

Giancotti A, Grazzini F, De Dominicis F, Romanini G, Arcuri C. Multidisciplinary evaluation and clinical management of mesiodens. J Clin Pediatr Dent. 2002:26(3):233-7

Goaz P, White S. Projection geometry. In: OralRadiology: Principles and Interpretation. 3rd ed. St. Luois, Mo: Mosby. 1994:97-105

Goho C. Neonatal sublingual traumatic ulceration (Riga-Fede disease): Report of cases. J Dent Child. 1996;63(5): 362-4

Griffen Al. Periodontal problems in children and adolescents. In: Pinkham JR, Casamassimo PS, Fields HW Jr. McTigue DJ, Nowak AJ, eds. Pediatric Dentistry: Infancy through Adolescence. 4th ed. St. Louis, Mo: Elsevier Saunders. 2005: 417

Gruythuysen R. Non-restorative cavity treatment. Managing rather than masking caries activity. Ned tijdschr Tandheelkd. 2010, 117, 173-180

Guzman-Armstrong S. Rampant caries. J Sch Nurs. 2005; 21(5): 272-8

Haak R, Wicht MJ, Hellmich M, Gossmann A, Noack MJ. The validity of proximal caries detection using magnifying visual aids. Caries Res. 2002 Jul-Aug;36 (4):249-55

Harris R, Nicoll AD, Adair PM, Pine CM. Risk factors for dental caries in young children: a systematic review of the literature. Community Dent Health. 2004; 21(1 Suppl): 71-85

Hays P. Hamartomas, eruption cysts, natal, tooth, and Esptein pearla in newborn. J Dent Child. 2000;67(5):365-8

Hickel R, Heidemann D, Staehle HJ, Minnig P, Wilson NHF. Direct composite restorations. Extended use in anterior and posterior situations. Clin Oral Invest. 2004, 8:43–44

Hicks EP. Third molar management: A case against routine removal in adolescent and young orthdontic patients. J Oral Maxillofac Surg. 1999;57(7):831-6

Hiiri A, Ahovuo-Saloranta A, Nordblad A, Makela M. Pit and fissure sealants versus fluoride varnishes for preventing dental decay in children and adolescents. Cochrane Database Syst Rev. 2006; (4): CD003067

Holan G, Eidelman E, Fuks AB. Long-term evaluation of pulpotomy in primary molars using mineral trioxide aggregate or formocresol. Pediatr Dent. 2005;27(2):129-136

Hommez GM, Coppens CR, De Moor RJ. Periapical health related to the quality of coronal restorations and root fillings. Int Endod J. 2002 Aug;35(8):680-9

Howard R. The unreruped incisor. A study of postoperative eruptive history os incisors delayed in their eruption by supernumerary teeth. Dent Pract Dent Rec. 1967;17(9):332-41

http://www.salute.gov.it/imgs/C_17_pubblicazioni_2013_allegato.pdf

http://www.salute.gov.it/sorrisoSalute/.../Linee_guida_approvate_10_ott_2008.pdf

Hugoson A, Koch G, Gothberg C, Helkimo AN, Lundin SA, Norderyd O, Sjodin B, Sondell K. Oral health of individuals aged 3-80 years in Jonkoping, Sweden during 30 years (1973-2003). II. Review of clinical and radiographic findings. Swed Dent J. 2005; 29 (4): 139-55

Innes NP, Evans DJ & Stirrups DR. Sealing caries in primary molars: randomized control trial, 5-year results. J Dent Res. 2011, 90, 1405-10

Innes NP, Evans DJ & Stirrups DR. Sealing caries in primary molars: randomized control trial, 5-year results. J Dent Res. 2011, 90, 1405-10

Innes NP, Evans DJ & Stirrups DR. Sealing caries in primary molars: randomized control trial, 5-year results. J Dent Res. 2011, 90, 1405-1

Itota T, Nakabo S, Torii Y, Narukami T, Doi J, Yoshiyama M. Effect of fluoride-releasing liner on demineralized dentin. Quintessence Int. 2006;37(4):297-303

Jacobson B, Asgari A. Restorative dentistry for children using a hard tissue laser. Alpha Omegan. 2008 Sep; 101(3):133-9

Jenkins S, Addy M, Newcombe R. Evaluation of mouthrinse containing chlorexidine and fluoride as an adjunct to oral hygiene. J Clin Periodontol 1993; 20: 20-5

Johnson MF. The role of risk factors in the identification of appropriate subjects for caries clinical trials: design considerations. J Dent Res. 2004; 83

Jokovic A, Locker D. Evidence-based recommendations for the use of pit and fissure sealants in Ontario's public dental health programs. Community Dental Health Services Research Unit. Quality Assurance Report no. 21, 2001.

Jones S, Burt BA, Petersen PE, Lennon MA. The effective use of fluorides in public health. Bull World Health Organ. 2005; 83 (9): 670-6

Kaban L. Infections of the maxillofacial region. In: Pediatric Oral and Maxillofacial Surgery. Philadelphia, Pa: Saunders. 1990:164-88

Kallestal C, Norlund A, Soder B, Nordenram G, Dahlgren H, Petersson LG, Lagerlof F, Axelsson S, Lingstrom P, Mejare I, Holm AK, Twetman S. Economic evaluation of dental caries prevention: a systematic review. Acta Odontol Scand. 2003; 61 (6): 341-6

Katebzadeh N, Dalton BC, Trope M. Strengthening immature teeth during and after apexification. J Endod. 1998;24(4):256-9

Kawashima N, Wadachi R, Suda H, Yeng T, Parashos P. Root canal medicaments. Int Dent J. 2009 Feb;59(1):5- 11

Kemoli AM, van Amerongen WE, Opinya G. Influence of the experience of operator and assistant on the survival rate of proximal ART restorations: two-year results. Eur Arch Paediatr Dent. 2009 Dec; 10(4):227-32

Kielbassa AM, Paris S, Lussi A, Meyer-Lueckel H. Evaluation of cavitations in proximal caries lesions at various magnification levels in vitro. J Dent. 2006 Nov;34(10):817-22. Epub 2006 May 26

Kitchens DH. The economics of pit and fissure sealants in preventive dentistry: a review. J Contemp Dent Pract. 2005; 6 (3): 95-103

Koshy S, Love RM. Endodontic treatment in the primary dentition. Aust Endod J. 2004 Aug;30(2):59-68 Lalakea M, Messner A. Ankyloglossia: Does it matter? Pediatr Clin North Am. 2003;50(2):381-997

Lalakea M, Messner A. Ankyloglossia: Does it matter? Pediatr Clin North Am. 2003;50(2):381-997

Lapid O, Shaco-Levey R, Krieger Y, Kachko L, Sagi A. Congenital epulis. Pediatrics. 2001;107(2):191-2

Leonard M. The maxillary frenum and surgical treatment. Gen Dent. 1998;46(6):614-7

Leroy R, Bogaerts K, Lesaffre E, Declerck D. The effect of fluorides and caries in primary teeth on permanent tooth emergence. Community Dent Oral Epidemiol. 2003; 31(6): 463-70

Levy SM. An update on fluorides and fluorosis. J Can Dent Assoc. 2003; 69 (5): 286-91

Lewis CW, Milgrom P. Fluoride. Pediatr Rev. 2003; 24 (10): 327-36

Lindauer SJ, Rubenstein LK, Hang Wm, Andersen WC, Isaason RJ. Canine impaction identified early with panoramic radiographs. J Am Dent Assoc 1992; 123(3):91-2,95-7. Erratum in J Am Dent Assoc. 1992;123(5):16

Loyola-Rodriguez JP, García-Godoy F, Linquist R. Growth inhibition of glass ionomer cements on mutans streptococci. Pediatr Dent. 1994;16(5):346-9

Machiulskiene V, Nyvad B, Baelum V. Comparison of diagnostic yields of clinical and radiographic caries examinations in children of different age. Eur J Paediatr Dent. 2004 Sep;5(3):157-62

Mani S, Chawla SH , Tewari, A, Goyal A. Evaluation of calcium hydroxide and zinc oxide eugenol as root canal filling materials in primary teeth. Journal of Dent for children. 2000;142-7

Marakoglu I, Gursoy U, Marakoglu K. Congenital epulis: report of a case. J Dent Child. 2002;69(2):191-2

Marinho VC, Higgins JP, Sheiham A, Logan S. One topical fluoride (toothpastes, or mouthrinses, or gels, or varnishes) versus another for preventing dental caries in children and adolescents. Cochrane Database Syst Rev. 2004; (1): CD002780

Marthaler TM. Changes in dental caries 1953-2003. Caries Res. 2004; 38 (3): 173-81

Massler M, Savara BS. Natal and neonatal teeth: A review of the 24 cases reported in the literature. J Pediatr. 1950;36(3):349-59

Maturo P, Costacurta M, Perugia C, docimo R. Fluoride supplements in pregnancy, effectiveness in the prevention of dental caries in a group of children Oral e implantology 2001; 1(2): 23-27

McDonald RE, Avery DR, Dean JA. Management of trauma to the teeth and supporting tissues. In: Dentistry for the Child and Adolescent. 8th ed. St Louis, Mo: Mosby Inc. 2004:455-502

McDonald RE, Avery DR, Weddel JA. Gingivitis and preiodontal disease. In:McDonald RE, Avery DR, Dean JA, eds. Dentistry for the Child and Adolescent. 8th ed St. Louis, Mo: Mosby Co. 2004: 440-41

Mehdipour O, Kleier DJ, Averbach RE. Anatomy of sodium hypochlorite accidents. Compend Contin Educ Dent. 2007;28(10):548-50

Mejàre I, Cvek M. Partial pulpotomy in young permanent teeth with deep carious lesions. Endod Dent Traumatol. 1993;9(6):238-42

Mejare I, Lingstrom P, Petersson LG, Holm AK, Twetman S, Kallestal C, Nordenram G, Lagerlof F, Soder B, Norlund A, Axelsson S, Dahlgren H. Caries-preventive effect of fissure sealants: a systematic review. Acta Odontol Scand. 2003; 61: 321-30

Menezes R, Bramante CM, Letra A, Carvalho VG, Garcia RB. Histologic evaluation of pulpotomies in dog using two types of mineral trioxide aggregate and regular and white Portland cements as wound dressings. Oral Surg Oral Med Oral Pathol Oral Radiol Endod. 2004;98(3):376-9

Messner A, Lalakea M. Ankyloglossia: Controversies in management. Int J Pediatr Otorhinolaryngol 2000;54(2-3):123-31

Messner A, Lalakea M. The effect of ankyloglossia on speech in children. Otolaryngol Head Neck Surg. 2002;127(6):539-45

Mukai S, Mukai C, Asaoka K. Congenital ankyloglossia with deviation of the epiglottis and larynx: Symptoms and respiratory function in adults. Ann Otol Rhinol Laryngol. 1993:102(8Pt1):620-4

Murray PE, About I, Franquin JC, Remusat M, Smith AJ. Restorative pulpal and repair responses. J Am Dent Assoc. 2001;132(4):482-91

Murray PE, Hafez AA, Smith AJ, Cox CF. Bacterial microleakage and pulp inflammation associated with various restorative materials. Dent Mater. 2002;18(6):470-8

Neville B, Damm D, Allen C. Abnormalities of the teeth. In: Oral and Maxillofacial Pathology. Philadelphia, Pa: WB Saunders. 1995:44-95

Neville B, Damm D, Allen C. Odontogenic cysts and tumors. In: Oral and Maxillofacial Pathology. Philadelphia, Pa: WB Saunders; 1995:493-540

Neville B, Damm D, Allen C. Salivary gland pathology. In: Oral and Maxillofacial Pathology. Philadelphia, Pa: WB Saunders. 1995:322-61

Neville B, Damm D, Allen C. Soft tissue tumors. In: Oral and Maxillofacial Pathology. Philadelphia, Pa: WB Saunders. 1995:362-415

Neville B, Damm D, White D. Developmental disturbances of the oral and maxillofacial region. Color Atlas of Clinical Oral Pathology. 2nd ed.Baltimore, Md:Williamss & Wilkins. 2003:10-1

Nosrat IV, Nosrat CA. Reparative hard tissue formation following calcium hydroxide application after partial pulpotomy in cariously exposed pulps of permanent teeth. Int Endod J. 1998;31(3):221-6

Nunn JH, Murray JJ, Smallridge J. British Society of Paediatric Dentistry: policy document of fissure sealants in paediatric dentistry. Int J Paed Dent 2000; 10: 174-177

Nunn JH. The burden of oral ill health for children. Arch Dis Child. 2006; 91(3): 251-3

Oen KT, Thompson VP, Vena D, et al. Attitudes and expectations of treating deep caries: A PEARL Network survey. Gen Dent. 2007;55(3):197-203

Oliveira EF, Carminatti G, Fontanella V, Maltz M. The monitoring of deep caries lesions after incomplete dentine caries removal: Results after 14-18 months. Clin Oral Investig. 2006;10(2):134-9

Ozalp N, Saroğlu, I, Sönmez H. Evaluation of various root canal filling materials in primary molar pulpectomies: An in vivo study. Am J Dent. 2005;18(6):347-50

Papagigiannoulis P. Clinical studies on ferric sulphate as a pulpotomy medicament in primary teeth. Eur J Paediatr Dent. 2002 Sep;3(3):126-32

Patil PS, Chowdhary R, Mandokar RB. Effect of microwave postpolymerization treatment on residual monomer content and the flexural strength of autopolymerizing reline resin. Indian J Dent Res. 2009 Jul-Sep;20(3):293-7

Patino MG, Neiders ME, Andreana S, Noble B, Cohen RE. Collagen as an implantable material in medicine and dentistry. J Oral Implantol. 2002;28(5):220-5

Pereira JC, Stanley HR.. Pulp capping: Influence of the exposure site on pulp healing: Histologic and radiographic study in dog's pulp. J Endod. 1981;7(5):213-23

Petersson GH. Assessing caries risk--using the Cariogram model. Swed Dent J Suppl. 2003; 158:1-65

Petersson LG, Twetman S, Dahlgren H, Norlund A, Holm AK, Nordenram G, Lagerlof F, Soder B, Kallestal C, Mejare I, Axelsson S, Lingstrom P. Professional fluoride varnish treatment for caries control: a systematic review of clinical trials. Acta Odontol Scand. 2004; 62 (3): 170-6

Primosch R. Anterior supernumerary teeth-Assessment and surgical intervention in children. Pediatr Dent. 1981;3(2):204-15

Profitt W, Fields HW Jr, Ackerman J, Sinclair P, Thomas P, Tullock J. The etiology of orthodontic problems. In: Contemporary Orthodontics. 2nd ed. St. Louis, Mo: Mosby Year Book, Inc. 2000:105-38

Rabchinsky J, Donly KJ. A comparison of glass-ionomer cement and calcium hydroxide liners in amalgam restorations. Int J Periodontics Restorative Dent. 1993;13(4):378-83

Regezi J, Sciubba J. Abnormalities of teeth. In: Oral Pathology: Clinical Pathologic Correlations. Philadelphia, Pa: WB Sauders. 1993:494-520

Ricketts DNJ, Kidd EAM, Innes N, Clarkson J. Complete or ultraconservative removal of decayed tissue in unfilled teeth. Cochrane Database of Systematic Reviews 2006, Issue 3. Art. No.: CD003808.

Rock WP, Sabieha AM. The relationship between reported toothpaste usage in infancy and fluorosis of permanent incisors. Br Dent J. 1997; 183: 165-170

Rushmah M. Natal and neonatal teeth: A clinical and Histological study. J Clin Pediatr Dent. 1991;15(4):251-3

Russel K, Folwarczna M. Mediodens: Diagnosis and management of a common sumernumerary tooth. J Can Dent Assoc. 2003; 69(6):362-6

Schwendicke F, Dörfer CE & Paris S. Incomplete Caries Removal: A Systematic Review and Meta-analysis. Journal of Dental Research. 2013a, 92, 306-14

Schwendicke F, Jäger AM, Paris S, Hsu LY & Tu YK. Treating Pit-and-Fissure Caries: A Systematic Review and Network Meta-analysis. Journal of Dental Research. 2015, 94, 522-533

Schwendicke F, Kern M, Blunck U, Dorfer C, Drenck J & Paris S. Marginal integrity and secondary caries of selectively excavated teeth in vitro. J Dent. 2014a, 42, 1261-8

Schwendicke F, Kern M, Meyer-Lueckel H, Boels A, Doerfer C & Paris S. Fracture resistance and cuspal deflection of incompletely excavated teeth J Dentistry. 2013b, 42, 107-113

Scottish Intercollegiate Guideline Network. Prevention and management of dental decay in the preschool child. Austr Dent J 2006;51:272-275

Selwitz RH, Ismail AI, Pitts NB. Dental caries. Lancet. 2007; 369 (9555): 51-9

Senna A, Campus G, Gagliani M, Strohmenger L. Social economical influence on caries experience and CPITN values among a group of Italian call-up soldiers and cadets. Oral Health and Preventive Dentistry 2005; 1: 39- 46

Seow W. Diagnosis and management of unusual dental abdcesses in children. Aust Dent J. 2003;43:156-68

Shenker BJ, Maserejian NN, Zhang A, McKinlay S. Immune function effects of dental amalgam in children: a randomized clinical trial. J Am Dent Assoc. 2008;139:1496-505

Simonsen RJ. Pit and fissure sealant: review of the literature. Pediatr Dent. 2002;24:393-414

Siqueira JF Jr, Rôças IN, Paiva SS, Guimarães-Pinto T, Magalhaes KM, Lima KC. Bacteriologic investigation of the effects of sodium hypochlorite and chlorhexidine during the endodontic treatment of teeth with apical periodontitis. Oral Surg Oral Med Oral Pathol Oral Radiol Endod. 2007;104:122-30

Slayton RL. Treatment alternatives for sublingual traumatic ulceration (Riga-Fede disease). Pediatr Dent. 2000;22:413-4

Smallridge J. UK National Clinical Guidelines in paediatric dentistry. Int J Paed Dent. 2000; 10: 78- 83

Song F, O'Meara S, Wilson P, Goldenr S, Kleijnen J. The effectiveness and cost- effectiveness of prophylactic removal of wisdom teeth. Health Technol Assess. 2000;4(1):1-55

Strohmenger L, Campus G, Castiglia P, Reali D, Montagna MT, Minelli L, Majori S, Cagetti MG, Senna A, Pizzocri J. Indagine epidemiologica nazionale sulle condizioni dento-parodontali dei bambini di 4 e 12 anni. Doctor Os. 2006; 17: 853-866

Tao YC, Fried D. Near-infrared image-guided laser ablation of dental decay. J Biomed Opt. 2009 Sep-Oct;14(5):054045

Taylor GS. Characteristics of supernumerary teeth in the primary an permanent dentition. Trans Be Soc Study Orthod. 1970-71;57:123-8

Thompson V, Craig RG, Curro FA, Green WS, Shop JA. Treatment of deep carious lesions by complete excavation or partial removal, A critical review. J Am Dent Assoc. 2008;139:705-12

Tinanoff N, Kanellis MJ, Vargas CM. Current understanding of the epidemiology mechanisms, and prevention of dental caries in preschool children. Pediatr Dent. 2002;24:543-51

T orabinejad M, Chivian N. Clinical applications of mineral trioxide aggregate. J Endod. 1999;25:197-205

Tronstad L, Andreasen JO, Hasselgren G, Kristerson L, Riis I. PH changes in dental tissues after root canal filling with calcium hydroxide. Journal of Endodontics. 1981;7,:17–21

Tronstad L, Asbjornsen K, Doving L, Pedrsen I, Eriksen HM. Influence of coronal restorations on the periapical health of endodontically treated teeth. Endod Dent Traumatol. 2000;16:218-21

Twetman S, Petersson L, Axelsson S, Dahlgren H, Holm AK, Kallestal C, Lagerlof F, Lingstrom P, Mejare I, Nordenram G, Norlund A, Soder B. Caries-preventive effect of sodium fluoride mouthrinses: a systematic review of controlled clinical trials. Acta Odontol Scand. 2004;62: 223-30

Unemori M, Matsuya Y, Akashi A, Goto Y, Akamine A. Composite resin restoration and postoperative sensitivity: clinical follow-up in an undergraduate program. J Dent. 2001 Jan;29:7-13

van der Schoot EA, Kuitert RB, van Ginkel FC, Prahl-Andersen B. Clinical relevance of third permanent molars in relation to crowding after orthodontic treatment. J Dent. 1997;25:167-9

Waterhouse PJ, Nunn JH, Withworth JM. An investigation of the relative efficacy of Buckley's Formocresol and calcium hydroxide in primary molar vital pulp therapy. British Dental Journal. 2000;188:32-6

Weiner RS, Weiner LK, Kugel G. Teaching the use of bases and liners: A survey of North American dental schools. J Am Dent Assoc. 1996;127:1640-5

Weintraub JA. Fluoride varnish for caries prevention: comparisons with other preventive agents and recommendations for a community-based protocol. Spec Care Dentist. 2003;23: 180-6

Werner H, Hakeberg M, Dahlström L, Eriksson M, Sjögren P, Strandell A, Svanberg T, Svensson L, Wide Boman U. Psychological Interventions for Poor Oral Health: A Systematic Review. J Dent Res. 2016 Jan 29. pii: 0022034516628506

Whelton H. Overview of the impact of changing global patterns of dental caries experience on caries clinical trials. J Dent Res. 2004; 83 Spec No C: C29-34

Whight J.Tongue-tie. J Paediatr Child Health. 1995;31:276-8

Wilson S, Montgomery RD. Local anesthesia and oral surgery in Children. In: Pinkhan JR, Casamassimo PS, Fields HW Jr, McTigue DJ, Nowak AJ, eds. Pediatric Dentistry: Infancy through Adolescence. 4th ed. St.Luois, Mo:Elsevier Saunders. 2005: 454.461

Witherspoon DE, Small JC, Harris GZ. Mineral trioxide aggregate pulpotomies: A series outcomes assessment. J Am Dent Assoc. 2006;137(9):610-8

Wolfe JD, Weber-Gasparoni K, Kanellis MJ, Qian F. Survey of Iowa general dentists regarding the age 1 dental visit. Pediatr Dent. 2006 Jul-Aug;28(4):325-31

Yengopal V, Harneker SY, Patel N, Siegfried N. Dental fillings for the treatment of caries in the primary dentition. Cochrane Database Syst Rev. 2009 Apr 15;(2):CD004483

Yeung CA, Hitchings JL, Macfarlane TV, Threlfall AG, Tickle M, Glenny AM. Fuoridated milk for preventing dental caries. Cochrane Database Syst Rev. 2005; 3: CD003876

Yip HK, Samaranayake LP.Caries removal techniques and instrumentation: a review. Clin Oral Investig. 1998 Dec;2(4):148-54

Zehnder M. Root canal irrigants. J Endod. 2006;32(5):389-98 Zhu J, King D. Natal and neonatal teeth. J Dent Child. 1995;62(2):123-8

RESTORATIVE DENTISTRY

Restorative dentistry is the branch of dentistry dealing with the prevention and treatment of congenital and acquired hard tissue lesions in teeth. Its aims are as follows:

- to eliminate the causal factors of disease;
- to motivate patients to achieve optimal control of bacterial plaque and follow a proper diet;
- to intercept and arrest, if possible, initial decalcifying lesions by non-invasive and re-mineralisation therapies;
- to prevent carious lesions by non-invasive measures (i.e. fissure sealing);
- conventional treatment of hard tissue injuries for maintenance of pulp vitality and prevention of future damage to hard tissues; aesthetic blending of the restoration at normal conversational distance, if this is desired by the patient and clinically feasible.

If restorative dentistry is not accompanied by careful prevention and prophylaxis measures, it only temporarily resolves patient problems and the carious lesions will probably recur. Restorative procedures should therefore ideally be accompanied and followed by individual prophylactic measures. Restorative treatment must be included at the appropriate stage of a work plan that identifies patient problems and links them to one another: it must not focus only on the treatment of carious lesions (Benn 1999). It must include:

1. determination of Patients' expectations and their willingness to cope with dental treatment. Some patients attach great importance to their health and the appearance of their smiles, others only resort to treatment in emergencies while others occupy a middle position between these extremes. Patient assessment from this viewpoint can offer valuable hints about the degree of future cooperation that we can expect during and after treatment (oral hygiene at home and regular check-ups).
2. diagnosis of all carious lesions and assessment, if possible, of their activity level. Correct diagnosis must along with a thorough physical examination, if possible accompanied by bite-wing x-rays (Gowda 2009) and, if indicated, by pulp sensitivity tests and periapical x-rays.
3. determination of superficial and deep periodontal conditions with a view to restorative treatment.
4. determination of the occlusal situation. Different occlusal conditions can influence the choice of techniques and materials to be used.
5. treatment plan. The treatment plan must be explained to the patient, together with any alternative therapeutic approaches.

Dental caries is a disease that can largely be prevented (Fejerskov 1995, Hausen 1997, Elderton 1985, König 1984, Pitts 1998, Powell 1998, Radnai 1999 and Steiner 1990). A good preventive programme

includes oral hygiene sessions, periodic check-ups, application of fluoride by dental professionals and at home (mouth-rinses, toothpaste, etc), instructions for home plaque control and dietary suggestions (Anusavice 1998, Caufield 1997, Ciancio 1997, Do 2009, Edgar 1995, Mandel 1996, Triller 1998 and Van Palenstein Helderman 1996).

Patients with exposed root surfaces (gum recessions, elderly patients and so on) are at greater risk of root caries (Zambon 1995). Such patients must be encouraged to carry out effective cleaning and self-apply fluorides (Zambon 1995). An increased risk of caries is also present in patients taking certain drugs (Ciancio, 1997) or patients with a reduced salivary flow for various reasons (Edgar 1995, König 1984). Any treatment must naturally be preceded by a correct diagnosis (Edward 1997, Lussi 1998, Silverstone 1988, Stecksen-Blicks 1983 and Tveit 1994). As a general rule, the diagnostic value of probing alone should be given less credibility (Hintze 1994, Huysmans 1998, Ie 1995, Machiulskiene 1999, Ricketts 1997, Ricketts 1995, Weerheijm 1992). Thorough visual inspection with the teeth well-dried and free of deposits and pigmentation can offer more information. In doubtful cases, it is useful to carry out bite-wing x-rays (Weiss 1996, Zacharia 1995, Verdonschot 1992, Pitts 1983, Curilovic 1983, Hintze 1993, Verdonschot 1991, de Vries 1990, De Araujo 1992, Hintze 1999, Nyvad 1999, Mejare 1998, Downer 1992).

Dental caries can largely be prevented. Prevention programmes must therefore precede, accompany and follow conservative treatment.

Correct diagnosis of caries and determination of pulp sensitivity must precede any therapeutic procedure.

Any periodontal and occlusal problems should be assessed before undertaking any type of conservative treatment.

All restoration materials, substrates and dentinal adhesives are sensitive to moisture (Hitmi 1999, Lygidakis 1994, Reid 1990, Strassler 1996 and Small 1999). Good isolation of the operative field reduces bacterial contamination of dentine and protects soft tissue from possible trauma. The rubber dam is an excellent system for achieving good isolation (Accademia Italiana di Conservativa 2009, Berglund 1997, Christensen 1994, Kremers 1999, Marshall 1998, Plasmans 1994, Small 1999, Terry 2005, Small 1999 and Zitzmann 1999).

After diagnosing the caries, these must be treated by preserving the healthy mineralised tissues as far as possible. The cavity extension must be limited as far as possible, allowing for techniques and materials

chosen for restoration (Hirt 1987, Leinfelder 1996, Loe 1995, Miller 1997, Osborne 1998, Simonsen 1985) and respect for adjacent teeth (Kutsch 1999, Kielbassa 2006, Haak 2002, Forgie 2002, Accademia Italiana di Conservativa 2009, Lussi 1998, Medeiros 2000 and Moopnar 1991).
Cavity dimensions are directly proportional to the extent of the carious process (Anusavice 1998, Christensen 1996, Freedman 1999, Lderton 1985, Laswell 1985 and Porte 1984). Hard tissue cutting procedures must be performed under abundant water flow to prevent injury to the pulpodentinal complex (Anusavice 1998, Hirt 1987, Laswell 1985 and Porte 1984).
A smooth, unbroken cavity margin has a particular impact on marginal adaptation of the restoration and hence its long term result (Haller 1991, Kidd 1992, Nordbo 1998, Reller 1989 and Stratis 1998). The margin must therefore be finished off using appropriate instrumentation (Haller 1991, Reller 1989).

Cavity preparation must be as conservative as possible, allowing for the techniques and materials chosen for the restoration.

Proper finishing of the margins is recommended as it improves marginal adaptation and has an impact on restoration durability.

Proper isolation of the operative field ensures against contamination by fluids and bacteria while protecting soft tissue from possible trauma. A rubber dam is an excellent way of achieving this isolation.

Cavity preparation: operational steps

1. isolation of the operative field
2. opening of a cavity – access to the lesion
3. excavation of the caries
4. evaluation of cavity size
5. definitive cavity preparation
6. marginal finishing

The resulting preparation is repaired by means of direct restorations (filling) or indirect restorations (inlays). The choice depends on clinical factors (Elderton 1992, Krejci 1993 and Surmont 1990) (presence or absence of enamel on the cervical margin, cavity configuration and complexity, location and access, number of restorations in the same arch, relationships between the proximal and opposing teeth and the patient's age). The size of the residual sound tooth structure is also important (Surmont 1990).

An indirect restoration can generally be more invasive than a direct restoration (Anusavice 1989, Elderton 1992, Mjör 1993 and Surmont 1990). When treating carious lesions of limited extent, it is preferable to perform direct restorations (Krejci 1993 and Surmont 199).

With medium to large carious lesions, it is possible to choose for indirect restorations allowing better morphological restoration of the compromised tooth (Pallesen 2003). Full removal of demineralised and infected tissue is the goal of conservative therapy (Kidd 1996 and Yip 1998).

Softened dentine can be excavated using burs fitted on low/very low speed handpieces or by means of handheld instruments (Smales 1999).

For very deep caries, it is more prudent to excavate the final layers using hand-held tools because these allow greater control of movement thus limiting the risk of accidental pulp exposure (Weerheijm 1999). The dentine must be excavated until hard, compact issue is encountered (Weerheijm 1999). Once the softened dentine has been removed, the pulp must be appropriately protected using methods and materials selected at the discretion of the individual practitioner (Brannstrom 1969, Brannstrom 1971, Brannstrom 1973, Brannstrom 1974, Brannstrom 1976, Brannstrom 1976, Brannstrom 1976, Garberoglio 1985, Leinfelder 1994, Leinfelder 1997 and Strassler 1992).

Cavity preparation must be as conservative as possible given the extent of the carious process. The practitioner chooses the material and technique (direct or indirect).

Proper marginal finishing is recommended to improve marginal adaptation and restoration longevity.

Caries removal is the fundamental stage of conservative therapy.

All softened tissue must be removed until clinically healthy non-demineralised dentine is reached prior to final restoration.

Dentine colour is not a diagnostic indication.

With regard to materials to be used, it is essential to follow strictly the instructions and methods (application times, mixing ratios etc.) established by individual manufacturing companies (Anusavice 1989, Ferrari 1998, Kildal 1997, Krejci 1993, Swift 1995, Unterbrink 1995 and Watts 1992).

For direct restoration of decayed teeth in frontal sectors, the material of first choice is composite resin together with an appropriate bonding system (Davis 1998, Hitmi 1999, Koczarski 1998, Kramer 1994, Newman 1991, Nicolaisen 2000, Portalier 1997 and Peumans 1997).

For the use of amalgam, see Italian Ministry of Health Decree of 10 October 2001. Composite resins, combined with the use of dental adhesives can also produce good long-term clinical outcomes on premolars and molars (Collins 1998, Hickel 1998, Hickel 2004, Plasmans 1998, Qvist 1997, Timothy 2006, Tobi 1998, Van Meerbeek 1992 and Wendt 1996). However, their correct positioning requires greater attention and a more complex operating technique when compared with the use of amalgam (Christensen 1998, Frencken 2010, Liberman 1997, Smales 1993 and Van der Merwe 1993).

Resin-modified glass ionomer cement can be used effectively in paediatric dentistry for restoration of milk teeth or as preventive treatment in disadvantaged subjects (Benz 1998, Burke 1999, Freedman 1997, Frencken 2010, Hawthorne 1997, Hasselrot 1998, Hickel 1998, Hickel 2000, Hickel 2001, Hickel 1998, Hitmi 1999, Kanca 1997, Leinfelder 1998, Liberman 1987, Manhart 2001, Mair 1998, Martin 1997, McKinlay 2007, Mjör 1990, Nordbo 1992 and Smales 1992).

Cast gold restorations continue to be a reliable treatment option (Christensen 1996, Davis 1988, Dietschi 1995, Leinfelder 1998, McLaren 1999, Mjör 1992, Strassler 1996 and Tucker 1996). Furthermore, ceramic and composite resin inlays cemented using bonding techniques have achieved significant levels of clinical reliability (Abel 1998, Behle 1997, Chalifoux 1998, Jokstad 1994, Lacy 1998, Mair 1998, Powers 1998, Raskin 1999, Rees 1997 and Wassell 1995). Dentin bonding systems are an excellent way of anchoring materials to dental tissues (Charlton 1996, Degrange 1990, Donovan 1996, Eick 1997, Frankenberger 1999, Huth 1999, Kreulen 1998, Mjör 1993, Pashley 1997 and Swift 1998). The action of the various chemical products that modify dentine and enamel to promote bonding with composite resin is greatly disturbed by external contamination (blood, saliva, etc.). (Hickel 1999, Liberman 1987, Liebenberg 1997 and Scheibenbogen-Fuchsbrunner 1994).

Proper isolation of the operative field is strongly recommended (Roulet 1997 and Smales 1996).

Pre-prosthetic reconstruction of endodontically treated teeth

A pre-prosthetic restoration can be carried out: using amalgam, with or without an anchorage, retained by a prefabricated root canal post; with composite resin and a resin and glass fibre post cement-bonded with self-curing resin cement – or with a cast abutment post. The adhesive method seems to guarantee better conservation of the tooth structure as well as a chemical and mechanical bond with the dentine (Assif 1989 and Sornkul 1992).

The post should not be considered a tooth reinforcement but a support for the construction material (Mentink 1995). Use of a post is necessary when the height of the pulp chamber is reduced (in molars) or when fewer than three walls remain at coronal level (premolars and anterior teeth) (Helfer 1972, Randow 1986).

Subsequent prosthetic preparation should follow the principle of preserving dentine at cervical level: leaving a band of dentine in the coronal area (encircling the tooth neck) significantly increases the long-term survival of these teeth (ferrule effect) (Hansen 1990 and Sorensen 1990).

In cases where it is not possible to obtain the ferule effect, it is probably advisable to perform a surgical clinical crown lengthening operation and/or, where indicated, orthodontic extrusion (Hansen 1990 and Sorensen 1990). All restorations must be finished and polished, irrespective of the material used (Lutz 1983).

Finishing and polishing is performed using instruments and burs with decreasing cutting action (Herrgott 1989, Krejci 1984 and Lutz 1983). A smooth and polished surface is less retentive for bacterial plaque and helps achieve a good marginal fit (Briand 1990, Hondrum 1997, O'Brien 1984 and Schmid 1991).

Once the patient has completed the conservative treatment process, a maintenance programme must be recommended, involving check-ups and professional oral hygiene sessions with the possible application of topical fluorides (Axelsson 1978, Axelsson 1991 and Axelsson 1991). The uncontrolled presence of bacterial plaque naturally increases the risk of secondary caries for any restoration (Marthaler 1993). Patient cooperation is therefore a positive discriminator for the long-term success of conservative therapy.

Correct material insertion and handling is a crucial stage when performing any restoration.

The restoration should not interfere with occlusal dynamics.

The cervical margins must be contoured in order not to irritate the periodontal tissues.

A smooth and polished restoration surface is less retentive for bacterial plaque. This reduces the risk of recurrent caries and inflammation of marginal tissues.

Regular check-ups and re-polishing of the restorations, if necessary, contributes to their longevity.

Bibliography

Abel MG. In-office inlays with today's new materials. Dent Clin North Am 1998; 42: 657-64.

Accademia Italiana di Conservativa. Odontoiatria Restaurativa: procedure di trattamento e prospettive future. Ed. Elsevier Masson 2009; 123-151.

Accademia Italiana di Conservativa. Odontoiatria Restaurativa: procedure di trattamento e prospettive future. Ed. Elsevier Masson 2009; 123-151.

Anusavice KJ. Management of dental caries as a chronic infectious disease. J of Dent Educ 1998; 62: 791- 802.

Anusavice KJ. Criteria for selection of restorative materials: properties versus technique sensitivity, in Anusavice KJ (ed): Quality Evaluation of Dental Restorations: Criteria for Placement and Replacement. Chicago, Quintessence Publ Co, 1989, pp. 15-59.

Anusavice KJ. Material of the future: preservative or restorative? Operative Dentistry 1998; 23: 163-167.

Assif D, Oren E, Marshk BL. Photoelastic analysis of stress transfer in endodontically treated teeth to the supporting structure using different restorative tecnique. J Prosthet Dent 1989; 61: 535-543.

Axelsson P, Lindhe J, Nyström M. On the prevention of caries and periodontal disease. Results of a 15-year longitudinal study in adults. J Clin Period 1991; 18: 182-189.

Axelsson P, Lindhe J. Effect of controlled oral hygiene procedures on caries and periodontal disease in adults. J Clin Period 1978; 5: 133-151.

Axelsson P, Lindhe J. Effect of controlled oral hygiene procedures on caries and periodontal disease in adults. Results after 6 years. J Clin Period 1981; 8: 239-248.

Behle CA. Conservative direct and indirect resin posterior restorative alternatives for cracked dentition. Pract Periodontics Aesthet Dent 1997; 9: 405-13.

Benn DK, Clark TD, Dankel DD 2nd, Kostewicz SH. Practical approach to evidence-based management of caries.J Am Coll Dent 1999 Spring; 66 (1): 27-35

Benz C, Gust C, Folwaczny M, Benz B, Hickel R. Clinical evaluation of a compomer material in Class II restorations. (abstract 103) J Dent Res 1998, 77(special issue A).

Berglund A, Molin M. Mercury levels in plasma and urine after removal of all amalgam restorations: the effect of using rubber dams. Dent Mater 1997 Sep; 13(5): 297-304.

Brannstrom M, Isacsson G, Johnson G. The effect of calcium hydroxide and fluorides on human dentine. Acta Odontol Scand 1976; 34 (2): 59-67.

Brannstrom M, Nyborg H . Bacterial growth and pulpal changes under inlays cemented with zinc phosphate cement and Epoxylite CBA 9080. J Prosthet Dent 1974 May; 31 (5): 556-511.

Brannstrom M, Nyborg H J. Pulp reaction to a temporary zinc oxide/eugenol cement. Prosthet Dent 1976 Feb; 35 (2): 185-91.

Brannstrom M, Nyborg H. Cavity treatment with a microbicidal fluoride solution: growth of bacteria and effect on the pulp. J Prosthet Dent 1973 Sep; 30 (3): 303-10.

Brannstrom M, Nyborg H. Pulp reaction to fluoride solution applied to deep cavities: an experimental histological study. J Dent Res 1971 Nov-Dec; 50 (6): 1548-52.

Brannstrom M, Vojinovic O. Response of the dental pulp to invasion of bacteria around three filling materials. J Dent Child 1976 Mar-Apr; 43 (2): 83-9.

Brannstrom M. A new approach to insulation. Dent Pract Dent Rec 1969 Aug; 19 (12): 417-20.

Briand DE. Les composite d'obturation - étude expérimentale de la finition des surfaces par abrasion. Actualités Odonto-Stomatologiques 1990; 172: 619-649.

Burke FJT, Cheung SW, Mjör IA, Wilson NHF. Restoration longevity and analysis of reasons for the placement and replacement of restorations provided by vocational dental practitioners and their trainers in United Kingdom. Quintessence Int 1999, 30: 234-242.

Caufield PW. Dental caries - a transmissible and infectious disease revisited: a position paper. Pediatric dent 1997; 19: 491-498.

Chalifoux PR Treatment considerations for posterior laboratory-fabricated composite resin restorations. Pract Periodontics Aesthet Dent 1998; 10: 969-78.

Charlton DG. Dentine bonding: past and present. Gen Dent 1996; 44: 498-507.

Christensen GJ. The coming demise of the cast gold restoration? J Am Dent Assoc 1996; 127: 1233-1236.

Christensen GJ. Cavity preparation: cutting or abrasion? JADA 1996; 127: 1651-1654.

Christensen GJ. Current use of tooth-colored inlays, onlays, and direct-placement resins. J Esthet Dent 1998; 10: 290-5.

Christensen GJ. Using rubber dams to boost quality, quantity of restorative services. J Am Dent Assoc 1994 Jan; 125(1): 81-2.

Ciancio SG. Medications as a risk factor for caries and periodontal disease. NYS Dent J 1997; 59: 962-971.

Collins CJ, Bryant RW, Hodge KL. A clinical evaluation of posterior composite resin restorations: 8-year findings. J Dent 1998; 26: 311-317.

Curilovic Z, Saxer UP; Marthaler TM: Radiologische Kariesläsion im Schmelz - füllen oder abwarten? Schweiz Monatsschr Zahnmed 1983;93:930-934.

Davis SH. Excellence in dentistry: posterior rehabilitation using cast gold onlays. Dent Manage 1988; 28: 38- 43.

De Araujo FB, Rosito DB, Toigo E, dos Santos CK: Diagnosis of approximal caries: radiographic versus clinical examination using tooth separation. Am J Dent 1992 Oct;5(5):245-8.

de Vries HC, Ruiken HM, Konig KG, van 't Hof MA: Radiographic versus clinical diagnosis of approximal carious lesions. Caries Res 1990;24(5):364-70.3

Degrange M. Coronal filling biomaterials. Criteria for selection. Real Clin 1990; 1: 9-26.

Dietschi D, De Siebenthal G, Neveu-Rosenstand L, Holz J. Influence of the restorative technique and new adhesives on the dentine marginal seal and adaptation of resin composite Class II restorations: an in vitro evaluation. Quintessence Int 1995; 26: 717-727.

Donovan TE, Cho GC. Materials for conservative posterior restorations. J Calif Dent Assoc 1996 Sep; 24 (9): 32-38.

Dorfer CE, Schriever A, Heidemann D, Staehle HJ, Pioch T. Influence of rubber-dam on the reconstruction of proximal contacts with adhesive tooth-colored restorations. J Adhes Dent. 2001 Summer; 3(2): 169-75.

Downer MC, Worthington HV: The status of bite-wing radiographs in enhancing discriminatory ability in caries prophylactic clinical trials. Caries Res 1992;26(3):195-200.

Edgar WM, Higham SM. Role of saliva in caries models. Adv in Dent Res 1995; 9: 235-245.

Edward S. Changes in caries diagnostic criteria over time related to the insertion of fillings. A comparative study. Acta Odontol Scand 1997 Jan; 55(1): 23-6.

Eick JD, Gwinnett AJ, Pashley DH, Robinson SJ. Current concepts on adhesion to dentine. Crit Rev Oral Biol Med 1997; 8: 306-335.

Elderton RJ, Mjör IA. Changing scene in cariology and operative dentistry. Int Dent J 1992; 42: 165-169.

Elderton RJ. Assessment and clinical management of early caries in young adults: invasive versus non- invasive methods. Br Dent J 1985; 158: 440-444.

Elderton RJ. Assessment and clinical management of early caries in young adults: invasive versus non- invasive methods. Br Dent J 1985; 158: 440-444.

Fejerskov O. Strategies in the design of preventive programs. Adv in Dent Res 1995; 9: 82-88.

Ferrari M, Kugel G. Handling characteristics of resin composites in posterior teeth. Compend Contin Educ Dent 1998 Sep; 19 (9): 879-82.

Forgie AH, Pine CM, Pitts NB. The use of magnification in a preventive approach to caries detection. Quintessence Int. 2002 Jan;33(1):13-6.

Frankenberger R, Sindel J, Kramer N, Petschelt A. Dentine bond strength and marginal adaptation: direct composite resins vs ceramic inlays. Oper Dent 1999; 24: 147-55.

Freedman G, Goldstep F, Seif T, Pakroo J. Ultraconservative resin restorations. J Can Dent Assoc 1999 Nov; 65(10): 579-81.

Freedman G, Goldstep F. Fifth generation bonding systems: state of the art in adhesive dentistry. J Can Dent Assoc 1997 Jun; 63 (6): 439-43.

Frencken Jo E. The ART approach using glass-ionomers in relation to global oral health care. Dental Materials 2010; 26: 1–6.

Garberoglio R. La protezione della polpa. Attual Dent 1985 Dec 1; 1 (31): 28-9.

Haak R, Wicht MJ, Hellmich M, Gossmann A, Noack MJ. The validity of proximal caries detection using magnifying visual aids. Caries Res. 2002 Jul-Aug;36 (4):249-55.

Haller B, Klaiber B, Tens KD. Einfluss der Kavitätenfinierung auf das initiale Abdichtungsvermögen von Amalgamfüllungen in vitro. Schweiz Monatsschr Zahnmed 1991; 101: 986-992.

Hansen EK, Asmussen E, Christiansen NC. In vivo fractures of endodontically treated posterior teeth restored with amalgam. Endod Dent Traum 1990; 6: 49-55.

Hasselrot L. Tunnel restorations in permanent teeth. A 7 year follow-up study. Swed Dent J 1998, 22:1-7.1. Hausen H. Caries prediction-state of the art. Comm Dent & Oral Epidem 1997; 25: 87-96.

Hawthorne WS, Smales RJ. Factors influencing long-term restoration survival in three private dental practices in Adelaide. Aust Dent J 1997; 42: 59-63.

Helfer AR, Melnik S, Schilder H. Determination of the moisture content of vital and pulpless teeth. Oral Surg 1972; 34: 661-9.

Herrgott A N, Ziemiecki T L, Dennison J B. An evaluation of different composite resin systems finished with various abrasives. JADA 1989; 119: 729-732.

Hewlett ER, Cox CF. Clinical considerations in adhesive restorative dentistry--influence of adjunctive procedures. J Calif Dent Assoc. 2003 Jun; 31(6): 477-82.

Hickel R, Heidemann D, Staehle H.J, Minnig P, Wilson N.H.F. Direct composite restorations Extended use in anterior and posterior situations. Clin Oral Invest 2004; 8: 43–44.

Hickel R, Dasch W, Janda R, Tyas M, Anusavice K. New direct restorative materials. Int Dent J 1998, 48: 3- 16.

Hickel R, Manhart J, Garcia-Godoy F. Clinical results and new developments of direct posterior restorations. Am J Dent 13 (special issue) 2000 Nov, 41-54.

Hickel R, Manhart J. Longevity of restorations in posterior teeth and reasons for failure. J Adhesive Dent 2001, 3: 45-64.

Hickel R, Petschelt A, Maier J, Voss A, Sauter M. Nachuntersuchung von Fullungen mit Cermet-Zement (Ketac-Siver). Dtsch Zahnarztl Z 1998, 43: 851-853.

Hickel R. Two-year clinical evaluation of direct and indirect composite restorations in posterior teeth. J Prosthet Dent 1999; 82: 391-7.

Hintze H, Wenzel A, Danielsen B: Behaviour of approximal carious lesions assessed by clinical examination after tooth separation and radiography: a 2.5-year longitudinal study in young adults. Caries Res 1999 Nov- Dec;33(6):415-22.

Hintze H, Wenzel A. Clinically undetected dental caries assessed by bitewing screening in children with little caries experience. Dentomaxillofac Radiol 1994 Feb; 23(1): 19-23.

Hintze H: Screening with conventional and digital bite-wing radiography compared to clinical examination alone for caries detection in low-risk children. Caries Res 1993;27(6):499-504.

Hirt T Lutz F. Conservative Amalgam Restoration. Schweiz Monatsschr Zahnmed 1987; 97: 1261-1270.

Hitmi L, Attal JP, Degrange M. Influence of the time-point of salivary contamination on dentine shear bond strength of 3 dentine adhesive systems. J Adhes Dent 1999; 1(3): 219-32.

Hitmi L, Attal JP, Degrange M.. Influence of the time-point of salivary contamination on dentine shear bond strength of 3 dentine adhesive systems. J Adhes Dent 1999; 1(3): 219-32.

Hondrum SO, Fernandèz R. Contouring, finishing and polishing class 5 restorative materials. Oper Dent 1997; 22: 30-36.

Huth K, Selbertinger S, Kunzelmann KH, Hickel R.. Compomers for class I/II restorations – Results after 6 months (abstract 1439) J Dent Res 1999, 78 (special issue).

Huysmans MC, Longbottom C, Pitts N. Electrical methods in occlusal caries diagnosis: An in vitro comparison with visual inspection and bite-wing radiography. Caries Res 1998; 32(5): 324-9.

Ie YL, Verdonschot EH, Schaeken MJM, van't Hof MA. Electrical conductance of fissure enamel in recently erupted molar teeth as related to caries status. Caries Res 1995; 29: 94-99.

Jokstad A, Mjor IA, Nilner K, Kaping S. Clinical performance of three anterior restorative materials over 10 years. Quintessence Int 1994; 25: 101-108.

Kanca J . One step bond strength to enamel and dentine. Am J Dent 1997; 10: 5-8. Kidd E A M, Toffenetti F, Mjör I A. Secondary caries. Int Dent J 1992; 42: 127-138.

Kidd EAM, Ricketts DNJ, Beighton D. Criteria for caries removal at the enamel-dentine junction: a clinical and microbiological study. Br Dent J 1996; 180: 287-291.

Kielbassa AM, Paris S, Lussi A, Meyer-Lueckel H. Evaluation of cavitations in proximal caries lesions at various magnification levels in vitro. J Dent. 2006 Nov;34(10):817-22. Epub 2006 May 26.

Kildal KK, Ruyter IE. How different curing methods affect mechanical properties of composites for inlays when tested in dry and wet conditions. Eur J Oral Sci 1997 Aug; 105 (4): 353-61.

Koczarski MJ. Utilization of ceromer inlays/onlays for replacement of amalgam restorations. Pract Periodontics Aesthet Dent 1998; 10: 405-12.

König KJ. Remineralization. Firmenpublikation Elida Cosmetic Ag 1984, ISBN Schweiz 3 9055 2901.

Kramer N, Kunzelmann KH, Mumesohn M, Pelka M, Petschelt A. Langzeit Erfahrungen mit Cermet Zementfullungen in Klasse I/II-Kavitaten. Dtsch Zahnarztl Z 1994, 49: 905-909.

Krejci I, Lutz F. .Kompositfüllungen - das 1X1 des Ausarbeiten. Schweiz Monatsschr Zahnmed 1984; 94: 1015-1028.

Krejci I. Standortbestimmung in der Konservierenden Zahnmedizin. Schweiz Monatsschr Zahnmed 1993; 103: 614-619.

Krejci I. Standortbestimmung in der Konservierenden Zahnmedizin. Schweiz Monatsschr Zahnmed 1993; 103: 614-619.

Kremers L, Halbach S, Willruth H, Mehl A, Welzl G, Wack FX, Hickel R, Greim H. Effect of rubber dam on mercury exposure during amalgam removal. Eur J Oral Sci 1999 Jun; 107(3): 202-7.

Kreulen CM, Creugers NH, Meijering AC. Meta-analysis of anterior veneer restorations in clinical studies. J Dent 1998; 26: 345-53.

Kutsch VK. Microdentistry: a new standard of care. J Mass Dent Soc. 1999 Winter;47(4):35-9.

L.G. Do A.J. Spencer D.H. Association between Dental Caries and Fluorosis among South Australian Children. Caries Res 2009; 43: 366–373 I.

Lacy AM. Application of composite resin for single-appointment anterior and posterior diastema closure. Pract Periodontics Aesthet Dent 1998; 10: 279-286.

Laswell HR, Welk DA. Rationale for designing cavity preparations. Dent Clin North Am 1985; 2: 241-249.

Leinfelder KF. A conservative approach to placing posterior composite resin restorations. JADA 1996; 6: 743-748.

Leinfelder KF. An alternative approach to bonding and pulpal protection. Dent Today 1997 Apr; 16 (4): 88-9. I.

Leinfelder KF. Changing restorative traditions: the use of bases and liners. J Am Dent Assoc 1994; 125: 65- 67.

Leinfelder KF. Current status of dentine adhesive systems. Alpha Omega 1998; 9: 17-22.

Liberman R, Ben-Amar A, Herteanu L, Judes H. Marginal seal of composite inlays using different polymerization techniques. J Oral Rehabil 1997; 24: 26-9.

Liberman R, Judes H, Cohen E, Eli I. Restoration of posterior pulpless teeth: amalgam overlay versus cast gold onlay restoration. J Prosthet Dent 1987; 57: 540-543.

Liebenberg WH. Direct-indirect resin restoration: a case report of acceptable compromise. J Can Dent Assoc 1997; 63: 265-72.

Loe H. Changing paradigms in restorative dentistry. J Am Coll Dent 1995; 3: 31-36.

Lussi A, Gygax M. Iatrogenic damage to adjacent teeth during classical approximal box preparation. J Dent 1998 Jul-Aug; 26 (5-6): 435-41.

Lussi A. Methoden zur Diagnose und Verlaufsdisgnose der Karies. Schweiz Monatsschr Zahnmed 1998;108:357-363.

Lutz F, Setcos JC, Phillips RW. New finishing instruments for composite resins. JADA 1983; 107: 575-580.

Lygidakis NA, Oulis KI, Christodoulidis A. Evaluation of fissure sealants retention following four different isolation and surface preparation techniques: four years clinical trial. J Clin Pediatr Dent 1994 Fall; 19(1): 23-5.

Lygidakis NA, Oulis KI, Christodoulidis A. Evaluation of fissure sealants retention following four different isolation and surface preparation techniques: four years clinical trial. J Clin Pediatr Dent 1994 Fall; 19 (1): 23-5.

Machiulskiene V, Nyvad B, Baelum V. A comparison of clinical and radiographic caries diagnoses in posterior teeth of 12-year-old Lithuanian children. Caries Res 1999 Sep-Oct; 33(5): 340-8.

Mair LH. Ten-year clinical assessment of three posterior resin composites and two amalgams. Quintessence Int 1998; 29: 483-490.

Mala S, Lynch CD, Burke FM, Dummer PM.. Attitudes of final year dental students to the use of rubber dam. Int Endod J. 2009 Jul; 42(7): 632-8. Epub 2009 May 8.

Mandel ID. Caries prevention: current strategies, new directions. JADA 1996; 127: 1477-1488.

Manhart J, Hickel R. Klinische Studie zum einsatz eines All-in-one-Adhasivs. Erste Ergebnisse nach 6 Monaten. Quintessenz 1999, 50: 1277-1288.

Manhart J, Hickel R. Longevity of restorations – Chapter 16 pag.258 in: Advances in Dentistry Volume 2: Challenges of the future. Quintessence Publishing; 2001.

Marshall K. Rubber dam. Br Dent J 1998 Mar 14; 184(5): 218-9.

Marthaler T M. Zahnkaries und Zahnverlust bis zum Jahre 2008: Prognosen für die 25- bis 65jährigen Erwachsenen. Schweiz Monatsschr Zahnmed 1993; 103: 1476-1477.

Martin JA, Bader JD. Five-year treatment outcomes for teeth with large amalgams and crowns. Oper Dent 1997; 22: 72-8.

McKinlay Daniel, Annie Zhang, Mary A. Tavares and Sonja David C. Bellinger, Felicia Trachtenberg, David. Amalgam Trial Function: The New England Children's to Dental Amalgam and Neuropsychological A Dose- Effect Analysis of Children's Exposure. J Am Dent Assoc 2007;138;1210-1216.

McLaren EA, Rifkin R, Devaud V. Considerations in the use of polymer and fiber-based indirect restorative materials. Pract Periodontics Aesthet Dent 1999; 11: 423-32.

Medeiros VA, Seddon RP. Iatrogenic damage to approximal surfaces in contact with Class II restorations. J Dent 2000 Feb; 28(2): 103-105.

Mejare I, Kallestal C, Stenlund H, Johansson H: Caries development from 11 to 22 years of age: a prospective radiographic study. Prevalence and distribution. Caries Res 1998;32(1):10-6.

Mentink AGB, Creugers N. Five year report of a clinical trial on post and core restorations. JADR 1995; 74: 187-92.

Miller MB. Rest in peace G.V. Black: part I. Pract Periodont Aesthet Dent 1997; 7: 757-758.

Mjör I A. Direct posterior filling materials. In Vanherle G, Degrange M, Willems G: State of the art on direct posterior filling materials and dentine bonding. Leuven, Van der Poorten, 1993, pp. 15-28.

Mjör IA, Jokstad A, Quist V. Longevity of posterior restorations. Int Dent J 1990, 40: 11-17.

Mjör IA, Jokstad, A. Five-year study of Class II restorations in permanent teeth using amalgam, glass polyalkenoate (ionomer) cement and resin-based composite materials. J Dent 1993, 21: 338-343.

Mjör IA. Problems and benefits associated with restorative materials: side effect and long-term cost. Adv Dent Res 1992, 6: 7-16.

Moopnar M, Faulkner KDB. Accidental damage to teeth adjacent to crown-prepared abutment teeth. Austral Dent J 1991; 36: 136-140.

Newman SM. Amalgam alternatives: what can compete? J Am Dent Assoc 1991; 122: 67-71.

Nicolaisen S, von der Fehr FR, Lunder N, Thomsen I. Performance of tunnel restoration at 3-6 years. J Dent 2000, 28: 383-387.

Nordbo H, Leirskar J, von der Fehr FR. Saucer-shaped cavity preparations for posterior approximal resin composite restorations: observations up to 10 years. Quintessence Int 1998 Jan; 29 (1): 5-11.

Nordbo H, Lyngstadaas SP. The clinical performance of two groups of functioning class-II cast gold inlays. Acta Odontol Scand 1992; 50: 189-192.

Nyvad B, Machiulskiene V, Baelum V: Reliability of a new caries diagnostic system differentiating between active and inactive caries lesions. Caries Res 1999 Jul-Aug;33(4):252-60.

O'Brien W J, Johnston W M, Fanian F, Lambert S. The surface roughness and gloss of composites. J Dent Res 1984; 63: 685-688.

Osborne JW, Summitt JB. Extension for prevention: is it relevant today? Am J Dent 1998 Aug; 11(4): 189-96. Pashley DH, Carvalho RM. Dentine permeability and dentine adhesion. J Dent 1997; 25: 355-372.

Peumans M, Van Meerbeek B, Lambrechts P, Vanherle G. The 5-year clinical performance of direct composite additions to correct tooth form and position. II. Marginal qualities. Clin Oral Investig 1997; 1: 19- 26.

Pitts N: Monitoring of caries progression in permanent posterior approximal enamel by bitewing radiography: a review. Community Dent Oral Epidemiol 1983;11:228-235.

Pitts NB, Kidd EAM: The prescription and timing of bitewing radiography in the diagnosis and management of dental caries: contemporary recommandations. British Dental Journal 1992;21:225-227.

Pitts NB. Risk assessement and caries prediction. J Dent Educ 1998; 62: 762-770.

Plasmans PJ, Creugers NH, Hermsen RJ, Vrijhoef MM. Intraoral humidity during operative procedures. J Dent 1994 Apr; 22(2): 89-91.

Plasmans PJ, Creugers NH, Mulder J. Long-term survival of extensive amalgam restorations. J Dent Res 1998; 77: 453-60.

Portalier L. Composite smile designs: the key to dental artistry. Curr Opin Cosmet Dent 1997; 4: 81-85.

Porte A, Lutz F, Lund MR, Swartz ML & Cochran MA. Cavity designs for composite resins. Oper Dent 1984; 9: 50-56.

Powell LV. Caries risk assessment: relevance to the practitioner. JADA 1998; 129 (3): 349-353. Powers JM, Farah JW. Compomers. The Dental Advisor 15: 1-5, 1998.

Prati C. In vitro and in vivo adhesion in operative dentistry: a review and evaluation. Pract Periodontics Aesthet Dent 1998; 10: 319-327.

Qvist V, Laurberg L, Poulsen A, Teglers PT. Longevity and cariostatic effects of everyday conventional glass- ionomer and amalgam restorations in primary teeth: three-year results. J Dent Res 1997; 76: 1387-96.

Qvist V. & Strom C. 11-Year assessment of class-III resin restorations completed with two restorative procedures. Acta Odontologica Scandinavica 1993; 51: 253-262.

Radnai M, Fazekas A. Caries prevalence in adults seven years after previous exposure to fluoride in domestic salt. Acta Med dent Helv 1999; 4:163-166.

Randow K, Glantz PO. On cantilever loading of vital and non vital teeth. An experimental clinical study. Acta Odontol Scand 1986; 44: 271.

Raskin A, Michotte-Theall B, Vreven J, Wilson NH. Clinical evaluation of a posterior composite 10-year report. J Dent 1999; 27: 13-9.

Rau PJ, Pioch T, Staehle HJ, D√∂rfer CE. Influence of the rubber dam on proximal contact strengths. Oper Dent. 2006 Mar-Apr; 31(2): 171-5.

Rees JS, Jacobsen PH. The restoration of posterior teeth with composite resin. 2: Indirect-placement composite. Dent Update 1997; 24: 25-30.

Reid JS, Callis PD, Patterson CJW. Rubber Dam in Clinical Practice. Chicago, Quintessence Publ Co, 1990, pp. 5-20.

Reller U, Geiger F, Lutz F. Quantitative investigation of different finishing methods in conventional cavity preparations. Quintessence Int 1989; 20: 453-459.

Ricketts D, Kidd E, Wilson R. The electronical diagnosis of caries in pits and fissures: site-specific stable conductance readings or cumulative resistance readings? Caries Res 1997; 31: 119-124.

Ricketts DN, Kidd EA, Smith BG, Wilson RF. Clinical and radiographic diagnosis of occlusal caries: a study in vitro. J Oral Rehabil 1995 Jan; 22(1): 15-20.

Roulet JF. Longevity of glass ceramic inlays and amalgam-results up to 6 years. Clin Oral Investig 1997; 8: 40-46.

S. Gowda a W.M. Thomson b L.A. Foster Page c N.A. Croucher a What Difference Does Using Bitewing Radiographs to Epidemiological Estimates of Dental Caries Prevalence and Severity in a Young Adolescent Population with High Caries Experience? Caries Res 2009;43:436–44.

Scheibenbogen-Fuchsbrunner A, Manhart J, Kremers L, Kunzelmann KH. Langzeit Erfahrungle mit Cermet-Zementfullungen in KlasseI/II Kavitaten. Dtsch Zahnarztl Z49:905-909; 1994.

Schmid O, Krejci I, Lutz F. Ausarbeitung von adhäsiven zahnfarbenen Inlays aus Komposit und Keramik. Schweiz Monatsschr Zahnmed 1991; 101: 177-184.

Shannon A. Indirect posterior restorations: steps to clinical success. Curr Opin Cosmet Dent 1997; 4: 40-4. Shannon AJ. Clinical guidelines for indirect resin restorations. Can Dent Assoc 1997; 63 (6): 432-7.

Silverstone LM, Hicks MJ, Featherstone MJ. Dynamic factors affecting lesion initiation and progression in human dental enamel. Part I. The dynamic nature of enamel caries. Quintessence International 1988; 10: 683-711.

Simonsen RJ. Conservation of tooth structure in restorative dentistry. Quintessence Int 1985; 16: 15-24.

Smales RJ, Fang DT: In vitro effectiveness of hand excavation of caries with the ART technique. Atraumatic restorative treatment. Caries Res 1999 Nov-Dec;33(6):437-40.

Smales RJ, Hawthorne WS. Long-term survival and cost-effectiveness of five dental restorative materials used in various classes of cavity preparations. Int Dent J 1996; 46: 126-30.

Smales RJ, Webster DA. Restoration deterioration related to later failure. Operative Dentistry 1993; 18: 130- 137.

Smales RJ. Effect of rubber dam isolation on restoration deterioration. Am J Dent 1992; 5: 277-279.

Small BW. Seating, finishing, and polishing of ceramic restorations. Gen Dent 1999 Nov-Dec; 47(6): 560-2.1.

Small BW.Rubber dam-the easy way. Gen Dent 1999 Jan-Feb; 47(1): 30-3.

Sorensen JA, Engelman MJ. Ferrule design and fracture resistance of endodontically treated teeth. J Prosthet Dent 1990; 63: 529-536.

Sornkul E. Strength of root before and after endodontic treatement and restoration. J Endod 1992; 18 (9): 440-44.

Stecksen-Blicks C, Wahlin YB. Diagnosis of approximal caries in pre-school children. Swed Dent J 1983; 7(5): 179-84.

Steiner M, Menghini G, Curilovic Z, Marthaler TM. Kariesprävalenz bei Zürcher Schulkindern 1970, 1983 and 1988. Schweiz Monatsschr Zahnmed 1990; 100: 38-4.

Strassler HE. New concepts with bases and liners. J Esthet Dent 1992 Jul-Aug; 4 (4): 140-1. II.

Strassler HE. Isolation of the field more important than ever. MSDA J 1996 Fall; 39(3): 119-21.

Strassler HE. Isolation of the field more important than ever. MSDA J 1996 Fall; 39 (3): 119-21.

Stratis S, Bryant RW. The influence of modified cavity design and finishing techniques on the clinical performance of amalgam restorations: a 2-year clinical study. J Oral Rehabil 1998 Apr; 25(4): 269-78.

Stratis S, Bryant RW. The influence of modified cavity design and finishing techniques on the clinical performance of amalgam restorations: a 2-year clinical study. J Oral Rehabil 1998 Apr; 25: 269-278.

Surmont P, Martens L, D'Hauwers R. A decision tree for the treatment of caries in posterior teeth. Quintessence Int 1990; 21: 239-246.

Swift EJ Jr. Bonding systems for restorative materials-a comprehensive review. Pediatr Dent 1998; 20: 80- 84.

Swift EJ, Perdigao J, Heymann HO. Bonding to enamel and dentine: a brief history and state of the art, 1995 Quintessence Int 1995; 26: 95-110.

Terry DA.. An essential component to adhesive dentistry: the rubber dam. Pract Proced Aesthet Dent. 2005 Mar; 17(2): 106-108.

Timothy A. DeRouen; Michael D. Martin; Brian G. Leroux; et al.. A Randomized Clinical Trial Neurobehavioral Effects of Dental Amalgam in Children JAMA. 2006; 295(15):1784-1792.

Tobi H, Kreulen CM, Gruythuysen RJ, van Amerongen WE. The analysis of restoration survival data in split- mouth designs. J Dent 1998; 26: 293-298.

Triller M. Fluoride, a preventive agent of caries: mechanisms, sources, risks. Archive de Pediatrie 1998; 5: 1149-1152.

Tucker RV. Gold restorations of the distal aspect of cuspid teeth. Signature 1996; Winter: 4-9. Tveit AB, Espelid I, Fjelltveit A. Clinical diagnosis of occlusal dentine caries. Caries Res 1994; 28: 368-372.

Ulla Pallesen, Vibeke Qvist. Composite resin fillings and inlays. An 11-year evaluation. Clin Oral Invest 2003; 7: 71–79.

Unterbrink GL, Muessner R. Influence of light intensity on two restorative systems. Journal of Dentistry 1995; 23: 183-189.

Van der Merwe WJ. Clinical evaluation of four dental amalgams over a three year period. J Dent Assoc S Afr 1993; 48: 329-332.

Van Meerbeek B, Vanherle G, Lambrechts P, Braem M. Dentine- and enamelbonding agents. Curr Opin Dent 1992; 2: 117-127.

Van Palenstein Helderman WH, Matee MI, van der Hoeven JS, Mikx FH. Cariogenicity depends more on diet than the prevailing mutans streptococcal species. J Dent Res 1996; 75: 535-545.

Verdonschot EH, Kuijpers JMC, Polder BJ, DE Leng-Worm MH, BronkhorstEM. Effects of digital grey - scale modification on the diagnosis of small approximal carious lesion. J Dent 1992;20:44-49.

Verdonschot EH, van de Rijke JW, Brouwer W, ten Bosch JJ, Truin GJ: Optical quantitation and radiographic diagnosis of incipient approximal caries lesions. Caries Res 1991;25(5):359-64.

Wassell RW, Walls AW, McCabe JF. Direct composite inlays versus conventional composite restorations: three-year clinical results. Br Dent J 1995; 179: 343-349.

Watts C. Kinetic mechanisms of visible-light-cured resins and resin-composites. Setting mechanisms of dental materials, pp. 80-112. Transactions of the Academy of Dental Materials, 1992.

Weerheijm KL, Groen HJ, Bast AJ, Kieft JA, Eijkman MA, van Amerongen WE. Clinically undetected occlusal dentine caries: a radiographic comparison. Caries Res 1992; 26(4): 305-9.

Weerheijm KL, Groen HJ. The residual caries dilemma. Community Dent Oral Epidemiol 1999 Dec; 27 (6): 436-41.

Weiss EI, Tzoar A, Kaffe I. Interpretation of bitewing radiographs. Part 2. Evaluation of the size of approximal lesions and need for treatment. J Dent 1996; 24: 385-388.

Wendt SL Jr, Ziemiecki TL, Leinfelder KF. Proximal wear rates by tooth position of resin composite restorations. J Dent 1996; 24: 33-9.

Yip HK, Samaranayake LP. Caries removal techniques and instrumentation: a review. Clin Oral Investig 1998 Dec; 2 (4): 148-54.

Zacharia MA, Munshi AK: Microbiological assessment of dentine stained with a caries detector dye. J Clin Pediatr Dent 1995;19:111-115.

Zambon JJ, Kasprzak SA. The microbiology and histopathology of human root caries. Am J of Dent 1995; 8: 323-328.

Zitzmann NU, Elsasser S, Fried R, Marinello CP. Foreign body ingestion and aspiration. Oral Surg Oral Med Oral Pathol Oral Radiol Endod 1999 Dec; 88(6): 657-60.

ENDODONTICS

Endodontology or Endodontics should be considered in Dentistry the area related to morphology, physiology and pathology of the dental pulp and of the periradicular periodontal tissues, such as cementum, periodontal ligament and surrounding bone.

Endodontology is dealing with:

- diagnostic procedures to identify orofacial pain of dental origin, both depending on pulp pathologies or periapical-periodontal diseases
- vital pulp therapies
- complete root canal treatment, pulpectomy, root canal obturation and post-endodontic reconstruction
- selective pulpal amputation, pulpotomy and linked procedures to preserve pulp vitality in teeth with immature apical formation
- tooth replantation
- surgical procedures to eradicate periapical chronic inflammation of endodontic origin by apicoectomy and retrograde sealing of the root canal system
- post-endodontic reconstruction by intracanal accessory retentions, such as root canal posts, and suitable partial or complete crown coverage
- root canal retreatment in teeth showing post- treatment disease

Diagnosis

The intraoral examination to discover pulpal and periapical pathologies of endodontic origin is quite similar to a routine medical visit.

Medical history focused on sign and symptoms reported by the patient are fundamental to figure out the patient's main concern on pain linked to endodontic pathologies.

Intraoral examination should be accomplished by the classical medical procedure: observation, examination, palpation and percussion.

Observation may disclose swelling, fistulas and other soft tissues manifestation surrounding one or more teeth, all of them frequently reported in teeth with endodontic problems.

Teeth count and dental health conditions may also be some major factors to be examined to disclose pulpal or periapical pathologies.

Diagnostic procedures should be carried on by: periodontal probing, mobility test, percussion test, thermal tests, electrical tests. (Badino M, Taschieri S et al. 2009) (Jafarzadeh H, Udoye CI et al. 2008) (Lin J & Chandler NP 2008)

Trans-illumination test may reveal microfractures.
Radiographic examination – using centering devices and parallel rays technique – is mandatory to point out periapical status in teeth suspected to have a pulpal or periapical involvement of endodontic origin.
In particular teeth it should be followed by further X-Ray examination with different angulation to disclose peculiar anatomical features of the teeth (Cardinali F 2013).
In some case a radiographical monitoring could be necessary to follow-up the evolution of the pathology suspected or diagnosed.
In some complicate cases it should be recommended to add further and more sophisticated X-Ray analysis such as Cone Beam CT to evaluate more precisely the periapical involvement, root canal morphology and anatomical features of the surrounding tissues (inferior alveolar nerve and maxillary sinus).(Kruse C, Spin- Neto R et al. 2016)(Mota de Almeida FJ, Knutsson K et al. 2015) (Patel S, Durack C et al. 2015)
Microbiological test might be suggested in teeth with refractory healing process.
Extraoral examination should also be carried on to evaluate swelling in the upper and lower face aspect, particularly in the lower jaw area.
Palpation of these areas might signal lymph nodes enlargements or temporomandibular joint disfunctions.

Endodontic treatment should be accomplished in:
permanent teeth functionally and esthetically important with a reasonable outcome (Ng YL, Mann V et al. 2007) (Ng YL, Mann V et al. 2008) (Ng YL, Mann V et al. 2010)
Diagnostic procedures should be carried on by an accurate anamnesis, specific intra and extra oral examination and specific diagnostic instrumental examination
Pulp vitality and X-Ray examination are crucial to determine a proper diagnosis

Endodontic treatment indications

1. Permanent teeth with an irreversible pulpitis (Sim IG, Lim TS et al. 2016, Brennan DS, Balasubramanian M et al. 2016);

2. Permanent teeth with necrotic pulp tissue, associated or not to radiographic evidence of periapical radiolucencies (Torabinejad M, Corr R et al, 2009);

3. Permanent teeth that should be utilized for prosthetic purposes whether in not favorable position;

4. Permanent teeth that should be utilized for other purposes that might lead to pulpal damage (Schmidt JC, Walter C et al, 2014);

5. Traumatized teeth(Chala S, Abouqal R, Rida S et al. 2011);

6. Permanent teeth with internal or external resorbtions (Diouf JS, Benoist FL, Benoist HM, 2015) (Patel S, Kanagasingam S et al. 2009) (Patel S, Ricucci D et al. 2010);

7. Permanent teeth showing cracks or fissures that might compromise tooth future integrity (Heling I, Gorfil C et al. 2002);

8. Permanent teeth with refractory to desensitizing procedures

Endodontic treatment contraindications:

1. Permanent teeth not useful for functional or esthetic issues (Iqbal MK & Kim S, 2008) (Torabinejad M, Anderson P, Bader J et al. 2007);

2. Permanent teeth with insufficient periodontal support;

3. Fractured teeth with vertical fractures or horizontal fractures not restorable.

Bibliography

Aguilar P, Linsuwanont P (2011) Vital pulp therapy in vital permanent teeth with cariously exposed pulp: a systematic review. J Endod 37(5), 581-587.

Badino M (2007) "Elementi di diagnostica"; in "Manuale di Endodonzia, Elsevier, 2007", 80-87

Badino M, Taschieri S, Trisciuoglio F, Gagliani M (2009)" Elementi di diagnostica in Endodonzia" Giornale Italiano di Endodonzia; 23(1); 10-32

Brennan DS, Balasubramanian M, Spencer AJ. Treatment of caries in relation to lesion severity: implications for minimum intervention dentistry. Journal of dentistry 2015;43(1):58-65.

Cardinali F (2013) "La valutazione pre-endodontica: diagnosi e preparazione al trattamento" Dentista Moderno, 1; 30-55.

Chala S, Abouqal R, Rida S (2011) Apexification of immature teeth with calcium hydroxide or mineral trioxide aggregate: systematic review and meta-analysis. Oral Surg Oral Med Oral Pathol Oral Radiol Endod 112(4), e36-42.

Diouf JS, Benoist FL, Benoist HM. External inflammatory root resorption associated with a traumatic occlusion. Journal of clinical orthodontics : JCO 2015;49(3):195-200.

Heling I, Gorfil C, Slutzky H, Kopolovic K, Zalkind M, Slutzky-Goldberg I (2002) Endodontic failure caused by inadequate restorative procedures: review and treatment recommendations. J Prosthet Dent 87(6), 674-678.

Iqbal MK, Kim S (2008) A review of factors influencing treatment planning decisions of single-tooth implants versus preserving natural teeth with nonsurgical endodontic therapy. J Endod 34(5), 519-529.

Kruse C, Spin-Neto R, Wenzel A, Kirkevang LL. Cone beam computed tomography and periapical lesions: a systematic review analysing studies on diagnostic efficacy by a hierarchical model. International endodontic journal 2015;48(9):815-828.

Jafarzadeh H, Udoye CI, Kinoshita J (2008) The application of tooth temperature measurement in endodontic diagnosis: a review. J Endod 34(12), 1435-1440.

Lin J, Chandler NP (2008) Electric pulp testing: a review. Int Endod J 41(5), 365-374.

Mota de Almeida FJ, Knutsson K, Flygare L. The impact of cone beam computed tomography on the choice of endodontic diagnosis. International endodontic journal 2015;48(6):564-572.

Ng YL, Mann V, Rahbaran S, Lewsey J, Gulabivala K (2007) Outcome of primary root canal treatment: systematic review of the literature - part 1. Effects of study characteristics on probability of success. Int Endod J 40(12), 921-939.

Ng YL, Mann V, Gulabivala K (2008) Outcome of secondary root canal treatment: a systematic review of the literature. Int Endod J 41(12), 1026-1046.

Ng YL, Mann V, Gulabivala K (2010) Tooth survival following non-surgical root canal treatment: a systematic review of the literature. Int Endod J 43(3), 171-189.

Patel S, Durack C, Abella F, Shemesh H, Roig M, Lemberg K. Cone beam computed tomography in Endodontics - a review. International endodontic journal 2015;48(1):3-15.

Patel S, Kanagasingam S, Pitt Ford T (2009) External cervical resorption: a review. J Endod 35(5), 616-625.

Patel S, Ricucci D, Durak C, Tay F (2010) Internal root resorption: a review. J Endod 36(7), 1107-1121.
Sim IG, Lim TS, Krishnaswamy G, Chen NN. Decision Making for Retention of Endodontically Treated Posterior Cracked Teeth: A 5-year Follow-up Study. Journal of endodontics 2016;42(2):225-229.

Schmidt JC, Walter C, Amato M, Weiger R (2014) Treatment of periodontal-endodontic lesions--a systematic review. J Clin Periodontol 41(8), 779-790.

Torabinejad M, Corr R, Handysides R, Shabahang S (2009) Outcomes of nonsurgical retreatment and endodontic surgery: a systematic review. J Endod 35(7), 930-937.

Torabinejad M, Anderson P, Bader J et al. (2007) Outcomes of root canal treatment and restoration, implant-supported single crowns, fixed partial dentures, and extraction without replacement: a systematic review. J Prosthet Dent 98(4), 285-311.

Orthograde endodontic therapy for permanent teeth

If appropriate diagnostic and prognostic information is available (Lin LM, 2011; Aguilar P, 2011; Schmidt JC, 2014; Setzer FC, 2014), the orthograde endodontic therapy for permanent teeth envisages a sequence of steps from access cavity preparation, to shaping, cleaning and disinfection procedures of the canal system. These steps are then followed by the three-dimensional filling of the resulting endodontic volumes with materials which must be dimensionally stable and biologically compatible over time (Schilder H., 1974; European Society of Endodontology 1994 and 1998).
Although it is identified as an autonomous therapy, the post-endodontic reconstruction of the tooth is the necessary completion of the orthograde endodontic therapy (Moghaddam AS, 2014).

A pre-operative X-ray examination is recommended. For the involved tooth-element a centring device ought to be adopted which allows full view of the root and the periapical region (Stewart T., 2005).
In case of diagnostic uncertainty, Cone Beam CAT can be used as a subsequent instrumental investigation step (Talwar S, 2016; Leonardi Dutra K, 2016).
The anaesthetic treatment is of particular importance for both the patient's and the operator's comfort. It shall, therefore, be assessed based on the patient's local and general clinical condition. Where necessary or appropriate, the usual procedures for analgesia based on plexus or brachial blockage by means of local analgesics (Fowler S., 2016) can be complemented by a pharmacological pre-medication. This is usually administered orally or by inhalation for conscious sedation.
Before starting the endodontic therapy, any existing carious lesions and infiltrated dental restorations must be removed. A pre-endodontic restoration may have to be performed to ensure both the endodontium isolation from the oral environment and the needed temporary structural resistance to the masticatory loads. The risk of fracture can be reduced by controlling the occlusal loads and by performing the final restoration as soon as possible.
Where necessary or appropriate, treatments with antibiotics and/or anti-inflammatories can be added to control possible infections and pain symptoms (Parirokh M, 2014).

Recommendations

1. Endodontic therapies must be performed by means of sterile endodontic instruments and aseptic techniques. The surgical field must be properly isolated by a rubber dam in order to prevent any saliva and bacterial contamination of the tooth being treated as well as any accidental swallowing or upper airway occlusions (Goldfein J, 2013; Bondarde P., 2015; Kumar J., 2015).
2. Magnifying systems and/or special light sources can make some procedure steps easier to perform (Rampado ME, 2004; Del Fabbro M., 2009, 2015).
3. Access cavity preparation aims at removing the pulp chamber roof. This allows the chamber to be properly cleaned by removing its pulp and any obstacles, thereby offering a good view of the root canal orifices. It also allows the chamber to be functionally shaped to remove any primary interferences and to offer enough retention for the temporary cavity filling (Mannan G, 2001; Ferrari PH, 2005; Ruddle CJ, 2007; De Pablo OV, 2010).
4. After locating the root canal orifices, the canals are usually probed with suitable endodontic instruments, reaching as closely as possible the end of the endodontium in order to determine the working length. To that purpose, such methods can be used which envisage the use of

electronic apex locators and, if necessary or appropriate, of intra-operative X-ray examinations (Martínez-Lozano MA, 2001; Siu C, 2009, Martins JN, 2014; Lucena C, 2014).

5. The root canal pulp shall not be devitalised or removed chemically with materials containing toxic chemicals. A mechanical technique, or one based on manual instruments, shall instead be used to ream the root canal until a suitable shape is obtained. The root canal original anatomic structure shall be preserved to the best possible extent, particularly in its apical region. This shall be obtained by simultaneously removing the pulp tissues as well as the organic and inorganic debris, and by reducing the bacterial load (Berutti E, 2004; Kütarci A, 2008; Bird DC, 2009; Paqu F, 2009; Berutti E, 2009; Vieira EP, 2009; Pasqualini D, 2012; Elnaghy AM, 2014; Vasconcelos BC, 2014; Scattina A, 2015).
6. These results can only be obtained if the instrument-based technique is complemented by continuous and copious root canal irrigations, possibly with different irrigating agents. Such agents must have anti-bacterial and lubricating properties, as well as a specific action on the organic and inorganic residues (Sundvist G, 1994; Camara AC, 2009; Brito PR, 2009; Malkhassian G, 2009; Boutsioukis C, 2013).
7. Irrigating agent implementation systems, such as those based on lasers or ultra-sounds, can complement, but not replace, the classical irrigation techniques (Wang QQ, 2007; Sadık B, 2013; Boutsioukis C, 2016).
8. The endodontic instruments aim at clearing the root canal to allow an adequate flow of irrigating agents in the apical regions, too (Boutsioukis C, 2010), while at the same time preserving a shape which can support the three-dimensional filling of the endodontic volumes (Ng YL, 2011).
9. Interim medications can sometimes be used to prevent or reduce micro-organism growth in the canal system (Sjogren U, 1991; Athanassiadis B, 2007; Kawashima N, 2009). Such medications can be used between two subsequent treatments (Nair PN, 2005; Sathorn C, 2005; Figini L, 2007; Vera J, 2012).
10. Root canal shaping, cleaning and disinfection must be followed by root canal filling. A post-operative X-ray examination of the filling must be performed and must show the root apex. It is preferable that 2 - 3 mm of the periapical region should be clearly visible, too (Lyons WW, 2009; Tzanetakis GN, 2009).
11. If the patient is willing to co-operate, the treatment outcome should be checked regularly, and the assessment results should be included in the clinical documentation (Paredes-Vieyra J, 2012).

Bibliography

Aguilar P, Linsuwanont P. Vital pulp therapy in vital permanent teeth with cariously exposed pulp: a systematic review. J Endod. 2011 May;37(5):581-7.

Athanassiadis B, Abbott PV, Walsh LJ. The use of calcium hydroxide, antibiotics and biocides as antimicrobial medicaments in endodontics. Aust Dent J. 2007 Mar;52(1 Suppl):S64-82.

Berutti E, Negro AR, Lendini M, Pasqualini D. Influence of manual preflaring and torque on the failure rate of ProTaper rotary instruments.J Endod. 2004 Apr;30(4):228-30.

Berutti E, Cantatore G, Castellucci A, Chiandussi G, Pera F, Migliaretti G, Pasqualini D. Use of nickel-titanium rotary PathFile to create the glide path: comparison with manual preflaring in simulated root canals. J Endod. 2009 Mar; 35(3):408-12

Bird DC, Chambers D, Peters OA. Usage parameters of nickel-titanium rotary instruments: a survey of endodontists in the United States. J Endod. 2009 Sep;35(9):1193-7.

Bondarde P, Naik A, Patil S, Shah PH. Accidental Ingestion and Uneventful Retrieval of an Endodontic File in a 4 Year Old Child: A Case Report. J Int Oral Health. 2015;7(Suppl 2):74-6.

Brito PR, Souza LC, Machado de Oliveira JC, Alves FR, De-Deus G, Lopes HP, Siqueira JF Jr. Comparison of the effectiveness of three irrigation techniques in reducing intracanal Enterococcus faecalis populations: an in vitro study. J Endod. 2009 Oct;35(10):1422-7.

Boutsioukis C, Verhaagen B, Versluis M, Kastrinakis E, Wesselink PR, van der Sluis LW. Evaluation of irrigant flow in the root canal using different needle types by an unsteady computational fluid dynamics model.J Endod. 2010 May; 36(5):875-9.

Boutsioukis C, Lambrianidis T, Verhaagen B, Versluis M, Kastrinakis E, Wesselink PR, van der Sluis LW. The effect of needle-insertion depth on the irrigant flow in the root canal: evaluation using an unsteady computational fluid dynamics model.J Endod. 2010 Oct; 36(10):1664-8.

Boutsioukis C, Gogos C, Verhaagen B, Versluis M, Kastrinakis E, Van der Sluis LW. The effect of root canal taper on the irrigant flow: evaluation using an unsteady Computational Fluid Dynamics model. Int Endod J. 2010 Oct; 43(10):909-16.

Boutsioukis C, Psimma Z, van der Sluis LW. Factors affecting irrigant extrusion during root canal irrigation: a systematic review. Int Endod J. 2013 Jul;46(7):599-618.

Boutsioukis C, Tzimpoulas N.Uncontrolled Removal of Dentin during In Vitro Ultrasonic Irrigant Activation.J Endod. 2016 Feb;42(2):289-93.

Camara AC, de Albuquerque MM, Aguiar CM, de Barros Correia AC. In vitro antimicrobial activity of 0.5%, 1%, and 2.5% sodium hypochlorite in root canals instrumented with the ProTaper Universal system. Oral Surg Oral Med Oral Pathol Oral Radiol Endod. 2009 Aug;108(2):e55-61.

Del Fabbro M, Taschieri S, Lodi G, Banfi G, Weinstein RL. Magnification devices for endodontic therapy. Cochrane Database Syst Rev. 2009 Jul 8;(3):CD005969.

Del Fabbro M, Taschieri S, Lodi G, Banfi G, Weinstein RL Magnification devices for endodontic therapy.Cochrane Database Syst Rev. 2015 Dec 9;12

De Pablo OV, Estevez R, Péix Sánchez M, Heilborn C, Cohenca N. Root anatomy and canal configuration of the permanent mandibular first molar: a systematic review. J Endod. 2010 Dec;36(12):1919-31.

Elnaghy AM, Elsaka SE. Evaluation of root canal transportation, centering ratio, and remaining dentin thickness associated with ProTaper Next instruments with and without glide path.J Endod. 2014 Dec;40(12):2053-6

European Society of Endodontology (1994) Consensus report of the European Society of Endodontology on quality guidelines for endodontic treatment. International Endodontic Journal 1994, 27, 115–24.

European Society of Endodontology (1998) Guidelines for specialty training in endodontology. International Endodontic Journal 1998, 31, 67–72.

Ferrari PH, Cai S, Bombana AC. Effect of endodontic procedures on enterococci, enteric bacteria and yeasts in primary endodontic infections. Int Endod J. 2005 Jun;38(6):372-80.

Figini L, Lodi G, Gorni F, Gagliani M.Single versus multiple visits for endodontic treatment of permanent teeth.Cochrane Database Syst Rev. 2007 Oct 17;(4)

Fowler S, Drum M, Reader A, Beck M. Anesthetic Success of an Inferior Alveolar Nerve Block and Supplemental Articaine Buccal Infiltration for Molars and Premolars in Patients with Symptomatic Irreversible Pulpitis.J Endod. 2016 Mar;42(3):390-392

Goldfein J, Speirs C, Finkelman M, Amato R. Rubber dam use during post placement influences the success of root canal-treated teeth. J Endod. 2013 Dec;39(12):1481-4.

Leonardi Dutra K, Haas L, Porporatti AL Flores-Mir C, Nascimento Santos J, Mezzomo LA, Corrêa M, De Luca Canto G. Diagnostic Accuracy of Cone-beam Computed Tomography and Conventional Radiographyon Apical Periodontitis: A Systematic Review and Meta-analysis.J Endod. 2016 Mar;42(3):356-364.

Lin LM, Rosenberg PA. Repair and regeneration in endodontics. Int Endod J. 2011 Oct;44(10):889-906.

Lyons WW, Hartwell GR, Stewart JT, Reavley B, Appelstein C, Lafkowitz S. Comparison of coronal bacterial leakage between immediate versus delayed post-space preparation in root canals filled with Resilon/Epiphany. Int Endod J. 2009 Mar;42(3):203-7.

Lucena C, López JM, Martín JA, Robles V, González-Rodríguez MP. Accuracy of working length measurement: electronic apex locator versus cone-beam computed tomography. Int Endod J. 2014 Mar;47(3):246-56.

Kawashima N, Wadachi R, Suda H, Yeng T, Parashos P. Root canal medicaments. Int Dent J. 2009 Feb;59(1):5-11.

Kumar J, Sharma R, Sharma M, Prabhavathi V, Paul J, Chowdary CD. Presence of Candida albicans in Root Canals of Teeth with Apical Periodontitis and Evaluation of their Possible Role in Failure of Endodontic Treatment. J Int Oral Health. 2015 Feb;7(2):42-5.

Kütarci A, Akpinar KE, Sumer Z, Er K, Bek B. Apical extrusion of intracanal bacteria following use of various instrumentation techniques. Int Endod J. 2008 Dec;41(12):1066-71.

Malkhassian G, Manzur AJ, Legner M, Fillery ED, Manek S, Basrani BR, Friedman S. Antibacterial efficacy of MTAD final rinse and two percent chlorhexidine gel medication in teeth with apical periodontitis: a randomized double-blinded clinical trial. J Endod. 2009 Nov;35(11):1483-90.

Mannan G, Smallwood ER, Gulabivala K. Effect of access cavity location and design on degree and distribution of instrumented root canal surface in maxillary anterior teeth. Int Endod J. 2001 Apr;34(3):176-83.

Martínez-Lozano MA, Forner-Navarro L, Sánchez-Cortés JL, Llena-Puy C. Methodological considerations in the determination of working length. Int Endod J. 2001 Jul;34(5):371-6.

Martins JN, Marques D, Mata A, Caramês J. Clinical efficacy of electronic apex locators: systematic review. J Endod. 2014 Jun;40(6):759-77.

Moghaddam AS, Radafshar G, Taramsari M, Darabi F. Long-term survival rate of teeth receiving multidisciplinary endodontic, periodontal and prosthodontic treatments. J Oral Rehabil. 2014 Mar;41(3):236-42.

Nair PN, Henry S, Cano V, Vera J. Microbial status of apical root canal system of human mandibular first molars with primary apical periodontitis after "one-visit" endodontic treatment.Oral Surg Oral Med Oral Pathol Oral Radiol Endod. 2005 Feb;99(2):231-52

Ng YL, Mann V, Gulabivala K. A prospective study of the factors affecting outcomes of nonsurgical root canal treatment: part 1: periapical health. Int Endod J. 2011 Jul;44(7):583-609.

Ng YL, Mann V, Gulabivala K. A prospective study of the factors affecting outcomes of non-surgical root canal treatment: part 2: tooth survival. Int Endod J. 2011 Jul;44(7):610-25.

Paredes-Vieyra J, Enriquez FJ. Success rate of single- versus two-visit root canal treatment of teeth with apical periodontitis: a randomized controlled trial. J Endod. 2012 Sep;38(9):1164-9

Parirokh M, Sadr S, Nakhaee N, Abbott PV, Manochehrifar H. Comparison between prescription of regular or on-demand ibuprofen on postoperative pain after single-visit root canal treatment of teeth with irreversible pulpitis.J Endod. 2014 Feb;40(2):151-4.

Schmidt JC, Walter C, Amato M, Weiger R. Treatment of periodontal-endodontic lesions--a systematic review. J Clin Periodontol. 2014 Aug;41(8):779-90.

Paqu F, Ganahl D, Peters OA. Effects of root canal preparation on apical geometry assessed by micro-computed tomography. J Endod. 2009 Jul;35(7):1056-9.

Pasqualini D, Mollo L, Scotti N, Cantatore G, Castellucci A, Migliaretti G, Berutti E. Postoperative pain after manual and mechanical glide path: a randomized clinical trial. J Endod. 2012 Jan;38(1):32-6

Rampado ME, Tjäderhane L, Friedman S, Hamstra SJ. The benefit of the operating microscope for access cavity preparation by undergraduate students. J Endod. 2004 Dec;30(12):863-7.

Ruddle CJ. Access preparation endodontic: an opening for success. Dent Today. 2007 Feb;26(2):114, 116-9.

Sadık B, Arıkan S, Beldüz N, Yaşa Y, Karasoy D, Cehreli M. Effects of laser treatment on endodontic pathogen Enterococcus faecalis: a systematic review. Photomed Laser Surg. 2013 May; 31(5):192-200.

Sathorn C, Parashos P, Messer HH. Effectiveness of single- versus multiple-visit endodontic treatment of teeth with apical periodontitis: a systematic review and meta-analysis.Int Endod J. 2005 Jun;38(6):347-55.

Scattina A, Alovisi M, Paolino DS, Pasqualini D, Scotti N, Chiandussi G, Berutti E. Prediction of Cyclic Fatigue Life of Nickel-Titanium Rotary Files by Virtual Modeling and Finite Elements Analysis. J Endod. 2015 Nov;41(11):1867-70.

Schilder H. Cleaning and shaping the root canal. Dent Clin N Am 1974;18:269. (r. I).

Setzer FC, Kim S. Comparison of long-term survival of implants and endodontically treated teeth. J Dent Res. 2014 Jan; 93(1):19-26.

Siu C, Marshall JG, Baumgartner JC. An in vivo comparison of the Root ZX II, the Apex NRG XFR, and Mini Apex Locator by using rotary nickel-titanium files. J Endod. 2009 Jul;35(7):962-5.

Sjogren U, Figdor D, Spangberg L, Sundqvist G. The antimicrobial effect of calcium hydroxide as a short term intracanal dressing. Int Endod J 1991;24:119. (r. I).

Stewart T. Diagnosis and treatment planning are essential prior to commencing endodontic treatment: discuss this statement as it relates to clinical endodontic management. Aust Endod J. 2005 Apr; 31(1):29-34.

Sundvist G. Taxonomy, ecology, and pathogenicity of the root canal flora. Oral Surg Oral Med Oral Pathol 1994;78:522. (r. II)

Talwar S, Utneja S, Nawal RR, Kaushik A, Srivastava D, OberoySS. Role of Cone-beam Computed Tomography in Diagnosis of Vertical Root Fractures: A Systematic Review and Meta-analysis. J Endod. 2016 Jan;42(1):12-24.

Tzanetakis GN, Kakavetsos VD, Kontakiotis EG. Impact of smear layer on sealing property of root canal obturation using 3 different techniques and sealers. Part I. Oral Surg Oral Med Oral Pathol Oral Radiol Endod. 2009 Oct 27.

Vasconcelos BC, Frota LM, Souza Tde A, Bernardes RA, Duarte MA. Evaluation of the maintenance of the apical limit during instrumentation with hybrid equipment in rotary and reciprocating modes. J Endod. 2015 May;41(5):682-5.

Vera J, Siqueira JF Jr, Ricucci D, Loghin S, Fernández N, Flores B, Cruz AG. One-versus two-visit endodontic treatment of teeth with apical periodontitis: a histobacteriologic study. J Endod. 2012 Aug; 38(8):1040-52.

Vieira EP, Nakagawa RK, Buono VT, Bahia MG. Torsional behaviour of rotary NiTi ProTaper Universal instruments after multiple clinical use. Int Endod J. 2009 Oct;42(10):947-53.

Wang QQ, Zhang CF, Yin XZ. Evaluation of the bactericidal effect of Er,Cr:YSGG, and Nd:YAG lasers in experimentally infected root canals. J Endod. 2007 Jul; 33(7):830-2.

Endodontic retreatment

The endodontic non-surgical retreatment is indicated in the following cases:

1. Absence of coronal seal, even when the endodontic treatment was preformed correctly: there must be signs demonstrating exposure to the oral environment that caused endodontic recontamination (Alves et al. 1998, Berutti 1996, Gish et al. 1994, Magura et al. 1991, Swanson & Madison 1987, Torabinejad et al. 1990);

   Presence of signs and/or symptoms of periradicular lesion associated with previous endodontic treatment (Engstrom et al. 1964, Ng et al. 2008, Strindberg 1956, Torabinejad et al. 2009);

2. Prosthetic or restorative procedures that compromise pre-existing root canal filling (Ruddle 2004, JOE Editorial Board 2008a, Sjogren et al. 1990, Swanson & Madison 1987, Torabinejad et al. 1990);

3. Prosthetic or restorative procedures that involve teeth with inadequate endodontic treatment (JOE Editorial Board 2008b, Paik et al. 2004, Ruddle 2004, Sundqvist et al. 1998).

The endodontic retreatment must be done on permanent teeth that must: have a resistant structure, be important for function and have a favorable prognosis (Fristad et al. 2004, Kvist & Reit 1999, Torabinejad & White 2016).

The endodontic non-surgical retreatment represents a procedure aimed to either remove from a tooth root canal system the filling material that was previously inserted or to complete a previous inadequate

canal treatment. Root canal cleaning, shaping and filling must be done with adequate techniques and materials. The removal of pivots or other retention systems, the intervention on canal obstructions or the correction of any iatrogenic mistakes (perforations, stripping), could also be necessary (Bergenholtz at al. 1979, Del Fabbro et al. 2007, Fuss & Trope 1996, JOE Editorial Board 2008a, Main et al. 2004, Pace et al. 2008, Schilder 1974, Trope & Tronstad 1985).

The method's objectives are:

1. Identification of cause of failure (Baumgartner 1991, George 2015);
2. Symptoms control (Sathorn et al 2008; Briggs & Scott 1997, Fristad et al. 2004);
3. Shaping, cleaning and filling each canal system as close to the apex as possible (Briggs & Scott 1997, JOE Editorial Board 2008, Bystrom & Sundqvist 1981, Schilder 1974);
4. Hermetical and lasting sealing of the coronal access (Alves et al. 1998, Gish et al. 1994, Magura et al. 1991);
5. Help healing and repairing of the periradicular tissues (Bystrom & Sundqvist 1981, Ng et al. 2008);
6. Check the therapy outcome over time (Chevigny et al. 2008, Farzaneh et al. 2004, Gorni & Gagliani 2004, Wu et al. 2009).

Bibliography

Alves J, Walton R, Drake D. Coronal leakage: endotoxin penetration from mixed bacterial communities through obturated, post-prepared root canals. J Endod 1998; 24, 587-91.

Baumgartner JC. Microbiologic and pathologic aspects of endodontics. Curr Opin Dent 1991;1:737.

Bergenholtz G, Lekholm U, Milthon R, Heden G, Odesjo B, Engstrom B. Retreatment of endodontic fillings. Scand J Dent Res 1979;87:217.

Berutti E. Microleakage of human saliva through dentinal tubules exposed at the cervical level in teeth treated endodontically. J Endod 1996; 22, 579-82.

Briggs PF, Scott BJ. Evidence-based dentistry: endodontic failure. How should it be managed? Br Dent J. 1997 Sep13;183:159-64.

Bystrom A, Sundqvist G. Bacteriologic evaluation of the efficacy of mechanical root canal instrumentation in endodontic therapy. Scand J Dent Res 1981;89:321.

Chevigny C, Dao TT, Basrani BR, Marquis V, Farzaneh M, Abitbol S, Friedman S. Treatment outcomes in endodontics: the Toronto Study phase III and IV: orthograde retreatment. J Endod 2008;34:131-7.

Del Fabbro M, Taschieri S, Testori T, Francetti L, Weinstein RL. Surgical versus non surgical endodontic retreatment for periradicular lesions. Cochrane Database Syst Rev 2007;18(3).

Engstrom B, Hard AF, Segerstad L, Ramstrom G, Frostell G. Correlation of positive cultures with the prognosis of root canal treatment. Odontol Rev 1964;15, 257-270.

Farzaneh M, Abitbol S, Lawrence HP, Friedman S. Treatment outcomes in endodontics: the Toronto Study phase I and II: orthograde retreatment. J Endod 2004;30:627-33.

Fristad I, Molven O, Halse A. Non surgically retreated teeth: radiographic findings after 20-27 years. Int Endod J 2004;37:8-12.

Fuss Z, Trope M. Root perforations: classification and treatment choices based on prognostic factors. Endod Dent Traumatol 1996;12:255.

George R. Nonsurgical retreatment vs. endodontic microsurgery: assessing success. Evid Based Dent. 2015 Sep;16(3):82-3.

Gish SP, Drake DR, Walton RE, Wilcox L. Coronal leakage: bacterial penetration through obturated canals following post preparation. JADA 1994; 125, 1369-72.

Gorni F, Gagliani M. The outcome of endodontic retreatment: a two years follow up study. J Endod 2004;30:1-4.

JOE Editorial Board. Endodontic retreatment: an online study guide. J Endod. 2008a May;34(5 Suppl):e125-30.

JOE Editorial Board. Success and failure in endodontics: an online study guide. J Endod. 2008b May;34(5 Suppl):e1-6.

Kvist T, Reit C. Results of endodontic retreatment: a randomized clinical study comparing surgical and non surgical procedures. J Endod 1999;25:814-7.

Magura ME, Kafrawy AH, Brown CE Jr, Newton CW (1991) Human saliva coronal microleakage in obturated root canals: an in vitro study. J Endod 1991; 17, 324-31.

Main C, Mirzayan N, Shabahang S, Torabinejad M. Repair of root perforation using mineral trioxide aggregate: a long term study. J Endod 2004;30:80-3.

Ng YL, Mann V, Gulabivala K. Outcome of secondary root canal treatment: a systematic review of the literature. Int Endod J. 2008 Dec;41(12):1026-46.

Pace R, Giuliani V, Pagavino G. Mineral trioxide aggregate as repair for furcal perforation: case series. J Endod 2008;34:1130-3.

Paik S, Sechrist C, Torabinejad M. Levels of evidence for the outcome of endodontic retreatment. J Endod. 2004 Nov;30:745-50.

Ruddle CJ. Non surgical endodontic retreatment. J Endod. 2004 Dec;30:827-45.

Sathorn C, Parashos P, Messer H. The prevalence of postoperative pain and flare up in single and multiple-visit endodontic treatment: a systematic review. Int Endod J. 2008 Feb;41:91-9.

Schilder H. Cleaning and shaping the root canal. Dent Clin N Am 1974;18:269.

Sjogren U, Hagglund B, Sundqvist G, Wing K. Factors affecting the long term results of endodontic treatment. J Endod 1990;16:498-4.

Strindberg Z. The dependence of the result of pulp therapy on certain factors. An analytic study based on radiographic and clinical follow up examination. Acta Odontol Scand 1956;14;suppl.21.

Sundqvist G, Figdor D, Persson S, Sjogren U. Microbiologic analysis of teeth with failed endodontic treatment and the outcome of conservative retreatment. Oral Surg Oral Med Oral Pathol Oral Radiol Endod 1998;85:86.

Swanson K, Madison S. An evaluation of coronal microleakage in endodontically treated teeth. Part I. Time periods. J Endod 1987; 13, 56-9.

Torabinejad M, Ung B, Kettering JD. In vitro bacterial penetration of coronally unsealed endodontically treated teeth. J Endod 1990;16, 566-9.

Torabinejad M, Corr R, Handysides R, Shabahang S. Outcomes of nonsurgical retreatment and endodontic surgery: a systematic review. J Endod. 2009 Jul;35:930-7.

Torabinejad M, White SN. Endodontic treatment options after unsuccessful initial root canal treatment: Alternatives to single-tooth implants. J Am Dent Assoc. 2016 Mar;147(3):214-20.

Trope M, Tronstad L. Long-term calcium hydroxide treatment of a tooth with iatrogenic root perforation and lateral periodontitis. Endod Dent Traumatol 1985;1:35.

Wu MK, Shemesh H, Wesselink PR. Limitations of previously published systematic reviews evaluating the outcome of endodontic treatment. Int Endod J. 2009 Aug;42(8):656-66.

Perforations Repair

The intervention aims to seal an iatrogenic perforation deriving from procedural error (Carr GB 1994), or a pathological one, from external reabsorption in communication with the root canal or internal reabsorption with perforation, with an orthograde and/or surgical approach (Carr GB 1998 , Farzaneh M. et al 2004).

The evaluation elements that should be considered before the therapeutic choice, for prognostic purposes, are:

- the location
- the accessibility
- the size
- the visibility
- the periodontal health status
- the proximity to anatomical structures
- the strategic importance of the part (Carr GB 1998, Regan J, et al 2005).

The location can be defined as: supracrestal, crestal and apical, depending on the involved anatomical part of the dental element (Regan J et al.2005).

The surgical choice is carried out when, apart from the access difficulty or the orthograde failure, the defect is too large and not very contained, or where an intervention in the apical area is already planned or when it presents extruded material (Heiling I et al 2002).

The shape and treatment of the surgical flap will be managed according to the modalities expressed in the chapter dealing with surgical endodontics.

The access, orthograde and/or surgical, is intraoperatively cleaned, the perforation is regularized in the shape -even using ultrasound, disinfected, closed up with biocompatible materials, which give good guarantee of seal and stability over time (Main C et al .2004, Bogen G. et al. 2009, Mente J et al. 2009, Krupp C et al. 2013, Mente J et al. 2014, Gorni F et al. 2015,Parirokh M. et al. 2010, Siew K et al. 2015).

Therefore the prognosis may be more opportune when the perforations are small, of recent production, and are located in apical or supracrestal locations; on the contrary, it is less advantageous when the perforations are dated, large and in crestal location with endoperiodontal communication (Gorni F et al.2016, Siew K et al. 2015, Tsesis I et al. 2010).

Contraindications to treatment are: orthograde and surgical inaccessibility caused by local anatomical factors; tooth with insufficient periodontal support; non-collaborating patient; patient with a medical history compromised by uncompensated systemic diseases; radiation therapy and bisphosphonate therapy.

Bibliography

Bogen G, Kuttler S. Mineral trioxide aggregate obturation: a review and case series. J Endod 2009;35,777–90.

Carr GB. Surgical endodontics, pathways of the pulp, Mosby, st. Louis, Sixth Edition, p.544, 1994

Carr GB, Bentkover SK. Surgical endodontics, pathways of the pulp, Mosby, St. Louis, Seventh Edition, p.636,1998.

Fabio G. Gorni, Anita Andreano, Federico Ambrogi, Eugenio Brambilla, Massimo Gagliani Patient and Clinical Characteristics Associated with Primary Healing of Iatrogenic Perforations after Root Canal Treatment: Results of a Long-term Italian Study. J Endod 2015:42, 211-15

Fabio G. Gorni, Andreano A, Ambrogi F, Brambilla E, Gagliani M. Patient and Clinical Characteristics Associated with Primary Healing of Iatrogenic Perforations after Root Canal Treatment: Results of a Long-term Italian Study. J Endod. 2016 Feb;42(2):211-5.

Farzaneh M, Abitbol S, Friedman S. Treatment outcome in endodontics: the Toronto study. Phases I and II: Orthograde retreatment. J Endod 2004;30:627–33.

Heling I, Gorfil C, Slutzky H, Kopolovic K, Zalkind M, Slutzky-Goldberg I. Endodontic failure caused by inadequate restorative procedures: review and treatment recommendations. J Prosthet Dent 2002;87:674–8.

Christian Krupp, Clemens Bargholz, Martin Brüsehaber, Michael Hülsmann Treatment Outcome after Repair of Root Perforations with Mineral Trioxide Aggregate: A Retrospective Evaluation of 90 Teeth . J Endod 2013:39, 1364-68

Main C, Mirzayan N, Shabahang S, et al. Repair of root perforations using mineral trioxide aggregate: a long-term study. J Endod 2004;30:80–3.

Masoud Parirokh, Mahmoud Torabinejad .Mineral Trioxide Aggregate: A Comprehensive Literature Review—Part III: Clinical Applications, Drawbacks, and Mechanism of Action. J Endod 2010:36, 400-13

Mente J, Hage N, Pfefferle T, Koch MJ, Dreyhaupt J, Staehle HJ, et al. Mineral trioxide aggregate apical plugs in teeth with open apical foramina: a retrospective analysis of treatment outcome. J Endod 2009:35, 1354–8

Johannes Mente, Meltem Leo, Dimos Panagidis, Daniel Saure, Thorsten Pfefferle Treatment Outcome of Mineral Trioxide Aggregate: Repair of Root Perforations—Long-term Results.
J Endod 2014:40, 790-96

Mente J, Leo M, Panagidis D, Saure D, Pfefferle T. Treatment outcome of mineral trioxide aggregate: repair of root perforations-long-term results. J Endod. 2014 Jun;40(6):790-6.

John D.Regan , David E. Whitherspoon e Deborah M.Foyle .Surgical repair of root and tooth perforations.Endodontic Topics 2005,11,152-178

Siew K, Lee AH, Cheung GS. Treatment Outcome of Repaired Root Perforation: A Systematic Review and Meta-analysis. J Endod. 2015 Nov;41(11):1795-804.

Tsesis I, Rosenberg E, Faivishevsky V, Kfir A, Katz M, Rosen E. Prevalence and Associated Periodontal Status of Teeth with Root Perforation: A Retrospective Study of 2,002 Patients' Medical Records. Journal of Endodontics, Volume 36, Issue 5, May 2010, Pages 797-800.

Endodontic treatment of permanent teeth with open apex

Apexification procedure, performed in association with a non-surgical endodontic treatment, is indicated to treat a permanent tooth with an open apex affected by irreversible pulpitis or pulp necrosis following deep caries or traumatic injuries.

There are two categories of permanent teeth with open apexes:

1. True immature teeth (that are present in the dental arches, but have not completed yet their root development)
2. Teeth whose root development has been interrupted due to an irreversible damage to the dental pulp when they were still at an immature stage, but have been diagnosed later in time on an adult patient.

In both situations it is important to do an APEXIFICATION TREATMENT. Apexification is an endodontic treatment performed by the removal of necrotic pulp tissue, the delicate instrumentation of the root canal with K-files and the irrigation of the root canal with 1%-5% sodium hypochlorite, and in which the obturation of the open apex cannot be performed using traditional techniques. The open apex can be sealed using an intermediate bioactive medication (possibly calcium hydroxide) that would ease the closure of the open apex by the formation of a hard tissue barrier in the terminal portion of the incomplete root (normally a cementum repair). When apexification is completed (about 12 months following treatment) the tooth can be obturated using guttapercha and sealer (1-8). As an alternative, apexification can be performed directly by obutrating the open apex with a bioactive endodontic cement (i.e. portland), without waiting the formation of the hard tissue barrier, which will still occur in the following twelve months (8-12)

APEXOGENESIS is indicated in teeth affected by reversible or partly reversible pulpitis (due to caries or trauma) and will enable the physiologic root development in the immature tooth if, following the pulp damage, a pulp capping or a deep/ shallow pulpotomy procedure are performed to maintain pulp vitality . Both treatments should include the removal of carious tissue, if present, the disclosure and possible removal of part of coronal or radicular dental pulp, and the medication of the pulp stump with calcium hydroxide or portland cements, followed by the obturation of the tooth.

Bibliography

Azimi S, Fazlyab M, Sadri D, Saghiri MA, Khosravanifard B, Asgary S.
Comparison of pulp response to mineral trioxide aggregate and a bioceramic paste in partialpulpotomy of sound human premolars: a randomized controlled trial. Int Endod J. 2014; 47:873-81

Bonte E, Beslot A, Boukpessi T, Lasfargues JJ. MTA versus Ca(OH)2 in apexification of non-vital immature permanent teeth: a randomized clinical trial comparison. Clinical Oral Investigations 2015; 19:1381.

Cvek M. A clinical report on partial pulpotomy and capping with calcium hydroxide in permanent incisors with complicated crown fracture. J Endod 1978;4:232.

Damle SG, Bhattal H, Loomba A. Apexification of anterior teeth: a comparative evaluation of mineraltrioxide aggregate and calcium hydroxide paste. J Clin Paediatric Dent 2012;36:263.

Dominguez Reyes A, Muñoz Muñoz L, Aznar Martín T. Study of calcium hydroxide apexification in 26 young permanent incisors. Dent Traumatol 2005; 21:141.

El -Meligy OA, Avery DR. Comparison of apexification with mineral trioxide aggregate and calcium hydroxide. Pediatr Dent 2006;28:248.

England MC, Best E. Non induced apical closure in immature roots of dogs' teeth. J Endod 1977;3:411

European Society of Endodontology. Quality guidelines for endodontic treatment: consensus report of the European Society of Endodontology. Int Endod J 2006;39:921-930.

Mejàre I, Cvek M. Partial pulpotomy in young permanent teeth with deep carious lesions.
Endod Dent Traumatol. 1993;9:238-42

Rafter M. Apexification: a review. Dent Traumatol 2005;21:1-8.

Sheehy EC, Roberts GJ. Use of calcium hydroxide for apical barrier formation and healing in non-vital immature permanent teeth: a review. Br Dent J. 1997;183:241.

Simon S, Rilliard F, Berdal A, Machtou P. The use of mineral trioxide aggregate in one-visit apexification treatment: a prospective study. Int Endod J 2007;40:186-197.

Steiner JC, Van Hassel HJ. Experimental root apexification in primates. Oral Surg Oral Med Oral Pathol 1971;31:409.

Walia T, Chawla HS, Gauba K. Management of wide open apices in non-vital permanent teeth with Ca(OH)2 paste. J Clin Pediatr Dent 2000;25:51.

Witherspoon DE, Small JC, Regan JD, Nunn M. Retrospective analysis of open apex teeth obturated with mineral trioxide aggregate. J Endod 2008;34(10):1171-6.

Dental traumatology

Dental trauma injuries are usually caused by accidental falls, sporting events and accidents (Güngör 2014). They mainly involve the front teeth in children and adolescents, the upper central incisors being the most frequently affected teeth (Güngör 2014). The management of dento-alveolar trauma should refer to specific diagnostic and therapeutic protocols (Table 1).

TABLE 1 - GENERAL RECOMMENDATIONS FOR THE MANAGEMENT OF DENTO-ALVEOLAR TRAUMATIC LESIONS

CLINICAL HISTORY (Day & Duggal 2003)

- Obtain detailed information on the trauma that has just occurred.
- Medical history.
- Dental history with particular reference to previous trauma or pathologies affecting the involved teeth.

CLINICAL EXAMINATION (Diangelis *et al.* 2012)

- Inspection of facial and oral soft tissues.
- Facial skeletal palpation to detect any fractures.
- Inspection of trauma-affected teeth to detect location, displacement, mobility, possible fractures.
- Proceed to a periodontal sounding.
- Perform thermal tests and electrical tests, mobility tests and percussion tests.

RADIOGRAPHIC EXAMINATION (Diangelis *et al.* 2012, Patel *et al.* 2015)

The following projections and routine angles are recommended:

- occlusal projection;
- horizontal 90° projection with bisectric technique, with central beam crossing the tooth object of investigation;
- horizontal lateral projection with mesial or distal angle with respect to the tooth surveyed, with bisector technique.

The CBCT is often indicated with the appropriate FOV in place of the three above-mentioned projections. In case of lips or mucous lacerations additional radiographs should be performed to search for dental fragments or foreign materials penetrated into the soft tissues.

INDICATIONS TO BE PROVIDERD TO THE PATIENT (Diangelis *et al.* 2012)

- Soft diet for at least a week.
- Maintain good oral hygiene.
- Undergo periodic controls over time.

Bibliografy

1. Day PF, Duggal MS.A multicentre investigation into the role of structured histories for patients with tooth avulsion at their initial visit to a dental hospital. Dent Traumatol 2003;19:243-7.
2. Diangelis AJ, Andreasen JO, Ebeleseder KA, Kenny DJ, Trope M, Sigurdsson A, Andersson L, Bourguignon C, Flores MT, Hicks ML, Lenzi AR, Malmgren B, Moule AJ, Pohl Y, Tsukiboshi M. International Association of Dental Traumatology guidelines for the management of traumatic dental injuries: 1. Fractures and luxations of permanent teeth. Dent Traumatol 2012;28: 66-71.
3. Güngör HC. Management of crown-related fractures in children: an update review. Dent Traumatol 2014;30:88-99.
4. Patel S, Durack C, Abella F, Shemesh H, Roig M, Lemberg K. Cone beam computed tomography in Endodontics - a review. Int Endod J 2015;48:3-15.

Post-traumatic dento-alveolar fractures

Post-traumatic dento-alveolar fractures (Table 2) may affect both the coronal-radicular portion of the tooth as well as the bone support and may be associated with dental displacement.

TABLE 2 - POST-TRAUMATIC DENTO-ALVEOLAR FRACTURES

CORONAL FRACTURES
- **ENAMEL INFRACTIONS**
- **ENAMEL FRACTURES**
- **ENAMEL-DENTINE FRACTURES WITHOUT PULP EXPOSURE**
- **ENAMEL-DENTINE FRACTURES WITH PULP EXPOSURE**

RADICULAR FRACTURES

CORONO-RADICULAR FRACTURES

ALVEOLAR FRACTURES

MAXILLARY FRACTURES

Post-traumatic coronal fractures

Among coronal fractures, enamel infractions are simple cracks, while enamel fractures produce tissue loss (Güngör 2014). Coronal enamel-dentine fractures affect enamel and coronal dentine, while corono-radicular fractures involve enamel, dentine and cement; both fractures can cause pulp exposure (Güngör 2014).

Unless concomitant luxation or root fracture occur, no mobility, no sensitivity to percussion, no altered response to sensitivity tests are associated. An initial negative response to sensitivity tests indicates greater risk of healing complications (Diangelis et al. 2012). A negative initial response to sensitivity tests indicates greater risk of healing complications (Andreasen & Kahler 2015). An initial negative response to the electric pulp test does not indicate the presence of pulp necrosis but only the increased risk of late necrosis (Table1) (Diangelis et al. 2012, Patel et al. 2015). Concomitant luxation increases the risk of pulp necrosis, reported to occur in 34.5-73.3% of cases (Güngör 2014, Hecova 2010).

Conservative or prosthetic restorative procedures are indicated (Güngör 2014). If the fracture exposes the pulp in teeth with immature roots, is indicated to perform pulp cupping or pulpotomy to allow root development, using an appropriate material in association to an adhesive resin composite restoration (Güngör 2014, Diangelis et al. 2012). If the traumatic exposure of the pulp affects teeth with mature

roots, the decision to perform endodontic treatment should be taken based on the hypothetical pulp damage (Güngör 2014); in elderly patients or when it is associated with luxation, endodontic treatment is indicated (Diangelis et al. 2012).

Clinical and radiographic examination should be performed 6-8 weeks and 1 year after the trauma to monitor the state of the pulp (Diangelis et al. 2012), but in doubtful cases they have to be protracted over time.

In the absence of pulp exposure, the prognosis is favorable. If the fracture rhyme is close to the pulp, late-necrosis appears in 2-5% of cases, if there is an associated luxation the risk of necrosis increases (Güngör 2014, Hecova et al. 2010). In cases of pulp exposure, if the vitality of the pulp has been preserved, complications such as obliteration of the canal, pulpitis and pulp necrosis may arise (Diangelis et al. 2012).

Post-traumatic radicular fractures

Post-traumatic radicular fractures tend to be oblique or horizontal and affect cement, dentine and pulp (Diangelis et al. 2012). They are caused by a frontal impact that causes palatal dislocation and mild extrusion of the fractured coronal fragment, often with laceration of the pulp. Maintaining the vitality of the pulp is influenced by the degree of apical maturation (Diangelis et al. 2012), the location of the fracture rhyme, the extent of the dislocation, and the distance between the fragments: the greater the distance, the more likely the pulp necrosis of the coronal fragment is (Andreasen & Kahler 2015).

The general recommendations for the treatment of dento-alveolar trauma lesions are listed in Table 1.

The tooth may appear extruded and dislocated palatably, mobile and painful to percussion. The tests of sensitivity are not trusted immediately after trauma (Diangelis et al. 2012). An immediate negative response to the electrical test can return positively after 1-12 months and does not therefore indicate pulp necrosis, but only an increased risk of late necrosi (Andreasen & Kahler 2015). In radicular fractures, the diagnosis of pulp necrosis is based on the radiographic amplification of the space between the two fragments and / or radiotransparency adjacent to the fracture site, as well as on the appearance of gray coronal discoloration or a fistula tract (Diangelis et al. 2012). By employing two-dimensional radiological techniques, the fracture is only apparent if the beam and fracture line coincide (Patel et al. 2015), therefore diagnosis may be difficult and require multiple projections or, alternatively, the use of CBCT (Diangelis et al. 2012, Patel et al. 2015).

If there is excessive mobility of the coronal fragment, it should be stabilized with elastic splint, usually for no more than 4 weeks, but up to 4 months if the fracture affects the third coronary root (Diangelis et al. 2012).

Many post-traumatic root fractures repair spontaneously, with either formation of hard tissue or interposition of soft tissue between the fragments (Andreasen & Kahler 2015). Repair can take years.
When root fractures occur in immature teeth, rare occurrence because of the resilience of the support tissues, repair with calcified tissue is likely and usually no endodontic treatment is required (Andreasen et al. 2004). In mature teeth the blood supply to the apical fragment is usually preserved, so if pulp necrosis occurs it often only affects the canal portion of the coronal fragment (Cvek et al. 2004) and only that should be endodontically treated, using a material able to induce the formation of a barrier of hard tissue at the fracture line and filling the coronal the coronal fragment with gutta–percha (Cvek et al. 200, (Bakland & Andreasen 2012).
Pulp sensitivity and tooth mobility should be controlled over tim. Sensitivity tests and radiographic controls should be carried out 3 weeks, 6 weeks and 3 months after injury (Diangelis et al. 2012).
In the unusual case of necrosis in the apical fragment, it should be decided whether to extend the treatment to the apical fragment or to extract it. If mobility persists despite initial splinting, the tooth crown may be permanently fixed to adjacent teeth with composite resin and adhesive techniques. The factors affecting repair probability include age, developmental stage, mobility, fragment dislocation, separation between apical and coronal fragments. Prognosis is more favorable (Andreasen & Kahler 2015) and necrosis is less frequent in mature teeth, when the displacemet of the coronal fragment occurs, and in cases with minimal displacement of the coronal fragment the prognosis is better ((Andreasen & Kahler 2015, Diangelis et al. 2012)
Other complications, such as resorptions, ankylosis and loss of bone support, are rare (Andreasen et al. 2004). The long-term prognosis is worse when the fracture involves the coronal third of the root (Andreasen et al. 2004).

Post-traumatic corono-radicular fractures

Post-traumatic root fractures are fractures, often oblique, affecting both the crown and the root of the teeth, involving enamel, dentin and cement. The pulp is often exposed. The clinical picture is produced by the combination of the signs and symptoms caused by coronal and radicular fractures described above. Multidisciplinary treatment and prognosis vary depending on the location of the fracture, its apical level, relative to the bone crest and the amount of residual root. (Güngör et al. 2014).

Alveolar and maxillary fractures

Crown-root fractures and post-traumatic dental luxations can be associated with alveolar and maxillary fractures. They produce complex clinical frameworks whose management requires multidisciplinary skills (Andreasen & Lauridsen 2015, Rahimi-Nedjat et al. 2014).

Bibliography

Andreasen FM, Kahler B. Pulpal response after acute dental injury in the permanent dentition: clinical implications-a review. J Endod 2015;41:299-308.

Andreasen JO, Andreasen FM, Mejàre I, Cvek M. Healing of 400 intra-alveolar root fractures. 1. Effect of pre-injury and injury factors such as sex, age, stage of root development, fracture type, location of fracture and severity of dislocation. Dent Traumatol 2004;20:192-202.

Andreasen JO, Lauridsen E. Alveolar process fractures in the permanent dentition. Part 1. Etiology and clinical characteristics. A retrospective analysis of 299 cases involving 815 teeth. Dent Traumatol 2015;31:442-7.

Bakland LK, Andreasen JO. Will mineral trioxide aggregate replace calcium hydroxide in treating pulpal and periodontal healing complications subsequent to dental trauma? A review . Dent Traumatol 2012;28:25-32.

Cvek M, Mejàre I, Andreasen JO. Conservative endodontic treatment of teeth fractured in the middle or apical part of the root. Dent Traumatol 2004;20:261-9.

Diangelis AJ, Andreasen JO, Ebeleseder KA, Kenny DJ, Trope M, Sigurdsson A, Andersson L, Bourguignon C, Flores MT, Hicks ML, Lenzi AR, Malmgren B, Moule AJ, Pohl Y, Tsukiboshi M. International Association of Dental Traumatology guidelines for the management of traumatic dental injuries: 1. Fractures and luxations of permanent teeth. Dent Traumatol 2012;28: 66-71.

Güngör HC. Management of crown-related fractures in children: an update review. Dent Traumatol 2014;30:88-99.

Hecova H, Tzigkounakis V, Merglova V, Netolicky J. A retrospective study of 889 injured permanent teeth. Dent Traumatol 2010;26:466-75.

Patel S, Durack C, Abella F, Shemesh H, Roig M, Lemberg K. Cone beam computed tomography in Endodontics - a review. Int Endod J 2015;48:3-15.

Rahimi-Nedjat RK, Sagheb K, Walter C. Concomitant dental injuries in maxillofacial fractures - a retrospective analysis of 1219 patients. Dent Traumatol 2014;30:435-41.

Treatment of traumatic injuries of endodontic interest

Luxation

The term "luxation" identifies a series of injuries of different gravity, caused by traumas, which may affect teeth and their supporting structures.

In a high percentage of cases (over 80%), elements of the upper frontal group are involved (Glendor 2009).

Those, normally linked to traumas with reduced impact velocity may coexist with other traumatic pathologies such as fractures and require, in such cases, a complementary treatment (Polimeni 2012).
The most recent classifications (Di Angelis 2012) distinguish, by gravity:

- concussion
- subluxation
- extrusion
- lateral luxation
- intrusive luxation

The first two clinical conditions are less severe and those with the best prognosis for the elements involved (AAE 2014 guidelines); usually they do not require treatment but they need a careful follow up to evaluate and treat any pulp impairment (TAB.1).
Extrusion and lateral luxation are two pathological situations where pulp and periodontal damage coexist, which need to be evaluated radiographically with different projections. The outcome may change from complete regeneration/repair of damaged tissues to pulpal necrosis, external root reabsorption, or periodontal attachment loss. The prognosis depends on the degree of root development of the subject involved and the follow-up should be continued for at least 5 years (Robertson 2000).
Intrusive luxation is one of the most critical post-traumatic manifestations that almost always leads to ~~the~~ pulp necrosis of the affected teeth with completely formed apex and is associated with a high risk of radical resorption (Trope 2002). In uncertain cases the follow-up should continue for at least 5 years.
In case of concussion or subluxation, treatment includes the reduction of occlusal interferences, a two-week soft diet and the possible stabilization of the affected tooth.
In case of extrusion or lateral luxation, treatment should be started as soon as possible with the repositioning of the tooth and eventually a non-rigid stabilization for a period of 2-4 weeks (and beyond, in case of radiographic evidence of periodontal lesion), in order to allow periodontal ligament healing (Andreasen 2006*). If pulpal necrosis or irreversible pulpitis are occurring, endodontic treatment is indicated (Barnett 2002, Ferrazzini Pozzi 2008). In this case, the treatment of open apex teeth is different from that with a completely formed apex, since it is possible to allow the complete root development by means of an apexification procedure or apexogenesis, (Garcia-Godoy 2012, Diogenes 2013).
In case of an intrusive luxation the treatment changes, depending on the degree of development of the tooth. For teeth with an incomplete apex formed it is recommended to wait for a spontaneous eruption for a few months, and then intervene, if necessary, orthodontically or surgically. The same can be stated for completely formed teeth, but in this case, the waiting period is reduced to 2-4 weeks and the possibility of preventive pulpectomy should be considered (Andreasen 2006**).

Bibliography

American Association of Endodontists. Colleagues for Excellence. The treatment of traumatic dental injuries. Summer 2014.

*Andreasen JO, Andreasen EM. Essentials of traumatic injuries to the teeth. Blackwell Munksgaard, reprinted 2006, 77-112. **

*Andreasen JO, Bakland LK, Andreasen FM. Traumatic intrusion of permanent teeth. Part 3. A clinical study of the effect of treatment variables such as treatment delay, method of repositioning, type of splint, length of splinting and antibiotics on 140 teeth. Dental Traumatology 2006;22: 99-111. ***

Barnett F. The role of endodontics in the treatment of luxated permanent teeth. Dent Traumatol 2002; 18: 47-56.

DiAngelis AJ, Andreasen JO, Ebeleseder KA, KennyDJ, Trope M, Sigurdsson A, Andersson L, Bourguignon C, Flores MT, Lamar Hicks M, Lenzi AR, Malmgren B, Moule AJ, Pohl Y, Tsukiboshi M. International Association of Dental Traumatology guidelines for the management of traumatic dental injuries: 1. Fractures and luxations of permanent teeth. Dental Traumatology 2012; 28: 2–12.

Diogenes A, Henry M, Texeira F, Hargreaves K. An update on clinical regenerative endodontics. Endodontic Topics 2013, 28: 2-23.

Ferrazzini Pozzi EC, von Arx T. Pulp and periodontal healing of laterally luxated permanent teeth: results after 4 years. Dent Traumatol 2008;24: 658-662.

Garcia-Godoy F, Murray PE. Recommendation for using regenerative endodontic procedures in permanent immature traumatized teeth. Dental Traumatology 2012; 28: 33-41.

Glendor U. Aetiology and risk factors related to traumatic dental injuries: a review of the literature. Dent Traumatol 2009;25: 19-31.

Polimeni A. Odontoiatria pediatrica. Elsevier, 2012. 191-192.

Robertson A, Andreasen FM, Andrease JO, Norén JG. Long-term prognosis of crown-fractured permanent incisors. The effect of stage of root development and associated luxation injury. Int J Paediatr Dent 2000; 10:191-199.

Trope M. Root resorption due to dental trauma. Endodontic Topics 2002; 1: 79–100.

Tooth reimplantation

Avulsion of permanent teeth is seen in 0.5-3% of all traumatic dental injuries (Andreasen 2007, Glendor 1996). Replantation is in most situations the treatment of choice, but cannot always be carried out immediately. An appropriate emergency management and treatment plan are important for a good prognosis.

As all the correct clinical approaches, anamnesis has a role of primary importance for a correct framing of dental trauma. Informations on the modalities of the trauma should be recorded to allow a more effective legal protection of the patient, and possibly indicate the occurrence of contamination by making tetanus prophylaxis necessary.

Knowing how the trauma occurred can lead to the identification of the anatomical parts involved and consequently evaluate the presence of possible foreign bodies. Finally, knowledge of the time between the trauma and the first aid and how the tooth has been recovered and treated.

There are two types of reimplantation, which differ according to the time when the tooth was out of the socket: early and delayed reimplantation.

Early reimplantation can be carried out when the periodontal ligament is still viable, it should take place within a maximum of 60 minutes from the avulsion if the tooth was properly stored in a physiological solution, saliva or milk. The aim of the early reimplantation is to obtain the reattachment of the viable periodontal fibers and recreate a restitutio ad integrum of the periodontal ligament itself.

Operative phases include: clean the root surface and apical foramen with a stream of saline and soak the tooth in saline thereby removing contamination and dead cells from the root surface, administer local anesthesia, irrigate the socket with saline, Replant the tooth slowly with slight digital pressure, verify normal position of the replanted tooth both clinically and radiographically, apply a flexible splint for up to 2 weeks, keep away from the gingiva, administer systemic antibiotics, check tetanus protection, initiate root canal treatment 7–10 days after replantation and before splint removal (Panzarini 2008, Esper 2007, Cohenca 2007).

Delayed reimplantation occurs when the periodontal ligament is not viable, when the trauma history tells us that the total extra-oral dry time has been more than 60 minutes.

Operative phases include:

Remove attached non-viable soft tissue carefully with gauze, root canal treatment should be done either on the tooth prior to replantation, or it can be done 7–10 days later, administer local anesthesia, irrigate the socket with saline, replant the tooth, verify normal position of the replanted tooth clinically and radiographically, stabilize the tooth for 4 weeks using a flexible splint, administration of systemic antibiotics, check tetanus protection (Levin 2010).

Regarding the use of antibiotics, studies in the literature suggest systemic antibiotic prophylaxis to prevent complications, a two and a half higher failure has been calculated in cases in which antibiotic is not to used. Tetracycline is the first choice in appropriate dose for patient age and weight the first week after replantation; penicillin is the second choice (Andreasen 2006, Bryson 2003). Refer the patient to a physician for evaluation of need for a tetanus booster if the avulsed tooth has contacted soil or tetanus coverage is uncertain (Trope 2011).

Regarding splinting of replanted teeth, current scientific evidence suggest to splint up to 2 weeks replanted permanent teeth. Studies have shown that periodontal and pulpal healing (in relation to the maturity of the root) is promoted if the replanted tooth is given a chance for slight motion and the splinting time is not too long (Kahler 2008, Hinckfuss 2009).

Replanted teeth should be monitored by clinical and radiographic control after 4 weeks, 3 months, 6 months, one year and yearly thereafter. Clinical and radiographic examination will provide information to determine outcome (Andreasen 1995).

The protocols described above could be applied to extraction with intentional reimplantation. The aim of the extraction with intentional reimplantation is represented by the extraction of tooth from its socket with subsequent endodontic treatment and/or apicectomy and retrograde obturation out of oral cavity and then reimplantation. This procedure is necessary when orthograde therapy is not possible or success not achieved and when traditional endodontic-surgical therapy is not viable. Studies demonstrate a survival rate exceeding 88% at one year (Chung 2014).

There is no scientific evidence of these results in the long term.

Bibliography

Andreasen JO, Andreasen FM. Avulsions. In: Andreasen JO, Andreasen FM, Andersson L, editors. Textbook and color atlas of traumatic injuries to the teeth, 4th edn. Oxford, UK: Wiley-Blackwell; 2007. p. 444–88.

Andreasen JO, Borum MK, Jacobsen HL, Andreasen FM. Replantation of 400 avulsed permanent incisors. 1. Diagnosis of healing complications. Endod Dent Traumatol 1995;11:51–8.

Andreasen JO, Storgaard Jensen S, Sae-Lim V. The role of antibiotics in presenting healing complications after traumatic dental injuries: a literature review. Endod Topics 2006;14:80–92.

Bryson EC, Levin L, Banchs F, Trope M. Effect of minocycline on healing of replanted dog teeth after extended dry times. Dental Traumatol 2003;19:90–5.

Chung WC, Tu YK, Lin YH, Lu HK. Outcomes of autotransplanted teeth with complete root formation: a systematic review and meta-analysis. J Clin Periodontol. 2014 Apr;41(4):412-23.

Cohenca N, Stabholz A. Decoronation – a conservative method to treat ankylosed teeth for preservation of alveolar ridge prior to permanent prosthetic reconstruction: literature review and case presentation. Dent Traumatol 2007;23:87–94.

Glendor U, Halling A, Andersson L, Eilert-Peterson E. Incidence of traumatic tooth injuries in children and adolescents in the county of Västmanland, Sweden. Swed Dent J 1996;20:15–28.

Esper HR, Panzarini SR, Poi WR, Sonoda CK, Casatti CA. Mechanical removal of necrotic periodontal ligament by either Robinson bristle brush with pumice or scalpel blade. Histomorphometric analysis and scanning electron microscopy. Dent Traumatol 2007;23:333–9.

Hinckfuss S, Messer LB. Splinting duration and periodontal outcomes for replanted avulsed teeth, a systematic review. Dent Traumatol 2009;25:150–7.

Kahler B, Heithersay GS. An evidence-based appraisal of splinting luxated, avulsed and root-fractured teeth. Dent Traumatol. 2008 Feb;24(1):2-10.

Levin L, Jeffet U, Zadik Y. The effect of short dental trauma lecture on knowledge of high-risk population: an intervention study of 336 young adults. Dent Traumatol 2010;26:86–9.

Panzarini SR, Gulinelli JL, Poi WR, Sonoda CK, Pedrini D, Brandini DA. Treatment of root surface in delayed tooth replantation: a review of literature. Dent Traumatol 2008;24:277–82.

Trope M. Avulsion of permanent teeth: theory to practice. Dent Traumatol 2011;27:281–94.

Radicular resorption

Tissue resorption of permanent teeth should be considered the expression of a transitory or progressive pathological event triggered by the activation of clustered cells (Lyroudia et al. 2002, Tronstad et al. 1988)

Origin

The source can be periodontal (external root resorption) (Ne et al.1999, Andreasen 1985) and invasive external cervical resorption (Heithersay 1999, Frank et al.1998), resulting from a breakdown of the radicular cement, or endodontic (internal root resorption) (Patel et al. 2010, Haapasalo et al. 2006, Nilsson et al. 2013) due to a persistent inflammatory stimulus produced on canal walls by infected pulp tissue, not completely necrotic.

Cause

External resorption may be due to a damage to the root ceementum by mechanical causes (dental trauma) (Andreasen et al. 2007, Trope 2002), orthodontic movement (Maues et al 2015), disodontiasis, tumor mass, autotransplantation, intentional replantation (Panzarini et al. 2008), periodontal or dento-alveolar surgery (Andreasen et al. 1981), chemical and thermal damage (Patel et al. 2010, Cvek 1985, Dahal 2003), infectious causes such periodontisis, or it can be associated to systemic diseases. Sometimes the origin of the resorption remains unknown (idiopathic resorption) (Darbar et al.2003).

Internal resorption may be due to damage to the internal root surface or may be caused by a trauma or by an intracanal infection (Andreasen et al. 2007). The spread of the infection in the outer root surface, especially in the periapical area, causes a damage to the cement resulting in resorptive areas in the periapex(Ne et al. 1999, Andreasen 1985, Friedman et al. 1988).

Evolution

The resorptive process may stop if the triggering cause is missing but its evolution preserves margins of unpredictability (Tronstad 1988).

Symptomatology

Internal and external radicular resorption frequently evolve in the absence of symptoms and are randomly diagnosed during a radiographic investigation. Symptoms of an acute pulpitis may occur if external resorption involves the pulp (Tronstad 1988). An external resorption localized in the sub-crestal site may occur with periodontal abscess (Andreasen et al. 1985).

Diagnosis

Diagnosis is generally radiographic. Often it is difficult to determine the source of resorption by reading a two-dimensional X-ray image, especially when the resorptive area is not located at the interproximal level, whereas a CBCT may be the crucial examination (Patel et al. 2010, Lyroudia 2002). Pulp sensitivity tests can be positive both in external and internal resorption and do not help in differential diagnosis. Only invasive cervical resorption can be differentially diagnosed by a pink tooth discoloration. If resorption involves the coronal part of the root it is possible to detect soft tissue inflammation and a periodontal probing in the affected area (Andreasen 1985).

Treatment

The importance of a differential diagnosis between internal and external resorption has strict therapeutic and prognostic implications. Internal resorption: the progression of the internal root resorption stops with endodontic treatment, which is effective if performed before the loss of radicular tissue is too wide in the centrifugal direction. External apical resorption also stops after endodontic treatment (Patel et al., 2010, Tronstad 2009).

External resorption: the progression of external (non-periapical) resorption is not affected by the endodontic treatment which is only necessary when the pulp is involved, and the severity of its evolution often results in the extraction of the tooth. Therapy consists in the exposure of the resorptive area whenever possible, in the complete elimination of the inflammatory tissue and in the restoration of the residual cavity with a suitable material (Frank et al. 1998, Trope 1998, Panzarini et al. 2008, Main et al 2004, Cvek 1993).

Prognosis

The prognosis of external root resorptions depends on the extent of the dentinal loss, the site of resorption and its progression (Andreasen 1985). Teeth with rapidly progressive resorption may have a poor short-term prognosis, regardless of a proper therapy.

The prognosis of internal root resorption is good after proper endodontic treatment if the loss of root structure has not compromised the mechanical integrity of the tooth, therefore early diagnosis can change the prognosis of the tooth (Patel et al., 2010). The most common complication is the horizontal fracture of the root involved.

Bibliography

Andreasen J, Andreasen F, Andersson L, eds. Text- book and color atlas of traumatic injuries to the teeth, 4th ed. Oxford: Blackwell Munksgaard; 2007.

Andreasen, J.O. & Kristerson, L. (1981). Evaluation of different types of autotransplanted connective tissues as potential periodontal ligament substitutes. International Journal of Oral Surgery 10, 189–201.

Andreasen, J.O.. External root resorptions: its implication in dental traumatology, paedodontics, periodontics, orthodontics and endodontics. International Journal of End- odontics1985; 8, 109–118.

Cvek M, Lindvall AM. External root resorption following bleaching of pulpless teeth with oxygen peroxide. Dental Traumatology 1985;(2):56-60.

Cvek, M. (1993). Endodontic management of traumatized teeth. In: Andreasen, J.O. & Andreasen, F.M., eds. Textbook and Color Atlas of Traumatic Injuries to the Teeth. Copenhagen: Munksgaard, pp. 517–585.

Dahal JE,Pallesen U. Tooth bleaching – A critical review on the biological aspects.Crit Rev Oral Biol Med(2003);14(4):292-304.

Darbar UR, Jenkins CBG. Multiple external root resorption: case report. Austr DentJ1993;38:433-5.

Frank AL, Bakland LK. Nonendodontic therapy for supraosseous extracanal invasive resorption. J Endod 1987;13:348-55.

Frank AL, Torabinejad M. Diagnosis and treatment of extracanal invasive resorption. J Endod 1998;7:500-4.

Friedman S, Rotstein I, Libfeld H, Stabholz A, Heling I. Incidence of external root resorption and esthetic results in 58 bleached pulpless teeth. Endod Dent Traumatol 1988;4:23-6.

Heithersay GS. Invasive cervical resorption: an analy- sis of potential predisposing factors. Quintessence Int 1999;30:83-95.

Lyroudia KM, DourouVI, Pantelidou OC, LabrianidisT, Pitas IK. Internal root resorption studied by radiography, stereomicroscope, scanning electron microscope, and computerized 3D reconstructive method. Dent Traumatol 2002;18:148-52.

M. Haapasalo and U. Endal, "Internal inflammatory root resorption: the unknown resorption of the tooth," Endodontic Topics, vol. 14, pp. 60–79, 2006.

Main C, Mirzayan N, Shabahang S, Torabinejad M. Repair of root perforations using mineral trioxide aggregate: a long term study. J Endod 2004;30:80–3.

Maués CP, do Nascimento RR, Vilella Ode V. Severe root resorption resulting from orthodontic treatment: prevalence and risk factors. Dental Press J Orthod. 2015 Jan-Feb;20(1):52-8

Ne RF, Witherspoon DE, Gutmann GL. "Tooth resorption," Quintessence International 1999, vol. 30, no. 1, pp. 9–25.

Nilsson E,Bonte E, Bayet F,Lasfargues JJ. Management of Internal Root Resorption on Permanent Teeth.Int J Dent 2013

Panzarini SR,Gulinelli JL, Poi WR, Sonoda CK, Pedrini D, Brandini DA. Treatment of root surface in delayed tooth replantation: a review of literature. Dent Traumatol 2008; 24(3):277-82.

Rankow HJ, Krasner PR. Endodontic applications of guided tissue regeneration in endodontic surgery. Oral Health 1996;86:33-5.

Shanon Patel, Domenico Ricucci, Conor Durak, Franklin Tay. Internal Root Resorption: A Review J Endod. 2010 Jul;36(7):1107-21

Tronstad L. Endodontic aspects of root resorption. In: Tronstad L, ed. Clinical endodontics: a textbook. 3rd ed. Stuttgart: Thieme; 2009.

Tronstad L. Root resorption:etiology, terminology and clinical manifestations. Endod Dent Traumatol 1988;4:241-52.

Trope M. Root resorption due to dental trauma. Endodontic Topics 2002;1:79-100.

Trope M. Subattachment inflammatory root resorption: treatment strategies. Pract Periodontics Aesthet Dent. 1998;10:1005-10.

Crown bleaching

Intracoronal bleaching is useful in teeth that present with crown discoloration. Such discolorations could be caused by:

- pulp hemorrage: it represents the most frequent cause of dental discoloration following trauma. Blood enters the dentinal tubules where it decomposes, causing deposits of chromogenic degradation products. (Arens,1989).
- pulp necrosis: it causes the diffusion of degradation products which create discoloration
- pulp calcification: it causes discoloration due to the obliteration of the dentinal tubules and formation of a new dentine layer with the maintenance of pulp vitality. Often observed following trauma. (Watts,2001),
- Irrigants: the combination of sodium hypochlorite (even at low concentration) and chlorexidine determine reddish- brown precipitate. (Basrani,2007)-Inadequate endodontic treatments: the incomplete removal of necrotic tissue, the use of root canal sealers or obturating materials which release made of eugenol metallic salts may cause the discoloration/ pigmentation of the tooth. .(Vanini,2003)(Plotino,2008).

Mechanism of bleaching

Dischromic spots are caused by chemicals or chromogenic agents. Bleaching agents act on the molecular chains of pigments that are oxidized and transformed into water and carbonium, that are then dissolved together with with new oxygen.

The application of heat to the bleaching procedure may cause problems related to root resorption.

The use of dyode laser does not improve bleaching in comparison with the use of an alternative light source like a halogen lamp. (Gontijo ,2008) (Attin ,2003)

Bleaching agents:

- Hydrogen peroxide: is an effective whitening agent, however high concentration should be used with caution to avoid the risk for root resorption .(Attin ,2003)
- Sodium perborate: monohydrate,trihydrate or tetrahydrate currently used with the addition of water release hydrogen peroxide. (Ari,2002).

Currently, there are very few studies on the use of sodium carbonate but thanks to a coating process, this product is a whitening agent in commerce. Combined with 30% hydrogen peroxide, it does not penetrate deeply into the dentin and therefore has no effect on its microhardness. (Kaneko ,2000)

- Carbamide peroxide: an organic compound containing hydrogen peroxide and urea. It shows a whitening capacity equal to hydrogen peroxide and an excellent dentin penetration. (Lim,2004)

Scientific literature agrees on the need for further insights about the use of these materials *in vivo*.

Bleaching procedures:

- Internal bleaching: (the walking bleach)(Spasser 1981).Compared to others, this technique is the easiest and most predictable method because its results are more evident and maintained in the long term. .(Zimmerli ,2010)

Before starting treatment:

- Inform the patient through informed consent;
- The dental element to be treated must be asymptomatic;
- Acquire photographic documentation and detect the degree of discoloration using a standard colour scale;
- Carry out an intraoral radiograph to have a T0 and therefore a useful document for highlighting any alterations following bleaching.

Stages of Treatment:

- Isolation with rubber dam or a similar device;
- Canal Filling Seal: It is an important requirement for whitening the element;
- Elimination of residual from root canal-filling materials and eventual restoration to promote the adaptation of the whitening agent to the dental surfaces, if necessary perform the temporary rebuilding of the missing walls;
- Determine a free space of 2-3 mm from the cervical margin;
- Form a base by sealing the root canal cement with the zync ossiphosphate or glass ionomer cement to prevent the whitening agent from diffusing into the periodontal space. The base should be more

accurate in case of perforation closed with MTA; In fact, this material has a very small marginal seal when in contactwith bleaching agents. (De Oliveira,2003). Where the dental walls are very thin, the application of low concentrations of whitening agent (if sodium peroxide is used, it must be mixed with distilled water) is recommended;

- Apply bleaching agent;
- Seal the access with temporary filling;
- Inform the patient that they should make the operator aware of symptom following treatment;
- Recall the patient after 2-3 days to assess the degree of bleaching obtained;
- If necessary repeat the application until the desired result is obtained;
- Do not immediately perform the definitive restoration of the treated element to stabilized the result. In this intermediate period, a calcium hydroxide application is recommended to counteract the increase in dentin permeability and to increase the PH; .(Demarco2001)
- perform the definitive restoration;
- Monitor the patient over time with radiographic controls.

In office Bleaching: The procedure is similar to the internal bleaching technique, but it differs on few points: 1. the permanence time of the whitening agent, which is limited to 15 minutes; once it is removed and eventually reapplied, it is eliminated with an irrigation of sodium hypochlorite followed by a rinse with water; and 2. the whitening agent must have a greater concentration in order to act in a shorter time. (Lai 2002)

Bibliography

Arens D: The role of bleaching in esthetics. Dent Coin North Am 33: 319–336 (1989)

Ari H, Ungör M: In vitro comparison of different types of sodium perborate used for intracoronal bleaching of discoloured teeth. Int Endod J 35: 433–436 (2002)

Attin T, Paqué F, Ajam F, Lennon Á M: Review of the current status of tooth whitening with the walking bleach technique. Int Endod J 36: 313–329 (2003)

Basrani B R, Manek S, Sodhi R N, Fillery E, Manzur A: Interaction between sodium hypo- chlorite and chlorhexidine gluconate. JEndod 33: 966–969 (2007)

Dietschi D, Rossier S, Krejci I: In vitro colorimetric evaluation of the efficacy of various bleach- ing methods and products. Quintessence Int 37: 515–526 (2006)

Demarco F F, Freitas J M, Silva M P, Justino L M: Microleakage in endodontically treated teeth: influence of calcium hydroxide dressing fol- lowing bleaching. Int Endod J 0134: 495–500 (2001)

De Oliveira L D, Carvalho C A, Hilgert E, Bondioli I R, De Araújo M A, Valera M C: Sealing evaluation of the cervical base in intracoronal bleaching. Dent Traumatol 19: 309–313 (2003)

Gontijo I T, Navarro R S, Ciamponi A L, Zezell D: Whitening techniques using the diode laser and halogen lamp in human devitalized primary teeth. J Dent Child 75: 164–167 (2008)

Kaneko J,Inoue S,Kawakami S,Sano H:Bleaching effetc of sodium percarbonate on discolored pulpless teeth in vitro.J Endod 26:25-28 (2000)

Lai SCN,Tay F R,Cheung G S ,Ma Y F,Carvalho R M,Wei S H Y ,Toledano M,Osorio R,Pashley D H:Reversal of compromised bonding in bleached enamel.j Dent res:81.477-481 (2002)

Lim M Y, Lum S O Y, Poh R S C, Lee G P, Lim K-C: An in vitro comparison of the bleaching efficacy of 35% carbamide peroxide with established intracoronal bleaching agents. Int En- dod J 37: 483–488 (2004)

Loxley E C, Liewehr F R, Buxton T B, McPherson JC 3rd: The effect of various intracanal oxidizing agents on the push-out strength of various perforation repair materials. Oral Surg Oral Pathol Oral Radiol Endod 95: 490–494 (2003)

Plotino G, Buono G, Grande N M, Pameier C H, Somma F: Nonvital tooth bleaching: a review of the literature and clinical procedures. J Endod 34: 394–407 (2008)

Spasser H F :A simple bleaching technique using sodium perborate .New York State Dent.J 27 :332-334 (1961)

L.Vanini, O. Klimovskaia, F. Mangani. Il restauro conservativo dei denti anteriori ACME, 2003.

Watts A, Addy M: Tooth discoloration and staining. A review of literature. Br Dent J 190: 309– 316 (2001)

Zimmerli B, Jeger F, Lussi A. Klinik für Zahnerhaltung. Bleaching of nonvital teeth: a clinically relevant literature review. 2010;120(4):306-13

Surgical Endodontics: Apicoectomy with Retrofill

This procedure is performed on all teeth with a periapical lesion of endodonic origin where it is impossible to carry out a root canal retreatment through the access cavity due to the presence of different kinds of obstacles (screw posts, cast post, ledges) or when the original anatomy has been altered by the previous treatment and it is impossible to negotiate the original canal (Gorni 2004).
Since the procedure requires extreme precision, it is highly recommended to perform the surgical procedure using a magnification system in accordance with the operator's choice . (Kim, et al, 2006; Rubinstein, et al, 2002; Setzer et al. Part I, 2010; Setzer et al Part II, 2012; Song, et al 2011; Song et al 2011; Tsesis et al 2013).

After making a correct treatment plan based on a correct radiographic and clinical examination, the procedure is started by providing the patient with an adequate local anesthesia, enough to guarantee a perfect anesthesia of the operative field and a good vasoconstriction of the tissues.

When the tissues appear to be completely anesthetized, the incision is made, a full thickness flap is elevated which will guarantee an optimal visibility of the surgical field. Then, if the cortical bone plate is still present, an opening is made in order to expose the root apex of which a few millimeters will be

resected and removed together with the granulation tissue. This will allow a good surgical access, a good visibility of the apical portion of the root canal and a good control of the bleeding. The objective is to save as much as possible of the root structure and the root length.

Now a class one cavity is prepared along the main axis of the root canal using the specifically designed ultrasonic tips, which have the same dimensions of the root canal lumen and sufficient length for an adequate depth preparation, characteristics not obtainable with slow speed burs.
The cavity is then sealed with a specific material ,like MTA or similar materials, which will guarantee a good seal and biocompatibility, (Saunders 2008, Torabinejad 1993, Torabinejad 1995, Torabinejad 1999; Koh, et al 1997)). For these reasons the use of amalgam is not indicated any more (Torabinejad 1994). The purpose of the retrofill is to seal any communication, apical or lateral, between the root canal system and the attachment apparatus. This communication could not be sealed before non-surgically. The retrofilling material must be radiopaque and easily recognizable in the intra-operative radiograph. It should have all the caracteristics of the root canal filling material. After positioning the retrofilling material, the surgical flap must be carefully repositioned and sutured. At the end of the surgical procedure, a post-operative radiograph is taken. Every six month for at least two years a recall radiograph should be taken to document the healing of the lesion.

Bibliography

Gorni, F.G.M., Gagliani, M.: The outcome of endodontic retreatment: a 2-yr follow-up. J. Endod. 30(1):1-4, 2004.

Kim, S., Kratchman, S.: Modern endodontic surgery concepts and practice: a review. J. Endod. 32:601–23, 2006.

Koh, E.T., Torabinejad, M., Pitt Ford, T.R., Brady, K.: Mineral trioxide aggregate stimulates a biological response in human osteoblasts. J. Biomed. Mater. Res. 37:432, 1997.

Rubinstein, R., Kim, S.: Long-term follow-up of cases considered healed one year after apical microsurgery. J. Endod. 25:378-83, 2002.

Saunders, W.P.: A Prospective Clinical Study of Periradicular Surgery Using Mineral Trioxide Aggregate as a Root-end Filling. J. Endod. 34(6): 660-665, 2008.

Song M, Shin S-J., Kim E.: Outcomes of endodontic micro-resurgery: a prospective clinical study. J. Endod. 37:316–20, 2011.

Song, M., Jung, I., Lee, S.J., Lee, C.Y., Kim, E.: Prognostic factors for clinical outcomes in endodontic microsurgery: a retrospective study. J. Endod. 37(7):927-33, 2011.

Torabinejad, M., Watson, T.F., Pitt Ford, T.R.: The sealing ability of a mineral trioxide aggregate as a retrograde root filling material. J. Endod. 19:591, 1993.

Torabinejad, M., Hong, C.U., Pitt Ford, T.R., Kettering, J.D.: Cytotoxicity of four root end filling materials. J. Endod. 21:489, 1995.

Torabinejad, M., Rastegar, A.F., Kettering, J.D., Pitt Ford, T.R.: Bacterial leakage of mineral trioxide aggregate as a root end filling material. J. Endod. 21:109, 1995.

Torabinejad, M., Hong, C.U., McDonald, F., Pitt Ford, T.R.: Physical and chemical properties of a new root-end filling material. J. Endod. 21:349, 1995.

Torabinejad, M., Chivian, N.: Clinical applications of mineral trioxide aggregate. J. Endod. 25:197-203, 1999.

Torabinejad, M., Higa, R.K., McKendry, D.J., Pitt Ford, T.R.: Dye leakage of four root-end filling materials: effects of blood contamination. J. Endod. 20:159, 1994.

Tsesis, I., Rosen E., Taschieri, S., Strauss, Y.T., Ceresoli, V., Del Fabbro, M.: Outcomes of surgical endodontic treatment performed by a modern technique: an updated meta-analysis of the literature. J. Endod. 39(3):332-39, 2013.

PERIODONTOLOGY

Periodontology is a specialty of dentistry that aims to promote the individual's health through prevention, diagnosis and treatment of the diseases that affect the supporting tissues of the teeth and the dental implants. Teeth-supporting tissues include gingiva, periodontal ligament, cementum and alveolar bone. The implant-supporting tissues include the peri-implant mucosa, alveolar bone and basal bone.

The main aim of Periodontology is to preserve the natural dentition and, therefore, masticatory function, phonation and aesthetics. Periodontology also deals with the insertion of dental implants to replace dental elements, which are to be removed or had already been removed.

Periodontal and peri-implant diseases are caused by some specific species of bacteria. Their severity is affected by several local and systemic factors which are conditioned by unhealthy lifestyles. Furthermore, periodontitis is sometimes related to some serious systemic diseases such as cardiovascular and dysmetabolic diseases. In addition, there are some evidencies of a correlation with premature and underweight births (EFP/AAP 2013).

Periodontal diseases include gingivitis and periodontitis, while the diseases that affect peri-implant tissues consist of both peri-implant mucositis and peri-implantitis.

Gingivitis affect the marginal gingiva and, possibly, the attached gingiva; common clinical features are erythema of the gingival margin, edema, bleeding on probing (BOP) and, sometimes, an inflammatory swelling. Gingival volume increase can be caused also by pharmaceutical treatment, or can be due to genetic susceptibility, neoplasms or unknown causes. Gingivitis are reversible but, if untreated, can progress to periodontitis. Implant-supporting tissues can be affected by peri-implant mucositis, a reversible inflammation of the soft tissues without bone loss.

Periodontitis are characterized by the destruction of the periodontal apparatus with loss of both clinical attachment and bone, with subsequent development of pockets and, sometimes, recessions of the gingiva. A characteristic hallmark of periodontitis is the loss of the connective attachments, which is usually irreversible. The American Academy of Periodontology (1999) has classified the Periodontitis into: Aggressive, Chronic, Necrotizing and linked to systemic diseases (Armitage GC 1999, Lang NP, Lindhe J 2016).

Severe Periodontitis is the sixth most prevalent chronic disease of mankind: it affects 10.8% of the world population (743 million people). The prevalence of periodontal diseases in the Italian population is very high (around 60%). The prevalence of aggressive and advanced forms is very high (10-14%) and rises from the age of 35-44 years. (Kassebaum NJ et al 2014, Sheiham A et al 2002)

Clinical studies show that most subjects affected by periodontitis maintain their own teeth for their entire life if an appropriate treatment is performed. When treatment is not completely effective, the disease progression can only be delayed. (Holm-Pedersen P et al 2007)

It is possibile to achieve an effective and efficient prevention of periodontal diseases.

Peri-implant mucositis are defined as inflammatory lesions restricted to the mucosa around an implant and are characterized by bleeding on probing without supporting bone loss (Lindhe et al 2008, Figueiro et al 2014, Heitz-Mayfield LJ 2008)

Peri-implantitis are defined as inflammatory lesions of the peri-implant mucosa involving bone, causing loss of the marginal supporting bone. Peri-implantitis are characterized by probing pocket depth ≥ 5 mm, bleeding on probing, suppuration and bone resorption, which is often evidenced by x-ray analysis.

Both peri-implant mucositis and peri-implantitis are infectious diseases caused by dental biofilm bacteria. (Lang et al 2011)

Although current epidemiologic data are limited and not always homogeneous, it has been reported that peri-implant mucositis is present in 80% of subjects with dental implants and can be observed in 50% of implants. Peri-implant disease affects 28-56% of subjects with dental implants and concerns 12-43% of the implants (Figueiro et al 2014, Lindhe et al 2008)

At the moment, the only treatment available to control the peri-implant tissue infections is the mechanical non-surgical and surgical therapy. This treatment can resolve the infectious-inflammatory clinical picture of the peri-implant mucositis, although the healing time of inflammation of peri-implant tissues is longer if compared to gingivitis. There is a lack of evidence of a complete *restitutio ad integrum* of peri-implant tissues.

Peri-implantitis treatment long-term results need further evaluation (Sanz et al 2015, Tonetti et al 2015).

It is also possible to achieve an effective and efficient prevention for peri-implant diseases.

PERIODONTAL DIAGNOSIS AND TREATEMENT

The periodontal diagnosis and treatment are structured in different steps as reported in the decisional tree (Table 1).

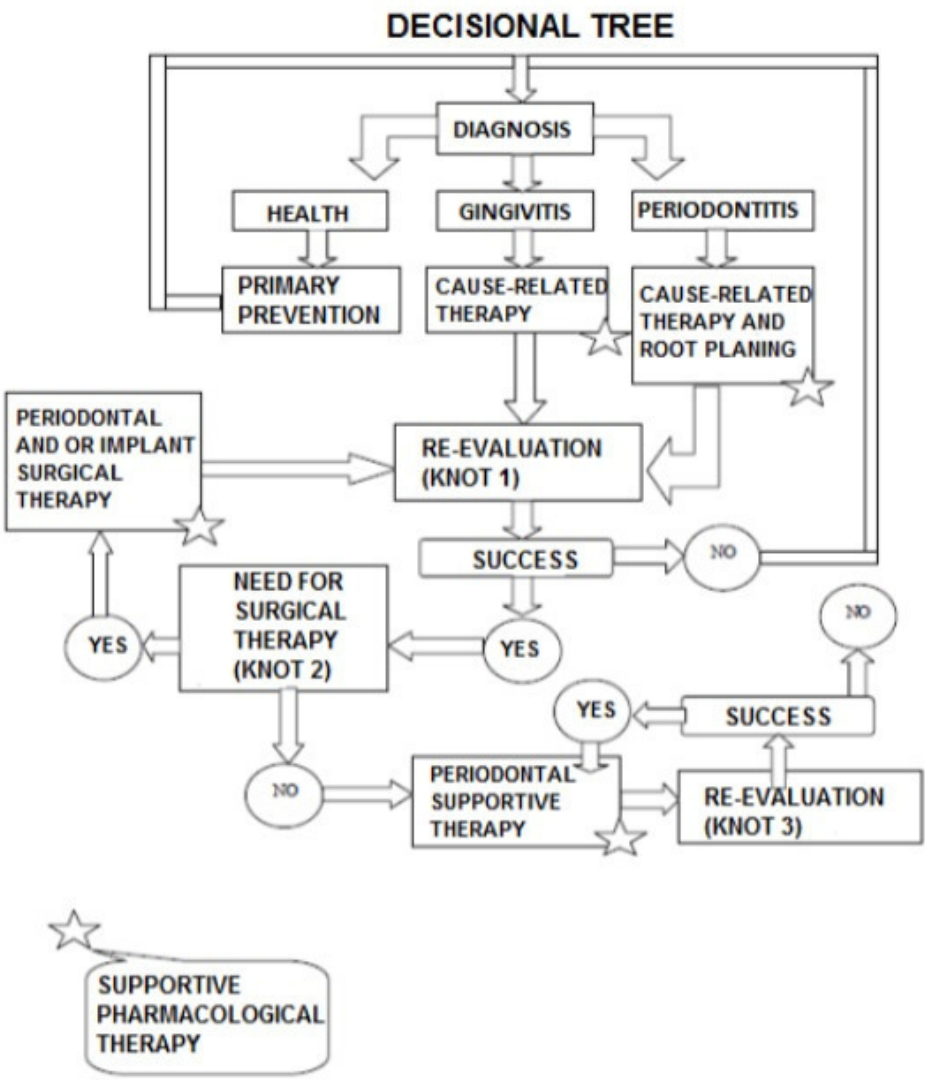

Periodontal diagnosis has to be performed interpreting the information from anamnesis and physical examination, and, if necessary, from radiographic exams and laboratory tests. (Chapple ILC 2009, Paster et al 2009)

The anamnesis aims to detect all the risk factors that may influence the onset and the progression of periodontal or peri-implant diseases: poor oral hygiene, familiarity, tobacco smoke, medications that may increase gingival volume (e.g: nyphedypin, diphenylhdantoin, cyclosporine), diabetes, congenital and non-congenital immune deficiency, some rare systemic diseases (Ehlers' syndrome, Papillon-Lefreve syndrome). (Chrcanovic BR 2015, Genco et al 2013 Jepsen S et al 2015, Knight et al 2016, Labriola et al 2005)

During physical examination, the inspection evaluates: the dental formula and the number of dental elements lost in relation to age; the morphology, volume, colour and consistency of gingiva, mucosa

and the surrounding anatomical structures; the presence of plaque and plaque retaining factors (calculus, caries, rough restorations, dental malpositions); dental migrations.

Any possible dental mobility must be checked. A differential diagnosis of other causes of hypermobility, such as occlusal trauma, endodontic lesions and active orthodontic treatment must be performed. Mobility of implants indicates the complete loss of osseointegration and strongly suggests the removal of the implant itself. **Probing is mandatory for a correct periodontal diagnosis and is the main diagnostic procedure to evaluate the health of the periodontal tissues.** Probing is performed using a periodontal probe, applying a light pressure along the circumference of each dental element between the tooth surface and gingiva. This allows to measure the probing depth of the gingival sulcus and/or periodontal pockets (PD) and the level of clinical attachment (CAL), and to detect furcation involvement, marginal bleeding and/or bleeding on probing (BoP) and the presence of sub-gingival calculus and/or rough or inadequate restorations. (Armitage GC, 2004, Goldenberg et al 2001).

The peri-implant probing should be accomplished before the beginning of the supportive periodontal therapy and possibly performed once a year to allow an early diagnosis of possible peri-implant diseases. The peri implant probing, which should be carried out with a light pressure with the same method used to perform periodontal probing, allows to measure the probing depth of the sulcus and/or detect the presence of peri-implant pockets (PD) and the marginal bleeding and bleeding on probing (BOP). (Abrahamsson I 2006, Graziani F et al 2012)

The peri-implant probing depth may be measured at the time of the insertion of the fixed prosthetics to evaluate changes in the transmucosal path over time. (Lang NP et al 2011)

Every dentist can record the data about periodontal/peri-implant health or disease using the method (complete periodontal charting, PSR or other), and modalities (paper or digital format), which he considers to be the most appropriate.

Periodontitis is a strong risk factor for peri-implantitis.

In order to acquire additional essential information for the diagnosis and, furthermore, in order to develop an appropriate treatment plan, it is necessary to take a periapical x-ray examination of the areas presenting clinical signs of periodontitis or peri-implant diseases. The x-ray examination, always undertaken in conformity with the principle of justification and optimization (ALARA), gives useful elements for the evaluation of the periodontal or peri-implant hard tissues. The evaluation of the peri-

implant support bone level is carried out radiographically at the beginning of the maintenance therapy and, subsequently, when there is a clinical suspicion of peri-implant disease. (ADA 2012, Bragger U 2005, De Bruyn H et al 2013, Eickholz P et al 200 Eickholz P et al 2004, Gomes-Filho IS et al 2007, Graetz C 2014, Harris D et al 2002, Jeffcoat MK et al 1995, Klein et al 2001, Lindhe J et al 2008, Muller HP et al 2005)

Sometimes, in relation to anamnestic data, systemic conditions and periodontal physical examination, blood tests can be useful.
In individuals diagnosed with very severe periodontitis, especially in the aggressive or associated to systemic pathologies forms, microbiological and immunological tests can be considered. In these particular clinical situations, the microbiological tests may be useful to guide the antimicrobial therapy. Culture analysis of the periodontal bacteria is the only microbiological test that allows to construct an antibiogram. The positivity of the test, which is site-specific, is an indicator of an increased risk of disease, although not indicating with certainty the progression of the disease; the absence of the periodontal pathogenic species in the pockets indicates, instead, a stability of the site. The immunological tests (number and functionality of PMN, antibody rate) may be helpful to diagnose and to establish the medical prognosis in individuals with suspected impairment of immune function. The use of these laboratory tests is justified **only** when they can provide further elements useful for the diagnosis and the treatment plan. (Armitage GC 2004, Pérez-Chaparro PJ et al 2016)
A careful anamnestic data-collection with a thorough physical examination, integrated, if necessary, with x-ray examinations and lab tests, allows for the correct evaluation of the periodontal and peri-implant condition of the patient. These evaluations can lead to distinguish:

1. Health
2. Gingivitis
3. Periodontitis
4. Peri-implant mucositis
5. Peri-implant disease

The diagnosis of health condition or periodontal disease must precede and be associated with any kind of dental treatment. (Tonetti et al 2015)

It is necessary to start a prevention program aimed at preserving the status quo when a periodontal health condition is present or has been achieved. (Tonetti et al 2015)

Non-surgical periodontal treatment

The non-surgical periodontal treatment (etiological treatment) includes:

1. The patient's information, instruction and motivation towards personal daily plaque control and the reduction of risk factors of the oral and periodontal pathologies.
2. Mechanical treatment of the dental surface (supra and sub gingival instrumentation).
3. Elimination of retentive plaque factors.

The patient's education includes information about the clinical progression of the periodontal and peri-implant disease, starting from the examination of the oral cavity and explaining the diagnostic methods and therapy protocols. Special attention must be paid to some behavioral habits that may represent potentially modifiable risk factors, such as smoking (antismoking counseling), an unhealthy diet and insufficient physical exercise. The patient must be informed about the importance of the treatment of systemic pathologies, if present, either linked or not to the periodontal disease. The clinician must provide each patient with a behavioral model concerning personal oral hygiene, adequate to his personal necessities and effective for the maintenance of his long-term health condition. (Axelsson P et al 2004, Chambrone et al 2010, Chen et al 2015, Gaunt F et al 2008, Genco Rj et al 2013, Lang NP et al 2005, Martinez-CanutP 2013, Newton et al 2015, Weston et al 2008).

Oral hygiene instructions must concern the appropriate mechanical removal methods of the bacterial plaque from the oral cavity, the use of the toothbrush and interproximal hygiene tools. The mechanical control of the supra gingival plaque can be combined with a chemical control using antiseptics, which might, over time, lead to the onset of side effects. (Sanz et al 2015, Walmsey AD et al 2008)

Chlorhexidine is the most effective anti plaque agent. It is used as an aid to active therapy and when the patient is not able to efficiently perform the mechanical oral hygiene procedures.

The mechanical treatment, aiming to remove bacterial plaque, supra and sub gingival calculus with polishing or scaling and root planing procedures, can be performed with manual tools, ultrasounds and sonics. The effectiveness of these tools has proved to be similar in removing the hard and soft deposits. There can be some side effects such as transitory bacteremia and dental hypersensitivity. (Drisko C.H 2001, Van der Weijden FA et al 2011, Yaacob M et al 2014)

Once the plaque and the calculus have been removed, it is necessary to perform a dental polishing and the finishing of the tooth surfaces.

In presence of supra and sub gingival plaque retentive factors, such as inadequate restarations, rough prosthetic margins and caries, **it is mandatory** to proceed with their elimination in order to allow

correct oral hygiene procedure and restore a suitable dental-gingival anatomy for an effective plaque control.

The expected results from the non-surgical periodontal treatment include the improvement of the patient's collaboration and motivation level, a significant and stable reduction of the bacterial plaque and calculus present on the dental surfaces (ideally under 20%), the elimination or reduction of clinical signs of marginal inflammation (erythema, edema and bleeding), the reduction of bleeding on probing -BOP- (ideally under 20%), the reduction of the probing depth -PD-, a gain of clinical attachment level -CAL- and the recession of the marginal tissue -REC. (Beirne P et al 2008)

Several mechanical non-surgical treatment protocols (etiological treatment) can be adopted, but again, it is necessary to provide, **possibly in the same appointment**, the removal of the etiological factors, both supra and sub gingival, **in the treated area**. Considering the patient's conditions, the non-surgical etiological therapy can be administered with a variable number of appointments, planned in the shortest time possible in order to avoid a re-infection of the treated sites due to the bacteria present in the yet untreated sites. Alternatively, when indicated, the clinician can program the so-called "Full Mouth Disinfection" in one or two sessions within a period of 24/48h. (Cosyn J et al 2006, Drisko C.H 2001, Eberhard J et al 2008, Eberhard et al 2015, Lang NP et al 2008)

There currently is no evidence that proves significant differences between scaling and root planing via ultrasonic tools and cleansing procedures using pressurized air and abrasive powder (air polishing). (Wennstrom J et al 2011)

There currently is no scientific evidence that proves that the employment of laser as an aid to the traditional non-surgical treatment (scaling and root planing) brings any clinically significant advantages compared to the traditional procedures performed singularly. (Mizutani et al 2016, Romanis et al 2015, Slot DE et al 2014, Zhao Y et al 2014)
The current scientific evidence proves only some modest changes in the clinical parameters achieved with photodynamic treatment in addition to conventional procedures of non-surgical therapy, evaluated in the short-term. At present, there is no evidence to sustain the efficacy of these procedures at medium and long term. (Chatzopolous DF & Aikaterini-Ellisavet 2016, Gatti C et al 2016, Heitz-Mayfiled LJ et al 2013, Mizutani et al 2016, Sgolastra F et al 2013)

The majority of the patients affected by gingivitis and periodontitis can be successfully treated achieving a stable condition of health using non-surgical procedures and an effective supportive therapy.

The patient's periodontal re-evaluation is always necessary after the etiological treatment,.

The patient's re-evaluation confirms the therapeutic success or failure. Markers of therapeutic success are the reduction of the amount of the bacterial plaque to the theoretical limit zero (FMPS over 20% cannot be accepted), the reduction of bleeding on probing to the theoretical limit zero (FMBS over 20% cannot be accepted) and the reduction of the probing depth.
The reduction of the probing depth, following a non-surgical treatment, mostly depends on the initial pocket depth (the probing depth must not be over 4 mm). (Beltràn-Aguilar E.D et al 2012)
The patient reaching these targets and, therefore, not in need of a surgical treatment, will be included in a periodontal supportive therapy program to maintain the achieved results; the patient will be constantly motivated to adopt an healthy lifestyle. Periodontal supportive therapy consists of scheduled sessions of periodontal and peri-implant professional hygiene, completed, if necessary, by a new collection of clinical data and an additional phase of active therapy. The regularity of the periodontal supportive therapy appointments must be stated taking into consideration the risk factors and the patient's plaque control ability, at the moment of the final re-evaluation, after the conclusion of the active treatment and during the following revaluations. (Armitage GC, Xenoudi P. 2016, Verdugo et al 2016)

If the expected results are not completely achieved, the etiological and the non-surgical mechanical treatment should be fully or partially repeated.

The need for a surgical treatment must be evaluated considering the following parameters: the presence of pockets with probing depth equal or greater than 5 mm; the alteration of the gingival and bone architecture; the presence of class II and III furcation involvement; the necessity to rebuild or regenerate the periodontal support; the necessity to modify the gingival position and/or volume; the presence of hopeless dental elements that require an implant-prosthetic treatment. (Matuliene G et al 2008, Papapanou et al 2000)

The clinician will choose the appropriate surgical technique taking into account the indications and the expected results of the different procedures in relation to his/her skill and experience.
Any kind of periodontal surgical treatment implies that the patient is motivated to maintain an adequate plaque control (plaque and bleeding score not more than 20%), and that general health conditions do not represent a controindication to the surgical procedure. The surgical treatment must be considered as an additional means to the non-surgical mechanical treatment (etiological therapy). The various

surgical techniques must be evaluated according to their efficacy in reducing deep pockets and in improving the conditions that enhance plaque accumulation, such as alterations of the gingival and bone architecture or furcation involvement. The clinician must consider that the pockets with a probing depth equal or greater than 5 mm have a risk of recurrence 12 times greater than sites with a probing depth equal or less than 4 mm; a pocket with a probing depth greater than 5 mm is a risk factor of tooth loss 8 times greater if compared to a site with a probing equal or less than 3mm; class II and III furcation involvement represents a risk factor for tooth loss up to 14 times greater if compared to teeth without furcation involvement.
(Cattabriga M et al 2000, Dannewitz B et al 2009, Dead DE et al 2016, Graetz C et al 2015, Heitz-Mayfiled LJ 2002, Huynh-Ba G et al 2009, Nibali et al 2016)

The main aim of surgical treatment is to riduce the risk of periodontal disease recurrence, thus restoring a gingival, bone and dental morphology that improves an effective dental hygiene at home.

Other aims of the periodontal surgical treatment are the increase of the periodontal support and/or, when possible, the reduction of aesthetically poor outcomes caused by the recession of tissues.

The surgical procedures suitable for the modification of the gingival/bone/dental anatomy are:

the access flap: it is an additional means to the etiological non-surgical therapy and the first surgical treatment that can be recommended in case of pockets with probing depth equal or greater than 5 mm, with or without positive BOP, still present at the end of the etiological therapy. This surgical procedure facilitates the access to radicular surface for an accurate sub gingival calculus removal, changing the microbiological environment of the treated sites. Scientific evidence shows that, in presence of pockets with probing depth of _> 5 mm, with or without positive BOP, there is a greater risk of disease progression. (Graziani F et al 2012, Graziani F et al 2015)

The expected results of the access flap procedure are: the reduction or the absence of bleeding on probing, the reduction of probing depth, the gain of clinical attachment and the recession of the marginal tissue.

The **resective surgery** (gingival, bone and radicular surgery) has to be considered as a treatment for the elimination of the pocket and a reshaping of the gingival, bone and dental morphology in order to promote an easy and effective bacterial plaque control. It is indicated particularly for the treatment of the gingival and bone enlargement, of _< 3mm infrabony defects and class II and III furcation involvement. Bone resective surgery can be used to restore the biological width and to allow the correct execution of conservative and prosthetic restorations. (Cairo F et al 2013, Cairo F et al 2015, Carnevale G. Et al 2000, Carnevale G. 2007, Carnevale G. Et al 2007)

The expected results of the resective surgery procedures are: the absence of bleeding on probing, a probing depth _< 3 mm, a clinical crown lenghtening and the marginal tissue's stability after complete tissue healing.

The regenerative bone surgery allows to regenerate the supporting tissue around the dental elements that are seriously compromised by the periodontal disease. The most reliable and effective procedures are the guided tissue regeneration (GTR) with the application of a physical barrier (tissue regeneration by means of membranes) and the biologically induced regeneration through amelogenins (ITR). It is possible to obtain a gain of the supporting tissues even using intermediate autografts or biomaterial gratfs. (Trombelli L et al 2008)

Regenerative surgical procedures can provide predictable clinical results in deep intraosseous defects (≥ 3 mm) with a tissue morphology suitable to the regeneration of the periodontal tissues.

The expected results of the regenerative therapy include the reduction of the probing depth, the gain of the clinical attachment level and a limited recession of the marginal tissue. (Cortellini P et al 2008, Cortellini P et al 2009, Cortellini et al 2015 Pagliaro U et al 2008)

the **muco-gingival surgery** includes the procedures aimed to correct the morphological defects by improving the position and/or quantity of the periodontal soft tissues. These defects can be treated with flap procedures or with tissue grafts, eventually using biomaterials. The main indications are the coverage of the exposed radicular surface or the increase of the width, height and thickness of the gingival tissue for functional, aesthetic, prosthetic requirements. (Cairo F et al 2008, Zucchelli G et al 2009)

The expected results of the mucogingival surgical procedures include the clinical attachment gain (root coverage), the elimination or reduction of the marginal tissue recessions (root coverage) and the increase of the height and thickness of the keratinized tissue. (Chambrone L et 2012)

PERI-IMPLANTITIS

Contrary to the patients' expectations, implants may encounter some biological complications, such as mucositits and peri-implant diseases. These conditions are determined by bacterial biofilm on the implant surface, which, if not removed, may cause the inflammation of the peri-implant tissues. (Abrahamsson KH et al 2016, Atieh MA et al 2013, CAnullo L et al 2015, Duarte PM et al 2016, Lang NP et al 2016, Pérez-Chaparro PJ et al 2016, Rakic M et al 2016, Renvert et al 2011, Sarmiento HL et al 2016)

Initially, the inflammation can affect the superficial gingival tissues, causing bleeding on probing (mucositis), but successively it can deepen, determining a probing depth increase and the resorption of the peri-implant bone (peri-implantitis).

The early diagnosis of the mucositis is essential because, at this stage, an appropriate therapy can prevent the progression of the infection to peri-implantitis, even if, in comparison to gingivitis, the time for the resolution of the inflammation is longer. However, there is a lack of scientific evidence that proves the complete *restitutio ad integrum* of the peri-implant tissues. (Derks J et al 2015, Derks J et al 2016, Figuero et al 2014, Jepsen S et al 2015, Salvi GE et al 2015, Sarmiento HL et al 2016, Tarnow DP 2016)

An untreated periodontitis, smoking, non-controlled systemic diseases (e.g. diabetes), inadequate prosthetics not allowing an effective plaque control and the patient's failed compliance to suggested oral hygiene and maintenance program increase the risk of peri-implantitis. (Brito et al 2014, Chambrone et al 2010, Chapple IL et al 2013, Chrcanovic BR et al 2014, de Brandão ML et al 2014, Gurgel et al 2016, Heitz-Mayfield LJ 2009, Karoussis IK et al 2003, Lin et al 2013, Marcantonio C et al 2015, Mombelli et al 2012, Monje et al 2014, Monje A et al 2016 , Renvert et al 2013, Renvert et al 2015, Rokn A et al 2016, Salvi GE et al 2014, Salvi GE et al 2015, Sgolastra F et al 2015,Simpson TC et al 2015, Sousa V et al 2016, Tonetti et al 2015, Turri et al 2016, Verdugo F et al 2016, Zangrando MS et al 2016)

The early identification and control of these risk factors **before the implant insertion** and the inclusion of the patient in an adequate SPC protocol can be very effective in reducing the incidence of these diseases. (Monje et al 2014, Monje A, et al 2016, Renvert et al 2015, Tonetti et al 2015, Zangrando MS et al 2016)

The treatment of the peri-implant disease consists of the removal of the bacterial biofilm, the reduction of the probing depth and, where necessary and possible, the correction of the associated bone defects. This kind of treatment must be carried out as early as possible, with the aim of stopping the progressive bone loss.

The non-surgical treatment, performed with various protocols and integrated with pharmacological therapies, is effective in eliminating the inflammation (bleeding on probing) in case of peri-implant mucositis, even with long healing time, while, in case of peri-implant disease, is it characterized by non-predictable results. (Carcuac O et al 2016, Faggion CM Jr, et al 2014, Figuero et al 2014, Heitz-Mayfield LJ et al 2014, Heitz-Mayfield LJ et al 2016, Hultin M et al 2007, Hur et al 2016, Kotsakis L et al 2014, Monje A et al 2016, Muthukuru M et al 2012, Natto et al 2015, Quirynen M, et al 2007, Renvert et al 2013, Romanos et al 2012, Romanos et al 2014, Romanos et al 2015, Roos-Jansåker Amet al 2015, Salvi GE et al 2012, Salvi GE et al 2014, Salvi GE et al 2015, Schwarz F et al 2015, van Winkelhoff AJ 2012, Verdugo Fet al 2016)

Several surgical protocols have been suggested; they all involve access flaps followed by mechanical or chemical procedures involving the removal of the asperities of the implant surfaces to reduce bacterial contamination. (Esposito et al 2012, Figuero et al 2014, Froum et al 2016, Renvert et al 2012 Romanos et al 2015)

Many surgical regenerative or resective procedures performed to correct the anatomy of the peri-implant bone defects by stopping or delaying, if possible, the peri-implant's progression have been reported. (Chan et al 2014, de Waal YC et al 2015, Khoshkam Vet al 2016, Ramanauskaite A et al 2016)

There is no conclusive evidence of the efficacy and of the cost/effectiveness ratio of these procedures. (Esposito et al 2012, Graziani et al 2012, Heitz-Mayfield LJ et al 2014, Papathanasiou E et al 2016, Schwarz F et al 2012, Schwendicke F et al 2015)

There currently is no conclusive scientific evidence proving that the use of laser as an aid to the surgical and non-surgical treatment of the peri-implant disease brings long term clinically significant advantages compared to the traditional procedures performed alone. (Mizutani et al 2016)

In selected cases of peri-implant diseases, the removal of failing implants can be considered. (Stajčić Z et al 2016)

REVALUATION

At the end of the surgical treatment, a further evaluation of the patient is necessary to assess the expected outcomes.

When the desired targets are achieved, the patient must be included in a supporting periodontal program. The patient will have to be periodically evaluated to confirm the stability of the result achieved with the treatment. The presence of clinical signs of recurrence of periodontal and/or peri-implant diseases (lack of stability of the results achieved with the active treatment) requires a new diagnostic evaluation and possible further treatment. The supporting therapy is an essential part of the periodontal and peri-implant treatment. Its main aim is to control over time plaque accumulation, in order to prevent potential recurrencies. (Armitage G et al 2016, Roldan S et al 2015)

The absence of clinical signs linked to periodontal and peri-implant diseases is the essential criterion for the inclusion and maintenance of a patient in a supporting periodontal and peri-implant program.

The diagnostic procedures consist in the detection of the presence of bacterial plaque, the presence of new risk factors linked to the patient and the clinical signs associated to periodontal diseases.

The therapeutic procedures are essentially based on the bacterial plaque and supra and sub gingival calculus removal and, when necessary, on the modification of the patient's oral hygiene behavior (instruction and motivation; scaling and root planing; etiological treatment).

The recurrence of clinical signs associated to gingivitis and periodontitis indicates the necessity of further active treatments of periodontal therapy (scaling and root planing; etiologic treatment; periodontal surgical treatment).

Patients must be empowered and motivated to receive personalized SPC treatments and to accept periodic follow up examinations.

This protocol allows those who follow it to maintain the health condition achieved with the active therapy for a longer time than those who do not. (Axelsson P1, Nyström B, Lindhe J 2004.; Lang NP, Lindhe J, van der Velden 2005)

A periodic follow up is important for patients with implant-prothesic rehabilitations. Early diagnosis is of great importance since peri-implant diseases cannot be easily solved. The radiographic evaluation of the peri-implant bone support level must be carried out firstly at the beginning of the treatment and later if a peri-implant disease is suspected. (Armitage G et al 2016)

Antimicrobial therapy

The medical therapy of periodontal disease uses antiseptics drugs and antibiotics.

The systemic anti microbical therapy implies the use of antibiotics. The aim is to reduce the amount of the periodontal pathogens in case of periodontal abscess, aggressive periodontitis, mechanical treatment refractory periodontitis, necrotizing periodontitis and peri-implantitis. Except in case of acute

infections, the antibiotics must not be administered without a previous mechanical treatment and in absence of the patient's optimal plaque control. There are several therapeutic protocols, mono-therapeutic or in association, suggested in different studies for various clinical situations: tetracyclines, metronidazole, ciprofloxacin, amoxicillin + clavulanic acid, clindamycin, metronidazole + amoxicillin (it is considered to be the most effective clinical pharmaceutical association for aggressive periodontitis), metronidazole + ciprofloxacin (ciprofloxacin can substitute amoxicillin in case of allergy to b-lattamine).

The expected results of the pharmacological antibiotic treatment are the reduction of the probing depth and the bleeding on probing at medium-term.

During the different therapeutic treatment steps of periodontal diseases, the use of drugs may be necessary; they are administered systemically or locally, as a support or integration of the mechanical therapy.

The continuous emergence of antibiotic-resistant bacterial species requires a limited use of systemic antibiotics in periodontal treatments. The topical anti-microbical therapy is based on the use of antibiotics and antiseptics with the aim of reducing the pathogen microflora in localized sites that do not respond to mechanical treatment both in peri-implant and periodontal diseases. It implies the topic application of anti-microbical medications, such as: metronidazole, doxicillin HCI, minocycline, piperacillin and chlorhexidine.(Cazzaniga A et al 2008, Cosgarea R et al 2016, Herrera D et al 2008, Herrera D et al 2012, Keestra et al 2015, Rabelo CC et al. 2015, Sgolastra et al 2012, Sgolastra et al 2013, Zandbergen et al 2013)

The anti-bacterial agents must be considered as an aid to conventional therapy and are not meant to replace the conventional mechanical treatment.

Bibliography

Abrahamsson I, Soldini C. Probe penetration in periodontal and peri-implant tissues: an experimental study in the beagle dog.
Clin. Oral Impl. Res. 17, 2006; 601–605

Abrahamsson KH, Wennström JL, Berglundh T, Abrahamsson I. Altered expectationson dental implant therapy; views of patients referred for treatment of peri-implantitis. Clin Oral Implants Res. 2016 Feb 25. doi: 10.1111/clr.12817.[Epub ahead of print] PubMed PMID: 26918305.

American Dental Association Dental radiographic examinations: recommendations for patient selection and limiting radiation exposure 2012

Armitage GC. Development of a Classification System for Periodontal Diseases and Conditions Ann Periodontol 1999;4:1-6.

Armitage GC, Xenoudi P. Post-treatment supportive care for the natural dentition and dental implants. Periodontol 2000. 2016 Jun;71(1):164-84.

Armitage GC. The complete periodontal examination. Periodontology 2000, 34:22-33,2004.

Atieh MA, Alsabeeha NH, Faggion CM Jr, Duncan WJ. The frequency of peri-implant diseases: a systematic review and meta-analysis. J Periodontol. 2013 Nov;84(11):1586-98. doi: 10.1902/jop.2012.120592. Epub 2012 Dec 13. Review.PubMed PMID: 23237585.

Axelsson P, Nyström B, Lindhe J. The long-term effect of a plaque control program on tooth mortality, caries and periodontal disease in adults. Results after 30 years of maintenance. J Clin Periodontol. 2004 Sep;31(9):749-57.

Beirne P, Clarkson JE, Worthington HV. Recall intervals for oral health in primary care patients (Review) The Cochrane Collaboration. Published by JohnWiley & Sons, Ltd. 2008

Beltrań N-Aguilar E.D., Eke P.I. , Thornton-Evans G., Petersen P.E. Recording and surveillance systems for periodontal diseases, Periodontology 2000, Vol. 60, 2012, 40–53

Blieden TM, Caton JG, Proskin HM, Stein SH, Wagener CJ. Examiner reliability for an invasive gingival bleeding index. J Clin Periodontol. 1992 Apr;19(4):262-7.

Bragger U Radiographic parameters:biological significance and clinical use Periodontology 2000, Vol. 39, 2005, 73–90

Brito C, Tenenbaum HC, Wong BK, Schmitt C, Nogueira-Filho G. Is keratinized mucosa indispensable to maintain peri-implant health? A systematic review of the literature. J Biomed Mater Res B Appl Biomater. 2014 Apr;102(3):643-50. doi:10.1002/jbm.b.33042. Epub 2013 Oct 7. Review. PubMed PMID: 24124021.

Cairo F, Carnevale G, Buti J, Nieri M, Mervelt J, Tonelli P, Pagavino G, Tonetti M. Soft-tissue re-growth following fibre retention osseous resective surgery or osseous resective surgery: a multilevel analysis. J Clin Periodontol. 2015 Apr;42(4):373-9

Cairo F, Carnevale G, Nieri M, Mervelt J, Cincinelli S, Martinolli C, Pini-Prato GP, Tonetti MS. Benefits of fibre retention osseous resective surgery in the treatment of shallow infrabony defects: a double-blind, randomized, clinical trial describing clinical, radiographic and patient-reported outcomes. J Clin Periodontol. 2013 Feb;40(2):163-71

Cairo F, Pagliaro U, Nieri M. Treatment of gingival recession with coronally advanced flap procedures: a systematic review. J Clin Periodontol. 2008 Sep;35(8 Suppl):136-62.

Canullo L, Schlee M, Wagner W, Covani U; Montegrotto Group for the Study of Peri-implant Disease. International Brainstorming Meeting on Etiologic and Risk Factors of Peri-implantitis, Montegrotto (Padua, Italy), August 2014. Int J Oral Maxillofac Implants. 2015 Sep-Oct;30(5):1093-104. doi: 10.11607/jomi.4386. PubMed PMID: 26394346.

Carcuac O, Derks J, Charalampakis G, Abrahamsson I, Wennström J, Berglundh T. Adjunctive Systemic and Local Antimicrobial Therapy in the Surgical Treatment of Peri-implantitis: A Randomized Controlled Clinical Trial. J Dent Res. 2016 Jan;95(1):50-7. doi: 10.1177/0022034515601961. Epub 2015 Aug 18. PubMed PMID:26285807.

Carnevale G, Cairo F, Nieri M, Tonetti MS. Fibre retention osseous resective surgery: how deep is the infrabony component of the osseous-resected defects? J Clin Periodontol. 2008 Feb;35(2):133-8

Carnevale G, Cairo F, Tonetti MS. Long-term effects of supportive therapy in periodontal patients treated with fibre retention osseous resective surgery. I: recurrence of pockets, bleeding on probing and tooth loss. J Clin Periodontol. 2007 Apr;34(4):334-41.

Carnevale G, Cairo F, Tonetti MS.Long-term effects of supportive therapy in periodontal patients treated with fibre retention osseous resective surgery. II: tooth extractions during active and supportive therapy. J Clin Periodontol. 2007 Apr;34(4):342-8.

Carnevale G. & Kaldahl W.B., Osseous resective surgery, Periodontology 2000, Vol. 22, 2000, 59–87

Carnevale G.Fibre retention osseous resective surgery: a novel conservative approach for pocket elimination. J Clin Periodontol. 2007 Feb;34(2):182-7

Cattabriga M, Pedrazzoli V, Wilson TG Jr. The conservative approach in the treatment of furcation lesions. Periodontol 2000. 2000 Feb;22:133-53.

Cazzaniga A, Galli C, Fiorini A, Cantini E, Lodi G. Systemic antibiotics as adjunctive treatment for chronic periodontitis (Protocol) The Cochrane Library 2008, Issue 2

Chambrone L, Chambrone D, Lima LA, Chambrone LA.Predictors of tooth loss during long-term periodontal maintenance: a systematic review of observational studies. J Clin Periodontol. 2010 Jul;37(7):675-84.

Chambrone L, Chambrone LA, Lima LA. Effects of occlusal overload on peri-implant tissue health: a systematic review of animal-model studies. J Periodontol. 2010 Oct;81(10):1367-78.

Chambrone L., Mendes Pannuti C., Tu Y.K. and Chambrone L.A. Evidence-Based Periodontal Plastic Surgery. II. An Individual Data Meta-Analysis for Evaluating Factors in Achieving Complete Root Coverage. J Periodontol 2012;83:477-490.

Chan HL, Lin GH, Suarez F, MacEachern M, Wang HL. Surgical management of peri-implantitis: a systematic review and meta-analysis of treatment outcomes. J Periodontol. 2014 Aug;85(8):1027-41. doi: 10.1902/jop.2013.130563. Epub 2013 Nov 21. Review. PubMed PMID: 24261909.

Chapple IL, Genco R; working group 2 of the joint EFP/AAP workshop. J Periodontol. 2013 Apr;84(4 Suppl):S106-12. Diabetes and periodontal diseases: consensus report of the Joint EFP/AAP Workshop on Periodontitis and Systemic Diseases.

Chapple ILC. Periodontal diagnosis and treatment – where does the future lie? Periodontology 2000. 2009;51:9-24.

Chatzopoulos DF & Aikaterini-Ellisavet Doufexi Photodynamic therapy in the treatment of aggressive periodontitis: A systematic review.Med Oral Patol Oral Cir Bucal. 2016 Mar 1;21(2):e192-200.

Chen PC Tung YC,Wu PW, WuLS, Lin YS, Chang CJ, Kung S, Chu PH Dental Procedures and the Risk of Infective Endocarditis, Medicine October 2015 Volume 94, Number 43,

Chrcanovic BR, Albrektsson T, Wennerberg A. Periodontally compromised vs. periodontally healthy patients and dental implants: a systematic review and meta-analysis. J Dent. 2014 Dec;42(12):1509-27. doi: 10.1016/j.jdent.2014.09.013. Epub 2014 Oct 2. PubMed PMID: 25283479.

Chrcanovic BR. A History of Periodontitis Suggests a Higher Risk for Implant Loss. J Evid Based Dent Pract. 2015 Dec;15(4):185-6. doi:10.1016/j.jebdp.2015.10.003. Epub 2015 Oct 24. PubMed PMID: 26698005.

Claffey N, Clarke E, Polyzois I, Renvert S. Surgical treatmentof peri-implantitis. J Clin Periodontol 2008: 35: 316–332.

Cortellini P et al Clinical concepts for regenerative therapy in intrabony defects Periodontology 2000, Vol. 68, 2015, 282–307

Cortellini P, Nieri M, Prato GP, Tonetti MS. Single minimally invasive surgical technique with an enamel matrix derivative to treat multiple adjacent intra-bony defects: clinical outcomes and patient morbidity. J Clin Periodontol. 2008 Jul;35(7):605-13.

Cortellini P, Tonetti M, Baldi C, Francetti L, Rasperini G, Rotundo R, Nieri M, Franceschi D, Labriola A, Prato GP. Does placement of a connective tissue graft improve the outcomes of coronally advanced flap for coverage of single gingival recessions in upper anterior teeth? A multi-centre, randomized, double-blind, clinical trial. J Clin Periodontol. 2009 Jan;36(1):68-79.

Cosgarea R, Juncar R, Heumann C, Tristiu R, Lascu L, Arweiler N, Stavropoulos A, Sculean A. Non-surgical periodontal treatment in conjunction with 3 or 7 days systemic administration of amoxicillin and metronidazole in severe chronic periodontitis patients. A placebo-controlled randomized clinical study. J Clin Periodontol. 2016 Sep;43(9):767-77.

Cosyn J, Wyn I. A systematic review on the effects of the chlorhexidine chip when used as an adjunct to scaling and root planing in the treatment of chronic periodontitis. J Periodontol. 2006 Feb;77(2):257-64.

Dannewitz B, Lippert K, Lang NP, Tonetti MS, Eickholz P. Supportive periodontal therapy of furcation sites: non-surgical instrumentation with or without topical doxycycline. J Clin Periodontol. 2009 Jun;36(6):514-22.

de Brandão ML, Vettore MV, Vidigal Júnior GM. Peri-implant bone loss in cement- and screw-retained prostheses: systematic review and meta-analysis. J Clin Periodontol. 2013 Mar;40(3):287-95. doi: 10.1111/jcpe.12041. Epub 2013 Jan 9. Review. PubMed PMID: 23297703.

De Bruyn H, Vandeweghe S, Ruyffelaert , Cosyn J, Sennerby L. Radiographic evaluation of modern oral implants with emphasis on crestal bone level and relevance to peri-implant health Periodontology 2000, Vol. 62, 2013, 256–270

de Waal YC, Raghoebar GM, Meijer HJ, Winkel EG, van Winkelhoff AJ. Prognostic indicators for surgical peri-implantitis treatment. Clin Oral Implants Res. 2015 Mar 29. doi: 10.1111/clr.12584. [Epub ahead of print] PubMed PMID: 25818042.

Deas DE, Moritz AJ, Sagun RS Jr, Gruwell SF, Powell CA. Scaling and root planing vs. conservative surgery in the treatment of chronic periodontitis.Periodontol 2000. 2016 Jun;71(1):128-39.

Derks J, Schaller D, Håkansson J, Wennström JL, Tomasi C, Berglundh T. Peri-implantitis - onset and pattern of progression. J Clin Periodontol. 2016 Apr;43(4):383-8. doi: 10.1111/jcpe.12535. Epub 2016 Mar 29. PubMed PMID:26900869.

Derks J, Schaller D, Håkansson J, Wennström JL, Tomasi C, Berglundh T. Effectiveness of Implant Therapy Analyzed in a Swedish Population: Prevalence of Peri-implantitis. J Dent Res. 2016 Jan;95(1):43-9. doi: 10.1177/0022034515608832.PubMed PMID: 26701919.

Derks J, Tomasi C. Peri-implant health and disease. A systematic review of current epidemiology. J Clin Periodontol. 2015 Apr;42 Suppl 16:S158-71. doi:10.1111/jcpe.12334. Review. PubMed PMID: 25495683.

Drisko C.H., Non surgical periodontal therapy, Periodontology 2000, 2001 25: 77-88,

Duarte PM, Serrão CR, Miranda TS, Zanatta LC, Bastos MF, Faveri M, Figueiredo LC, Feres M. Could cytokine levels in the peri-implant crevicular fluid be used to distinguish between healthy implants and implants with peri-implantitis? A systematic review. J Periodontal Res. 2016 Jan 16. doi: 10.1111/jre.12354. [Epub ahead of print] Review. PubMed PMID: 26774043.

Dzink JL, Socransky SS, Haffajee AD. The predominant cultivable microbiota of active and inactive lesions of destructive periodontal diseases. J Clin Periodont 1988; 15: 316-323.

Eberhard J, JervØe-Storm PM, Needleman I, Worthington H, Jepsen S. Full-mouth treatment concepts for chronic periodontitis: a systematic review. J Clin Periodontol. 2008 Jul;35(7):591-604.

Eberhard J1, Jepsen S, Jervøe-Storm PM, Needleman I, Worthington HV. Full-mouth treatment modalities (within 24 hours) for chronic periodontitis in adults. Cochrane Database Syst Rev. 2015 Apr 17;(4):CD004622. doi: 10.1002/14651858.CD004622.pub3.

EFP and AAP. Periodontitis and Systemic Diseases - Proceedings of a workshop jointly held by the European Federation of Periodontology and American Academy of Periodontology J Clin Periodontol. 2013 Volume 40, Issue Supplement s14 Pages S1–S214

Eickholz P, Hausmann E. Accuracy of radiographic assessment of interproximal bone loss in intrabony defects using linear measurements. Eur J Oral Sci 2000; 108: 70±73.

Eickholz P, Horr T, Klein F, Hassfeld S, Kim TS. Radiographic parameters for prognosis of periodontal healing of infrabony defects: two different definitions of defect depth. J Periodontol. 2004 Mar;75(3):399-407.

Esposito M, Grusovin MG, Worthington HV. Interventions for replacing missing teeth: treatment of peri-implantitis. Cochrane Database Syst Rev. 2012 Jan18;1:CD004970. doi: 10.1002/14651858.CD004970.pub5. Review. PubMed PMID:22258958.

Esposito M, Grusovin MG, Worthington HV. Treatment of peri-implantitis: what interventions are effective? A Cochrane systematic review. Eur J Oral Implantol. 2012;5 Suppl:S21-41. Review. PubMed PMID: 22834392.

Faggion CM Jr, Listl S, Frühauf N, Chang HJ, Tu YK. A systematic review and Bayesian network meta-analysis of randomized clinical trials on non-surgical treatments for peri-implantitis. J Clin Periodontol. 2014 Oct;41(10):1015-25. doi: 10.1111/jcpe.12292. Epub 2014 Aug 11. Review. PubMed PMID: 25039292.

Figuero E, Graziani F, Sanz I, Herrera D, Sanz M. Management of peri-implant mucositis and peri-implantitis. Periodontol 2000. 2014 Oct;66(1):255-73. doi: 10.1111/prd.12049. Review. PubMed PMID: 25123773.

Froum SJ, Dagba AS, Shi Y, Perez-Asenjo A, Rosen PS, Wang WC. Successful Surgical Protocols in the Treatment of Peri-Implantitis: A Narrative Review of the Literature. Implant Dent. 2016 Jun;25(3):416-26.

Gatti C, Aimetti M, Rasperini G, Landi L, Cairo F, on behalf of SIdP Italian Society of Periodontology and Implantology. RE: Long-term efficacy of microbiology-driven periodontal laser-assisted therapy, by Martelli et al., EJCMID 2016, 35(3): 423-31. Eur J Clin Micorbiol Infect Dis. 2016 Oct13. [Epub ahead of print].

Gaunt F, Devine M, Pennington M, Vernazza C, Gwynnett E, Steen N, Heasman P. The cost-effectiveness of supportive periodontal care for patients with chronic periodontitis. J Clin Periodontol 2008; 35 (Suppl. 8): 67–82.

Genco RJ, Borgnakke WS Risk factors for periodontal disease Periodontology 2000, Vol. 62, 2013, 59–94

Goldberg PV, Higginbottom FL, Wilson TG Periodontal considerations in restorative and implant therapy. Periodontol 2000. 2001;25:100-9.

Gomes-Filho IS, Sarmento VA, de Castro MS, da Costa NP, da Cruz SS, Trindade SC, de Freitas CO, de Santana Passos J. Radiographic features of periodontal bone defects: evaluation of digitized images. Dentomaxillofac Radiol. 2007 Jul;36(5):256-62.

Graetz C, Plaumann A, Wiebe FJ, Springer, Salzer S, Dorfer CE Periodontal Probing Versus Radiographs for the diagnosis of Furcation Involvement J Periodontol 2014;85:1371-1379

Graetz C., Schutzhold S., Plaumann A.,Kahl M., Springer C.,Salzer S., Holtfreter B.,Kocher T., Dorfer C.E. and Schwendicke F. Prognostic factors for the loss of molars – an 18-years retrospective cohort study. J Clin Periodontol 2015; 42: 943–95.

Graziani F, Figuero E, Herrera D. Systematic review of quality of reporting, outcome measurements and methods to study efficacy of preventive and therapeutic approaches to peri-implant diseases. J Clin Periodontol. 2012 Feb;39 Suppl 12:224-44. doi: 10.1111/j.1600-051X.2011.01832.x. Review. PubMed PMID: 22533959.

Graziani F, Gennai S, Cei S, Cairo F, Baggiani A, Miccoli M, Gabriele M, Tonetti M. Clinical performance of access flap surgery in the treatment of the intrabony defect. A systematic review and meta-analysis of randomized clinical trials. J Clin Periodontol 2012; 39: 145–156.

Graziani F, Gennai S, Karapetsa D, Rosini S, Filice N, Gabriele M, Tonetti M. Clinical performance of access flap in the treatment of class II furcation defects. A systematic review and meta-analysis of randomized clinical trials. J Clin Periodontol. 2015 Feb;42(2):169-81

Gurgel BC, Montenegro SC, Dantas PM, Pascoal AL, Lima KC, Calderon PD.Frequency of peri-implant diseases and associated factors. Clin Oral Implants Res. 2016 Aug 24. doi: 10.1111/clr.12944. [Epub ahead of print] PubMed PMID:27557997.

Harris D, Buser D, Dula K, Gröndahl K, Harris D, Jacobs R, Lekholm U, Nakielny R, van Steenberghe D, van der Stelt P . E.A.O. Guidelines for the use of Diagnostic Imaging in Implant Dentistry Clin. Oral Impl. Res, ***13****, 2002; 566–570*

Heitz-Mayfield LJ, Huynh-Ba G. History of treated periodontitis and smoking as risks for implant therapy. Int J Oral Maxillofac Implants. 2009;24Suppl:39-68. Review. PubMed PMID: 19885434.

Heitz-Mayfield LJ, Lang NP Surgical and nonsurgical periodontal therapy. Learned and unlearned concepts Periodontology 2000, Vol. 62, 2013, 218–231

Heitz-Mayfield LJ, Mombelli A. The therapy of peri-implantitis: a systematic review. Int J Oral Maxillofac Implants. 2014;29 Suppl:325-45. doi:10.11607/jomi.2014suppl.g5.3. Review. PubMed PMID: 24660207.

Heitz-Mayfield LJ, Salvi GE, Mombelli A, Loup PJ, Heitz F, Kruger E, Lang NP. Supportive peri-implant therapy following anti-infective surgical peri-implantitis treatment: 5-year survival and success. Clin Oral Implants Res. 2016 Jun 23. doi: 10.1111/clr.12910. [Epub ahead of print] PubMed PMID: 27335316.

Heitz-Mayfield LJ, Trombelli L, Heitz F, Needleman I, Moles D. A systematic review of the effect of surgical debridement vs non-surgical debridement for the treatment of chronic periodontitis. J Clin Periodontol. 2002;29 Suppl 3:92-102.

Heitz-Mayfield LJ. Peri-implant diseases: diagnosis and risk indicators. J Clin Periodontol 2008; 35 (Suppl. 8): 292–304.

Herrera D, Alonso B, Leon R, Roldan S, Sanz M. Antimicrobial therapy in periodontitis: the use of systemic antimicrobials against the subgingival biofilm. J Clin Periodontol 2008; 35 (Suppl. 8): 45–66.

Herrera D, Matesanz P, Bascones-Martínez A, Sanz M. Local and systemic antimicrobial therapy in periodontics. J Evid Based Dent Pract. 2012 Sep;12(3 Suppl):50-60.

Holm-Pedersen P, Lang NP, Muller F. What are the longevities of teeth and oral implants?Clin. Oral Impl. Res. 18 (Suppl. 3), 2007; 15-19

Hultin M, Komiyama A, Klinge B. Supportive therapy and the longevity of dental implants: a systematic review of the literature. Clin Oral Implants Res. 2007;18 Suppl 3:50-62.

Hur Y, Ogata Y. Insufficient evidence to support the use of laser therapy for peri-implantitis. J Am Dent Assoc. 2016 May;147(5):369-71. doi:10.1016/j.adaj.2016.02.012. Epub 2016 Mar 12. PubMed PMID: 26979380.

Huynh-Ba G, Kuonen P, Hofer D, Schmid J, Lang NP, Salvi GE. The effect of periodontal therapy on the survival rate and incidence of complications of multirooted teeth with furcation involvement after an observation period of at least 5 years: a systematic review. J Clin Periodontol 2009; 36: 164–176.

Jeffcoat MK, Chung Wang I, Reddy MS. Radiographic diagnosis in periodontics. Periodontology 2000 1995;7:5468.

Jepsen S, Berglundh T, Genco R, Aass AM, Demirel K, Derks J, Figuero E, Giovannoli JL, Goldstein M, Lambert F, Ortiz-Vigon A, Polyzois I, Salvi GE, Schwarz F, Serino G, Tomasi C, Zitzmann NU. Primary prevention of periimplantitis: managing peri-implant mucositis. J Clin Periodontol 2015; 42 (Suppl.16): S152–S157. doi: 10.1111/jcpe.12369.

Jin L, Cao C. Clinical diagnosis of trauma from occlusion and its relation with severity of periodontitis. J Clin Periodontol 1992; 19: 92-97.

Karoussis IK, Salvi GE, Heitz-Mayfield LJ, Brägger U, Hämmerle CH, Lang NP. Long-term implant prognosis in patients with and without a history of chronic periodontitis: a 10-year prospective cohort study of the ITI Dental Implant System. Clin Oral Implants Res. 2003 Jun;14(3):329-39.

Kassebaum NJ, Bernabè E, Dahiya M., Bhandari B., Murray C.J.L., Marcenes W. Global Burden of Severe Periodontitis in 1990-2010: A Systematic Review and Metaregression J Dent Res 2014, 93(11):1045-1053.

Keagle JG, Garnick JJ, Searle JR, King GE, Morese PK. Gingival resistance to probing forces. I Determination of optimal probe diameter. J Periodontol 1989; 60: 167-171.

Keestra JA, Grosjean I, Coucke W, Quirynen M, Teughels W. Non-surgical periodontal therapy with systemic antibiotics in patients with untreated aggressive periodontitis: a systematic review and meta-analysis. J Periodontal Res. 2015 Dec;50(6):689-706

Khoshkam V, Suárez-López Del Amo F, Monje A, Lin GH, Chan HL, Wang HL.Long-term Radiographic and Clinical Outcomes of Regenerative Approach for Treating Peri-implantitis: A Systematic Review and Meta-analysis. Int J Oral Maxillofac Implants. 2016 Sep 6. doi: 10.11607/jomi.4691. [Epub ahead of print] PubMed PMID: 27598426.

Klein F, Kim TS, Hassfeld S, Staehle HJ, Reitmeir P, Holle R, Eickholz P. Radiographic defect depth and width for prognosis and description of periodontal healing of infrabony defects. J Periodontol. 2001 Dec;72(12):1639-46.

Knight ET, Liu J, Seymour GJ, Faggion CM Jr, Cullinan MP. Risk factors that may modify the innate and adaptive immune responses in periodontal diseases. Periodontol 2000. 2016 Jun;71(1):22-51.

Kotsakis GA1, Konstantinidis I, Karoussis IK, Ma X, Chu H. Systematic review and meta-analysis of the effect of various laser wavelengths in the treatment of peri-implantitis. J Periodontol. 2014 Sep;85(9):1203-13. doi: 10.1902/jop.2014.130610. Epub 2014 Jan 20.

Kotsovilis S, Fourmousis I, Karoussis IK, Bamia C. A systematic review and meta-analysis on the effect of implant length on the survival of rough-surface dental implants. J Periodontol. 2009 Nov;80(11):1700-18.

Labriola A, Needleman I, Moles DR. Systematic review of the effect of smoking on nonsurgical periodontal therapy. Periodontol 2000. 2005;37:124-37. Review.

Lang NP, Berglundh T. Periimplant diseases: where are we now?–Consensus of the Seventh European Workshop on Periodontology. J Clin Periodontol 2011: 38(Suppl. 11): 178–181.

Lang NP, Lindhe J, van der Velden U on behalf of the European Workshop in Periodontology group D. Advances in the prevention of periodontitis. Consensus report of the 5th European Workshop in Periodontology. J Clin Periodontol 2005; 32(Suppl. 6): 291–293.

Lang NP, Lindhe J.eds Clinical Periodontology and Implant Dentistry. 6th edition Wiley Blackwell 2016.

Lang NP, Tan WC, Krahenmann MA, Zwahlen M. A systematic review of the effects of full-mouth debridement with and without antiseptics in patients with chronic periodontitis. J Clin Periodontol 2008; 35 (Suppl. 8): 8–21.

Lin GH1, Chan HL, Wang HL.The significance of keratinized mucosa on implant health: a systematic review. J Periodontol. 2013 Dec;84(12):1755-67. doi: 10.1902/jop.2013.120688. Epub 2013 Mar 1.

Lindhe J, Meyle J. Peri-implant diseases: consensus Report of the Sixth European Workshop on Periodontology. J ClinPeriodontol 2008: 35: 282–285.

Little TM, Girgis SS,, Masotti RE. Diphenylhyidantoin inducedgingival hyperplasia:its response to drug dosage. Developmental Medicine and Child neurology 1975; 17: 421-424.

Marcantonio C, Nicoli LG, Marcantonio Junior E, Zandim-Barcelos DL.Prevalence and Possible Risk Factors of Peri-implantitis: A Concept Review. J Contemp Dent Pract. 2015 Sep 1;16(9):750-7. PubMed PMID: 26522602.

Martin-Cabezas R et al Clinical efficacy of probiotics as an adjunctive therapy to non-surgical periodontal treatment of chronic periodontitis: a systematic review and meta-analysis. J Clin Periodontol. 2016 Jun;43(6):520-30

Martinez-Canut P. Predictors of tooth loss due to periodontal disease in patients following long-term periodontal maintenance. J Clin Periodontol. 2015 Dec;42(12):1115-25.

Matuliene G, Pjetursson BE, Salvi GE, Schmidlin K, Brägger U, Zwahlen M, Lang NP. Influence of residual pockets on progression of periodontitis and tooth loss: results after 11 years of maintenance. J Clin Periodontol. 2008 Aug;35(8):685-95.

Mizutani K, Aoki A, Coluzzi D, Yukna R, Wang CY, Pavlic V, Izumi Y. Lasers in minimally invasive periodontal and peri-implant therapy Periodontology 2000, Vol. 71, 2016, 185–212

Mombelli A, Lang NP. The diagnosis and treatment of peri-implantitis. Periodontology 2000 1998;17:63-76.

Mombelli A, Müller N, Cionca N. The epidemiology of peri-implantitis. Clin Oral Implants Res. 2012 Oct;23 Suppl 6:67-76. doi: 10.1111/j.1600-0501.2012.02541.x. Review. PubMed PMID: 23062130.

Monje A, Alcoforado G, Padial-Molina M, Suarez F, Lin GH, Wang HL. Generalized aggressive periodontitis as a risk factor for dental implant failure: a systematic review and meta-analysis. J Periodontol. 2014 Oct;85(10):1398-407.doi: 10.1902/jop.2014.140135. Epub 2014 May 16. Review. PubMed PMID: 24835415.

Monje A, Aranda L, Diaz KT, Alarcón MA, Bagramian RA, Wang HL, Catena A. Impact of Maintenance Therapy for the Prevention of Peri-implant Diseases: A Systematic Review and Meta-analysis. J Dent Res. 2016 Apr;95(4):372-9. doi:10.1177/0022034515622432. Epub 2015 Dec 23. Review. PubMed PMID: 26701350.

Monje A, Aranda L, Diaz KT, Alarcón MA, Bagramian RA, Wang HL, Catena A. Impact of Maintenance Therapy for the Prevention of Peri-implant Diseases: A Systematic Review and Meta-analysis. J Dent Res. 2016 Apr;95(4):372-9

Muller HP, Ulbrich M, Heinecke A. Alveolar bone loss in adults as assessed on panoramic radiographs. (II) Multilevel models. Clin Oral Investig. 2005 Jun;9(2):105-10.

Muller HP, Ulbrich M. Alveolar bone levels in adults as assessed on panoramic radiographs. (I) Prevalence, extent, and severity of even and angular bone loss. Clin Oral Investig. 2005 Jun;9(2):98-104.

Muthukuru M, Zainvi A, Esplugues EO, Flemmig TF. Non-surgical therapy for the management of peri-implantitis: a systematic review. Clin Oral Implants Res. 2012 Oct;23 Suppl 6:77-83. doi: 10.1111/j.1600-0501.2012.02542.x. Review. PubMed PMID: 23062131.

Natto ZS, Aladmawy M, Levi PA Jr, Wang HL. Comparison of the efficacy of different types of lasers for the treatment of peri-implantitis: a systematic review. Int J Oral Maxillofac Implants. 2015 Mar-Apr;30(2):338-45. doi:10.11607/jomi.3846. Review. PubMed PMID: 25830394.

Newton T.J. and Asimakopolou K. Managing oral hygiene as a risk factor for periodontal disease: a systematic reviwe of psychological approaches to behaviour change for improved plaque control in periodontal management. J of Clinical Periodontology; 42: (suppl. 16) S36-S46

Nibali L, Zavattini A, Nagata K, Di Iorio A, Lin GH, Needleman I, Donos N. Tooth loss in molars with and without furcation involvement - a systematic review and meta-analysis. J Clin Periodontol. 2016 Feb;43(2):156-66.

Pagliaro U., Nieri M., Rotundo R, Cairo F. Carnevale G., Esposito M., Cortellini P. and Pini-Prato G. Clinical Guidelines of the Italian Society of Periodontology for the Reconstructive Surgical Treatment of Angular Bony Defects in Periodontal Patients. J Periodontol 2008; 79:2219-2232.

Papapanou PN, Tonetti MS. Diagnosis and epidemiology of periodontal osseous lesions. Periodontology 2000 2000;22:8-21.

Papathanasiou E, Finkelman M, Hanley J, Parashis AO. Prevalence, Etiology and Treatment of Peri-Implant Mucositis and Peri-Implantitis: A Survey of Periodontists in the United States. J Periodontol. 2016 May;87(5):493-501. doi: 10.1902/jop.2015.150476. Epub 2015 Dec 8. PubMed PMID: 26643222.

Paster BJ, Dewhirst FE. Molecular microbial diagnosis. Periodontology 2000 2009;51:38-44.

Pérez-Chaparro PJ, Duarte PM, Shibli JA, Montenegro S, Heluy SL, Figueiredo LC, Faveri M, Feres M. The Current Weight of Evidence of the Microbiological Profile Associated With Peri-Implantitis: A Systematic Review. J Periodontol.2016 Jul 15:1-16. [Epub ahead of print] PubMed PMID: 27420109.

Quirynen M, Abarca M, Van Assche N, Nevins M, van Steenberghe D. Impact of supportive periodontal therapy and implant surface roughness on implant outcome inpatients with a history of periodontitis. J Clin Periodontol. 2007;34(9):805-15.

Rabelo CC et al Systemic antibiotics in the treatment of aggressive periodontitis. A systematic review and a Bayesian Network meta-analysis. J Clin Periodontol. 2015 Jul;42(7):647-57

Rakic M, Grusovin MG, Canullo L. The Microbiologic Profile Associated with Peri-Implantitis in Humans: A Systematic Review. Int J Oral Maxillofac Implants. 2016 Mar-Apr;31(2):359-68. doi: 10.11607/jomi.4150. Epub 2015 Oct 6. PubMed PMID: 26478978.

Ramanauskaite A, Daugela P, Juodzbalys G. Treatment of peri-implantitis: Meta-analysis of findings in a systematic literature review and novel protocol proposal. Quintessence Int. 2016;47(5):379-93. doi: 10.3290/j.qi.a35131. PubMed PMID: 26574611.

Renvert S, Polyzois I, Claffey N. How do implant surface characteristics influence peri-implant disease? J Clin Periodontol. 2011 Mar;38 Suppl 11:214-22. doi: 10.1111/j.1600-051X.2010.01661.x. Review. PubMed PMID: 21323717.

Renvert S, Polyzois I, Claffey N. Surgical therapy for the control of peri-implantitis. Clin Oral Implants Res. 2012 Oct;23 Suppl 6:84-94. doi: 10.1111/j.1600-0501.2012.02554.x. Review. PubMed PMID: 23062132.

Renvert S, Polyzois I, Persson GR. Treatment modalities for peri-implant mucositis and peri-implantitis. Am J Dent. 2013 Dec;26(6):313-8. Review. PubMedPMID: 24640434.

Renvert S, Polyzois I. Risk indicators for peri-implant mucositis: a systematic literature review. J Clin Periodontol 2015; 42 (Suppl. 16): S172–S186. doi:10.1111/jcpe.12346.

Renvert S, Quirynen M. Risk indicators for peri-implantitis. A narrative review. Clin Oral Implants Res. 2015 Sep;26 Suppl 11:15-44. doi:10.1111/clr.12636. PubMed PMID: 26385619.

Renvert S, Roos-Jansa°ker A-M, Claffey N. Non-surgical treatment of peri-implant mucositis and peri-implantitis: a literature review. J Clin Periodontol 2008; 35 (Suppl. 8): 305–315.

Rokn A, Aslroosta H, Akbari S, Najafi H, Zayeri F, Hashemi K. Prevalence of peri-implantitis in patients not participating in well-designed supportive periodontal treatments: a cross-sectional study. Clin Oral Implants Res. 2016 Feb 26. doi: 10.1111/clr.12800. [Epub ahead of print] PubMed PMID: 26919480.

Roldan S, Sanchez N, Sculean A, Slot DE, Trombelli L, West N, Winkel E. Effect of professional mechanical plaque removal on secondary prevention of periodontitis and the complications of gingival and periodontal preventive measures: consensus report of group 4 of the 11th European Workshop on Periodontology on effective prevention of periodontal and peri-implant diseases. J Clin Periodontol. 2015 Apr;42 Suppl 16:S214-20. doi: 10.1111/jcpe.12367. PubMed PMID: 25626357.

Romanos GE, Javed F, Delgado-Ruiz RA, Calvo-Guirado JL. Peri-implant diseases: a review of treatment interventions. Dent Clin North Am. 2015Jan;59(1):157-78. doi: 10.1016/j.cden.2014.08.002. Epub 2014 Oct 7. Review.PubMed PMID: 25434564.

Romanos GE, Javed F. Laser Therapy is Safe but not Superior to Conventional Treatment of Peri-implantitis. J Evid Based Dent Pract. 2015 Jun;15(2):55-7. doi: 10.1016/j.jebdp.2015.03.005. Epub 2015 Mar 28. PubMed PMID: 25987382.

Romanos GE, Weitz D. Therapy of peri-implant diseases. Where is the evidence?J Evid Based Dent Pract. 2012 Sep;12(3 Suppl):204-8. doi: 10.1016/S1532-3382(12)70038-6. Review. PubMed PMID: 23040349.

Roos-Jansåker AM, Almhöjd US, Jansson H. Treatment of peri-implantitis: clinical outcome of chloramine as an adjunctive to non-surgical therapy, a randomized clinical trial. Clin Oral Implants Res. 2015 May 26. doi:10.1111/clr.12612. [Epub ahead of print] PubMed PMID: 26013241.

Sahrmann P, Attin T, Schmidlin PR. Regenerative treatment of peri-implantitis using bone substitutes and membrane: a systematic review. Clin Implant Dent Relat Res. 2011 Mar;13(1):46-57. doi: 10.1111/j.1708-8208.2009.00183.x. Review. PubMed PMID: 19681931

Salvi GE, Aglietta M, Eick S, Sculean A, Lang NP & Ramseier CA. Reversibility of experimental peri-implant mucositis compared with experimental gingivitis in humans. Clin. Oral Impl. Res. 23, 2012 182–190 doi: 10.1111/j.1600-0501.2011.02220.x

Salvi GE, Ramseier CA. Efficacy of patient-administered mechanical and/or chemical plaque control protocols in the management of peri-implant mucositis. A systematic review. J Clin Periodontol. 2015 Apr;42 Suppl 16:S187-201. doi:10.1111/jcpe.12321. Review. PubMed PMID: 25495416.

Salvi GE, Zitzmann NU. The effects of anti-infective preventive measures on the occurrence of biologic implant complications and implant loss: a systematic review. Int J Oral Maxillofac Implants. 2014;29 Suppl:292-307. doi:10.11607/jomi.2014suppl.g5.1. Review. PubMed PMID: 24660205.

Sanz M, Bäumer A, Buduneli N, Dommisch H, Farina R, Kononen E, Linden G, Meyle J, Preshaw PM, Quirynen M, Salvi GE, Zitzmann NU, The effect of anti-infective preventive measures on the occurrence of biologic complications and implant loss: A systematic Review. Int J Oral Maxillofac Impl 2014: 29 (suppl) 292-307

Sanz M, Bäumer A, Buduneli N, Dommisch H, Farina R, Kononen E, Linden G, Meyle J, Preshaw PM, Quirynen M, Roldan S, Sanchez N, Sculean A, Slot DE, Trombelli L, West N, Winkel E. Effect of professional mechanical plaque removal on secondary prevention of periodontitis and the complications of gingival and periodontal preventive measures: consensus report of group 4 of the 11th European Workshop on Periodontology on effective prevention of periodontal and peri-implant diseases. J Clin Periodontol. 2015 Apr;42 Suppl 16:S214-20. doi: 10.1111/jcpe.12367. PubMed PMID: 25626357.

Sanz M, Chapple IL; Working Group 4 of the VIII European Workshop on Periodontology. Clinical research on peri-implant diseases: consensus report of Working Group 4. J Clin Periodontol. 2012 Feb;39 Suppl 12:202-6. doi:10.1111/j.1600-051X.2011.01837.x. PubMed PMID: 22533957.

Sarmiento HL, Norton MR, Fiorellini JP. A Classification System for Peri-implant Diseases and Conditions. Int J Periodontics Restorative Dent. 2016 Sep-Oct;36(5):699-705. doi: 10.11607/prd.2918. PubMed PMID: 27560674.

Schinaglia GP, Forniti F, Cavallini R, Piva R, del SennoL. Cyclosporin A increases type 1 procollagen production and mRNA level in human gingival fibroblasts in vitro.J Oral Path and Med 1992; 21: 181-185.

Schou S. Implant treatment in periodontitis-susceptible patients: a systematic review. J Oral Rehabil. 2008 Jan;35 Suppl 1:9-22.

Schwarz F, Becker K, Renvert S. Efficacy of air polishing for the non-surgical treatment of peri-implant diseases: a systematic review. J Clin Periodontol. 2015 Oct;42(10):951-9. doi: 10.1111/jcpe.12454. Epub 2015 Oct 16. Review. PubMed PMID: 26362615.

Schwarz F, Iglhaut G, Becker J. Quality assessment of reporting of animal studies on pathogenesis and treatment of peri-implant mucositis and peri-implantitis. A systematic review using the ARRIVE guidelines. J Clin Periodontol. 2012 Feb;39 Suppl 12:63-72. doi: 10.1111/j.1600-051X.2011.01838.x.Review. PubMed PMID: 22533947.

Schwendicke F, Tu YK, Stolpe M. Preventing and Treating Peri-Implantitis: A Cost-Effectiveness Analysis. J Periodontol. 2015 Sep;86(9):1020-9. doi:10.1902/jop.2015.150071. Epub 2015 Apr 9. PubMed PMID: 25855573.

Sgolastra F et al Adjunctive photodynamic therapy to non-surgical treatment of chronic periodontitis: a systematic review and meta-analysis J Clin Period 2013; 40: 514-526

Sgolastra F, Gatto R, Petrucci A, Monaco A.Effectiveness of systemic amoxicillin/metronidazole as adjunctive therapy to scaling and root planing in the treatment of chronic periodontitis: a systematic review and meta-analysis. J Periodontol. 2012 Oct;83(10):1257-69.

Sgolastra F, Petrucci A, Severino M, Gatto R, Monaco A. Periodontitis, implant loss and peri-implantitis. A meta-analysis. Clin Oral Implants Res. 2015 Apr;26(4):e8-16. doi: 10.1111/clr.12319. Epub 2013 Dec 31. PubMed PMID: 24382358.

Sgolastra F, Petrucci A, Severino M, Gatto R, Monaco A. Smoking and the risk of peri-implantitis. A systematic review and meta-analysis. Clin Oral Implants Res. 2015 Apr;26(4):e62-7. doi: 10.1111/clr.12333. Epub 2014 Jan 18. PubMed PMID:24438442.

Sgolastra F, Severino M, Petrucci A, Gatto R, Monaco A.Effectiveness of metronidazole as an adjunct to scaling and root planing in the treatment of chronic periodontitis: a systematic review and meta-analysis. J Periodontal Res. 2014 Feb;49(1):10-9

Sheiham A and Netuveli GS. Periodontal diseases in Europe Periodontology 2000, Vol. 29, 2002, 104–121

Simpson TC, Weldon JC, Worthington HV, Needleman I, Wild SH, Moles DR, Stevenson B, Furness S, Iheozor-Ejiofor Z. Treatment of periodontal disease for glycaemic control in people with diabetes mellitus. Cochrane Database Syst Rev. 2015 Nov 6;(11)

Slot DE Jorritsma KH, Cobb CM, Van der Weijden FA. The effect of the thermal diode laser (wavelength 808-980 nm) in non-surgical periodontal therapy: a systematic review and meta-analysis. J Clin Period 2014; 41: 681-692

Sousa V, Mardas N, Farias B, Petrie A, Needleman I, Spratt D, Donos N. A systematic review of implant outcomes in treated periodontitis patients. Clin Oral Implants Res. 2016 Jul;27(7):787-844. doi: 10.1111/clr.12684. Epub 2015 Sep 18. Review. PubMed PMID: 26381260.

Stajčić Z, Stojčev Stajčić LJ, Kalanović M, Đinić A, Divekar N, Rodić M. Removal of dental implants: review of five different techniques. Int J Oral Maxillofac Surg. 2016 May;45(5):641-8. doi: 10.1016/j.ijom.2015.11.003. Epub 2015 Dec 10. PubMed PMID: 26688293.

Tarnow DP. Increasing Prevalence of Peri-implantitis: How Will We Manage? J Dent Res. 2016 Jan;95(1):7-8. doi: 10.1177/0022034515616557. PubMed PMID:26701918.

The Board of the SIdP, Italian Society of Periodontology and Implantology Letter to the Journal Eur J Clin Microbiol Infect Dis. 2016;accepted for publication

Tonetti MS, Chapple IL, Jepsen S, Sanz M. Primary and secondary prevention of periodontal and peri-implant diseases: Introduction to, and objectives of the 11th European Workshop on Periodontology consensus conference. J Clin Periodontol. 2015 Apr;42 Suppl 16:S1-4. doi: 10.1111/jcpe.12382. PubMed PMID:25683242.

Tonetti MS, Chapple IL; J Clin Periodontol. 2011 Mar;38 Suppl 11:114-8 of Seventh European Workshop on Periodontology. Biological approaches to the development of novel periodontal therapies--consensus of the Seventh European Workshop on Periodontology

Tonetti MS, Eickholz P, Loos BG, Papapanou P, van der Velden U, Armitage G,Bouchard P, Deinzer R, Dietrich T, Hughes F, Kocher T, Lang NP, Lopez R,Needleman I, Newton T, Nibali L, Pretzl B, Ramseier C, Sanz-Sanchez I,Schlagenhauf U, Suvan JE. Principles in prevention of periodontal diseases: Consensus report of group 1 of the 11th European Workshop on Periodontology on effective prevention of periodontal and peri-implant diseases. J Clin Periodontol. 2015 Apr;42 Suppl 16:S5-11. doi: 10.1111/jcpe.12368. PubMed PMID: 25639948

Trombelli L, Farina R. Clinical outcomes with bioactive agents alone or in combination with grafting or guided tissue regeneration. J Clin Periodontol. 2008 Sep;35(8 Suppl):117-35.

Turri A, Rossetti PH, Canullo L, Grusovin MG, Dahlin C. Prevalence of Peri-implantitis in Medically Compromised Patients and Smokers: A Systematic Review. Int J Oral Maxillofac Implants. 2016 Jan-Feb;31(1):111-8. doi:10.11607/jomi.4149. Review. PubMed PMID: 26800167.

Van der Weijden FA, Campbell SL, Dörfer CE, González-Cabezas C, Slot DE. Safety of oscillating-rotating powered brushes compared to manual toothbrushes: a systematic review. J Periodontol. 2011 Jan;82(1):5-24.

van Winkelhoff AJ. Antibiotics in the treatment of peri-implantitis. Eur J Oral Implantol. 2012;5 Suppl:S43-50. Review. PubMed PMID: 22834393.

Verdugo F, Laksmana T, Uribarri A. Systemic antibiotics and the risk of superinfection in peri-implantitis. Arch Oral Biol. 2016 Apr;64:39-50. doi:10.1016/j.archoralbio.2015.12.007. Epub 2015 Dec 29. Review. PubMed PMID:26761363.

Verdugo F, Laksmana T, Uribarri A. Systemic antibiotics and the risk of superinfection in peri-implantitis. Arch Oral Biol. 2016 Apr;64:39-50. doi:10.1016/j.archoralbio.2015.12.007. Epub 2015 Dec 29. Review. PubMed PMID:26761363.

Waerhaug J. Histologic considerations which govern where the margin of restorations should be located in relation to the gingiva. Dent Clin of North Amer 1960; 167-176.

Walmsley AD, Lea SC, Landini G, Moses AJ. Advances in power driven pocket/root instrumentation. J Clin Periodontol 2008; 35 (Suppl. 8): 22–28.

Wennstrom J et al Subgingival debridement of periodontal pockets by air polishing in comparison with ultrasonic instrumentation during maintenance therapy J Clin Periodontol 2011; 38: 820-827

Weston P1, Yaziz YA, Moles DR, Needleman I. Occlusal interventions for periodontitis in adults. Cochrane Database Syst Rev. 2008 Jul 16;(3)

Yaacob M, Worthington HV, Deacon SA, Deery C, Walmsley AD, Robinson PG, Glenny AM. Powered versus manual toothbrushing for oral health. Cochrane Database Syst Rev. 2014 Jun 17;(6)

Zandbergen D, Slot DE, Cobb CM, Van der Weijden FA.The clinical effect of scaling and root planing and the concomitant administration of systemic amoxicillin and metronidazole: a systematic review. J Periodontol. 2013 Mar;84(3):332-51

Zangrando MS, Damante CA, Sant'Ana AC, Rubo de Rezende ML, Greghi SL, Chambrone L. Long-term evaluation of periodontal parameters and implant outcomes in periodontally compromised patients: a systematic review. J Periodontol. 2015 Feb;86(2):201-21. doi: 10.1902/jop.2014.140390. Epub 2014 Oct 2. Review. PubMed PMID: 25272977.

Zhao Y, Yin Y, Tao L, Nie P, Tang Y, Zhu M. Er:YAG laser versus scaling and root planing as alternative or adjuvant for chronic periodontitis treatment: a systematic review. J Clin Periodontol. 2014 Nov;41(11):1069-79. doi: 10.1111/jcpe.12304. Epub 2014 Oct 10. Review.PMID:25164559

Zitzmann NU, Berglundh T. Definition and prevalence of peri-implant diseases. J Clin Periodontol 2008; 35 (Suppl. 8): 286–291

Zucchelli G, Mele M, Mazzotti C, Marzadori M, Montebugnoli L, De Sanctis M, Coronally advanced flap with and without vertical releasing incisions for the treatment of multiple gingival recessions: a comparative controlled randomized clinical trial. J Periodontol. 2009 Jul;80(7):1083-94.

ORAL SURGERY

Oral surgery is the branch of dental dentistry that deals with the diagnosis and relative surgical treatment of diseases that involve soft and hard tissues of oral cavity and teeth. The treatments which are considered necessary for preventative and aesthetic reasons are also included.

Diagnosis

Medical history is aimed to highlight any systemic condition that may interfere with the diagnosis and also the subsequent surgical treatment. It is indispensable to investigate previous hospitalizations and / or surgery, trauma and chronic diseases, major or minor systemic diseases, allergies, use of drugs, spoiled habits like cigarette smoking, alcohol ... (Andrade MG 2007)
The remote dental history is aimed at detecting previous dental treatments;
the next dental history is, instead, oriented to the knowledge of the symptomatology for which the treatment is required, assessing, where relevant, the duration, the affected area, the frequency, the responsible factors for exacerbation and / or attenuation, time and mode of onset, epiphenomenos, if present.
The main objective of the clinical examination is to formulate a correct diagnosis in order to identify needs and therapeutic modes most appropriates for the single patient.
The patient's examination must be both extra and intra-oral and can be supplemented with clinical and / or laboratory exams. In the extra oral exam, the operator must point out any skin discrepancies, the presence and extension of head and neck swelling, lymphadenopathy and the presence of
of any asymmetry to the temporomandibular joint. With intra-oral examination
the operator must assess the dental formula, the oral hygiene level and the oral mucosa condition, including hypertrophic-hyperplastic and / or ulcerative injuries, the presence of swelling, fistulae or other injuries, the present teeth conditions, any dental anomalies, the periodontal condition, the quality of any restorations.
In order to get a more accurate diagnosis, some instrumental exams are a useful aid in oral surgery, such as endoscopic radiographs, orthopantomography (OPT), computerized tomography (CBCT), Magnetic Resonance (RMN) and ultrasound.
The intraoral Rxs allow to highlight the dental structure, the number of roots and partly their anatomy; it is also possible to study osteolytic areas of the periapice and / or along the dental root; they're also valid in post-operative follow up.
OPT is the basic exam in oral surgery because it allows to have a comprehensive upper and lower jaw bone view, all dental elements and important anatomical structures such as the mandibular canal, the jaw bone, the maxillary sinus. If the radiographic image is not sufficiently indicative, precise and

consistent, it is possible to make a CBCT-Cone Beam TC that allows to have richer information about the involved hard tissues, the position of impacted dental elements, and relevant anatomic structures.
About soft tissue exam, instead, RNM and ultrasound represent valid instruments for more detailed investigations of the temporomandibular joint, the salivary glands and lymph nodes. The listed radiographic examinations are essential according to the criteria of justification and appropriateness.
Blood tests are useful in order to evaluate any systemic alterations during oral surgery,
Pre-operatively, standard blood tests like can be provided, like complete blood count, platelets count, VES, azotemia, glycemia, prothrombinic activity, INR, activated partial thromboplastin time, standard urine and HBS-Ag, HCV, and HIV markers, only if the anamnesis makes them necessary.

Indications and contraindications to surgical treatment

Are the responsibility of oral surgery:
- simple dental extractions;
- complex dental extractions;
- extraction of impacted teeth;
- germectomies;
- exposure of impacted teeth for orthodontic purposes;
- pre-prosthetic surgery and interventions supporting orthodontic treatments;
- odontogenic sinus diseases;
- dental implantation and transplantation;
- apicectomy with retrograde filling;
- rizectomy;
- biopsy of soft and hard tissues;
- removal of tumor formations of soft and hard tissues;
- removal of pathological frenules;
- removal of salivary calculi;
- insertion of osteointegrated implants;
- reconstruction of hard and soft tissues

Contraindications to surgical treatment are essentially related to the patient's health. In general, as in all medical disciplines, it is contraindicated to perform oral surgery interventions when the surgical benefits are lower than its risks and, of course, in all patients who do not give their consent to treatment (Brusati R 1999) (Myatake Y 2004).
The patient must be informed of the diagnosis, therapy, presumable prognosis and any alternative treatments.

Bibliography

Andrade MG, Weissman R, Oliveira MG, Heitz C. Tooth displacement and root dilaceration after trauma to primary predecessor: an evaluation by computed tomography. Dent Traumatol 23 (6):364-7; 2007.

Brusati R, Chiapasco M. Elementi di chirurgia oro-maxillo-facciale. Masson, Milano p. 73;1999.

Myatake Y, Kazama M, Isoda M, ,Nejima J. Internal medicine education in dentistry: knowledge required varies according to dental specialty.Eur J Dent Educ 8(1):18-23;2004.

Extractions should be limited to severely compromised dental elements not functionally recoverable due to infectious diseases (caries, periodontal diseases, etc ...), in the case of dental elements that for strategic reasons of treatment cannot be preserved and in order to prevent infectious and / or traumatic diseases associated with teeth.

Preservation of the crestal bone is consistent in the decision to carry out an extraction, also considering the possibility of implant-prosthetic replacement of the extracted tooth and the growing importance of patients' oral aesthetic demands.

Prior to any extraction, careful preoperative evaluation is required to be performed with history, clinical examination, radiographic exams and if necessary, blood tests.

The extraction of fully-arched dental elements is recommended in all those conditions in which the teeth cannot be recovered in restorative, endodontic, periodontal and orthodontic conditions.

Specifically, dental extraction is indicated under the following conditions: periodontal compromised tooth with high horizontal and vertical mobility and not recoverable, tooth with caries not treatable through conservative methods, external or internal root not treatable resorption, trauma with non - recoverable fracture of dental element, teeth involved in a bone fracture rhyme, teeth associated with bone or soft tissues injuries. They are also indications to extraction: orthodontic reasons and medical or surgical conditions for which extraction is required such as prophylaxis (organ transplants, chemotherapy, radiation therapy, heart valve replacement, beginning of bisphosphonate therapy, especially if administered intravenously ...), refusal of patient to conservative therapy, ectopic tooth (Barone A 2011).

After local anesthesia (plessica or loco-regional), proceed with the use of straight or angled syndesmotomy, if deemed possible. Once the periotomy is completed, proceed with dental luxation that must be carried out with extreme caution.
Dental extraction can be completed with the use of appropriate dental levers.
Sometimes, in the case of a multiradicular tooth, coronotomy is recommended in order to avoid root fractures (Chiapasco M 2006) (Covani U 2003) (Di Lauro F 2000).
In the teeth extraction, sometimes it is necessary to elevate a muco-periosteal flap to improve visibility and access to any fractured root fragments; in this case the flap must be large enough to allow appropriate access and a adequate visibility to the operator.

When necessary, the most frequently used antibiotic prophylaxis scheme is the administration of 2 grams of amoxicillin (or equivalent) one hour before surgery, by continue for 2-5 days depending on the different circumstances.

Bibliography

Barone A e Bianchi A. Manuale di Chirurgia Orale; Ed. Elsevier (2011).

Chiapasco M. Manuale Illustrato di Chirurgia Orale; Ed. Masson/Elsevier (2006)

Covani U, Ferrini F. Chirurgia Orale; Ed. Martina Bologna s.r.l. 2003.

Di Lauro F, Bucci E. Chirurgia odontostomatologica con note di patologia. Editore Florio, 2000.

In the presence of a tooth with complex coronary and / or radicular anatomy that involves particular technical difficulties, more detailed radiographic examinations and, sometimes, execution of an access flap before extraction are required.

In these cases, not only the anatomical radicular conformation but also the anatomical relationships with important structures such as the mandibular canal, the jawbone and the maxillary sinus. should be carefully evaluated.
Surgical extraction technique for teeth with complex coronal and / or root anatomy can be more or less invasive according to the position of the tooth, to the remaining dental tissue and its relations with surrounding anatomical structures. It is usually necessary to plan an access flap during the preoperative phase, when necessary, and local anesthesia (plessica or loco-regional). The entity of the flap elevation depends on the type of difficulty of tooth extraction. In some cases, it can be recommended to make the osteotomy / osteoctomy to allow easier access to the dental element (always favouring odontotomy

techniques and minimizing osteotomy techniques). For bone resection, appropriate burs are used under constant irrigation. At the end of the extraction, the suture will be applied (SIdCO 2015) (Santoro F 1996).

A further detailed study is required by specific radiographic exams in case of erupted teeth that, in the preliminary radiographic examination, have clear anatomical relations which indicate a risk of oro-antral communication in order to set up a suitable prophylactic treatment and to inform the patient adequately about the involved risks and on a possible need for a plastic closure of the resulting oro-antral communication.

Bibliography

Santoro F, Maiorana C. Chirurgia Speciale Odontostomatologica. Masson, 1996.

SIdCO, Società Italiana di Chirurgia Odontostomatologica, Chirurgia Odontostomatologica, Edizioni Minerva Medica, 2015.

The indications for the removal of a third molar in total or partial inclusion are different depending on whether or not the tooth is associated with signs or symptoms.

If the third molar is symptomatic, the clinical indications of extraction are represented by pericoronitis, non-recoverable tooth for caries, fracture, periodontal or non-treatable endodontic injuries, acute or chronic infections (abscesses and cellulitis), form, size and position abnormalities of wisdom tooth causing injuries to the surrounding hard and soft tissues (Marciani RD 2007) (Brehmer B 1996).

In the absence of symptoms, the indications of extraction are: prevention of the second molar periodontal damage and / or caries (Sammartino G 2009), completion of periodontal therapies, completion of prosthetic rehabilitation, facilitate orthodontic movements (Van der Schoot EA 1997), presence of a tooth located in a bone fracture rhyme, tooth that is involved in a neoplastic excision zone, tooth interference with orthognatic and / or reconstructive surgery,

preventive and / or prophylactic removal in patients with major medical problems (Tai CC 1994) or particular surgical conditions or therapeutic treatments, conscious patient's rejection of a non-surgical treatment, in those patients who practice sports with high probability of trauma (ex. boxing, skiing, rugby, etc.), in subjects under 25 years of age to reduce the probability of periodontal injury of the second molar associated with late removal (Kugelberg C.F 1990, 1991).

As always, careful pre-operative assessment is necessary before extraction (Chandler LP1988) based on the medical history, the extraoral clinical examination (presence of satellite lymphadenitis, facial type and mouth opening) and the intraoral evaluation (presence of edema, swelling and mucosal health). In

addition, it should be evaluated the presence of caries of the tooth. The patient age may influence the indications of the extraction: up to completion of the third decade, the partial eruption in good position, with sufficient space and without associated disease can, in fact, lead to a complete eruption. In addition, radiographic examinations are indispensable because they define the exact position of the dental element and its continuity relationships with adjacent anatomical structures (Santamaria J 1997). The basic radiographic examination is OPT; they can also be carried out intraoral Rx and, if more accurate information is needed, TC or three-dimensional cone beam (Chandler L.P 1994) (Jhamb A 2009) (Kositbowornchai S 2010).

In case of lower third molar extraction, loco-regional anesthesia is performed at the inferior alveolar nerve and plessica and / or truncular to the buccinators nerve. For the extraction of the upper third molar is performed the plessica anesthesia. If the tooth is completely erupted, the same operating steps for simple extractions are performed. If the tooth is partially erupted or fully included, a mucoperiosteal incision with elevation of an access flap is performed. Afterwards the osteotomy is performed by using an appropriate drill mounted on a micromotor or surgical turbine, under constant irrigation. Subsequently, an odontotomy is performed by using a drill with a proper diameter to create space to overcome any undercuts, mounted on a micromotor or a surgical turbine and theluxation is carried out by usinglevers. After the extraction, the socket revision is performed, irrigating with physiological solution and suturing (Chiapasco M 2001).

The indications for the germectomy of third molars are those for the removal of impacted third molars in very early age.

The germectomy is the removal of a not fully formed tooth including its own follicle. The germ is comparable to the included tooth when the prediction of absence or incomplete eruption is within the third decade of life. The prediction is reliable when the lack of space is very evident, but not when the space available for the third molar is simply limited, even in relation to the age or state of the patient growth.

The surgical procedure, which must be carried out with the same cautions and the same planning described for the included third molar, involves the execution of a mucoperiosteal flap, osteotomy, odontotomy and suture.

Bibliography

Brehmer B, Lysell L, Rohlin H. Pathoses associated with mandibular third molars subjected to removal. Oral Surg Oral Med Oral Pathol Oral Radiol Endod 82(1): 10-7, 1996.

Chandler LP, Laskin D. Accuracy of radiographs and classification of impacted third molars. J Oral Maxillofacial Surg, 117: 461–5, 1988

Chiapasco M. Manuale illustrato di chirurgia orale. Masson editore, 2001.

Kositbowornchai S, Densiri-Aksorn W, Piumthanaroj P. Ability of two radiographic methods to identify the closeness between the mandibular third molar root and the inferior alveolar canal: a pilot study.Dentomaxillofac Radiol. 2010 Feb; 39(2):79-84.

Kugelberg CF. Impacted lower third molars and periodontal health. An epidemiological, methodological, retrospective and prospective clinical study. Swed Dent J Supp, 68: 1–52, 1990.

Kugelberg CF, Ahlstrom U, Ericson S, Hugoson A, Thilander H. The influence of anatomical, pathophysiological and other factors on periodontal healing after impacted lower third molar surgery. A *multiple regression analysis. J Clin Parodontol, 18(1): 37–43, 1991.*

Marciani RD. Third molar removal: an overview of indications, imaging, evaluation, and assessment of risk. Oral Maxillofacial Surg Clin North Am. 2007 Feb; 19(1):1-13, v. Review.

Sammartino G, Tia M, Bucci T, Wang HL, Prevention of mandibular third molar extraction-associated periodontal defects: a comparative study, J.Periodontol. 2009 Mar; 80(3) 389-96

Sammartino G, Tia M, Gentile E, Marenzi G, Claudio PP, Platelet-rich plasma and resorbable membrane for prevention of periodontal defects after deeply impacted lower third molar extraction, J. Oral Maxillofac Surg. 2009 No; 67 (11) 2369-73

Tai CC, Precious DS, Wood RE. Prophylactic extraction of third molars in cancer patient. Oral Surg Oral Med Oral Pathol, 78(2): 151-5, 1994 Aug .

Van der Schoot EA, Kuitert RB, Van Ginkiel FC, Prahl–Andersen B. Clinical relevance of third permanent molars in relation to crowding after orthodontic treatment. J Dent, 25(2): 167–9, 1997.

Jhamb A, Dolas RS, Pandilwar PK, Mohanty S. Comparative efficacy of spiral computed tomography and orthopantomography in preoperative detection of relation of inferior alveolar neurovascular bundle to the impacted mandibular third molar.J Oral Maxillofac Surg. 2009 Jan;67(1):58-66.

Santamaria J, Arteagoitia I. Radiologic variables of clinical significance in the extraction of impacted mandibular third molars. Oral Surg Oral Med Oral Pat Oral Rad Endodon 84(5):469-79, 1997.

Special precautions should be made to prevent any complications that may occur after surgery and the patient resignation or to take appropriate measures to oppose them in case of their onset.

The presence of pain assumes the prescription of an adequate pharmacological therapy with peripherally and/or centrally painkillers, NSAIDs, opioids and pharmacological associations. It's preferable that taking medicines takes place before the end of the local anesthesia effect and therapy continues for a reasonable number of days in relation to the importance of the intervention, possibly in association with a gastro-protective drug (Classen DC 1992).

Prevention of post-operative edema involves the adoption of low-invasive procedures, a reducd elevation of the flap, a gentle traction of soft tissues during divarication, limited periosteal incisions. It is a good practice to make irrigations of the treated part at the end of the intervention. Treatment with NSAIDs and corticosteroids is indicated in the cases of more invasive surgery (Gersema L 1992) (Graziani F 2006). In the presence of edema, however, the treatment provides for the use of ice packs in the first 24 hours on the operated zone, applied at intervals of 20 minutes associated with the possible administration of enzymatic anti-inflammatory drugs (Haas DA 2002) (Jackson JL 1990).

Trismus prevention can be achieved by reducing surgical times and limiting the detachment of the soft tissues. The treatment, on the other hand, provides a soft and / or semiliquid diet, physiotherapy of chewing muscles and TMJ and anti-inflammatory and muscle relaxant drugs.

The adoption of minimally invasive surgical techniques, where possible, allows prevention of ecchymosis while, in the event of their appearance, it is good to wait for the spontaneous resolution by slow resorption (De Michelis B 1992).

Hemorrhage can be prevented by subperiostal dissection of soft tissues,

their protection from the use of manual and rotating instruments and the patient resignation only after haemostasis control. It is a good practice to perform post-operative compression of the treated site with gauze, for 10 minutes after surgery, and before the patient resignation, check that hemostasis has occurred. Furthermore, appropriate post-operative instructions must be provided to the patient. In case of bleeding, the treatment consists in the compression of the affected area with gauze eventually soaked with anti-haemorragic for 20 minutes, checking the stability of the access flap, while in case of persistent bleeding a new suture is appropriate. If the bleeding cannot be controlled with the indicated measures, the patient should be sent to the nearest hospital (Reich W 2009) (Tonoli A 1985).

Prevention of hematomas is possible with subperiosteal dissection of soft tissues and the careful control of hemostasis before the patient resignation. Soft tissues protection is recommended when there is a risk of penetration by rotating or sharp instruments (AdeyemoWL 2007). If the hematomas occur, these may resorb spontaneously while, if airway obstructions occur, patient hospitalization and an urgent surgical removal of hematoma and the cause of hemorrhage are required. (OsbonDB 1973).

In the presence of acute infection and inflammation, it is necessary to avoid starting an elective surgery. It is good practice to comply with asepsy and sterilization standards, preoperative antibiotic prophylaxis, when indicated, and the use of medicated irrigants to prevent any infections. In the event of their onset, adequate antibiotic therapy is required associated with anti-inflammatory drugs and drainage of any abscess. Hospitalization is indicated in the case of infections invadingloggethe superficial and deep planes and / or lodges and cervical-facial spaces and

which may cause airway obstruction (August M 2003).

Prevention of alveolitis is possible by pre-operative oral hygiene sessions, pre-and post-operative abstention from cigarette smoking, minimum use of vasoconstrictor (Spider JR 1991). It is also advisable, for preventive purposes, curetting and using physiological irrigation at the end of the operation, check the formation of the clot before leaving the patient and prescribe oral antiseptics in the post-operative period. The treatment of alveolitis involves, under anesthesia, the curettage with irrigation of the socket together with the introduction of the antiseptic substances, iodoform gauze (Blum IR 2002) (Chiapasco M 2002). Surgical treatment planning with adequate radiological imaging, the execution of correct incision lines and the subperiosteal dissection allow the prevention of the injury of the nerve trunks (Robinson PP 2004). In the event of their onset, the treatment is variable according to the clinical presentation. In general, steroid therapy associated with vitamin B preparations (Boulox GF 2007) is recommended.

Bibliography

Adeyemo WL, Ladeinde AL, Ogunlewe MO. Influence of trans-operative complications on socket healing following dental extractions. J Contemp Dent Pract. 2007 Jan 1; 8 (1): 52-9.

August M. Complications in oral and maxillofacial surgery. Oral Maxillofac Surg Clin North Am. 2003 May; 15 (2).
Blum IR. Contemporary views on dry socket (alveolar osteitis): a clinical evaluation of standardization, aetiopathogenesis and management: a critical review. Int J Oral Maxillofac Surg. 2002 Jun; 31 (3): 309-17.

Bouloux GF, Steed MB, Penetrating VJ. Complications of third molar surgery. Oral Maxillofac Surg Clin North Am. 2007 Feb; 19 (1): 117-28.

Chiapasco M. Illustrated Manual of Oral Surgery. Masson, 2002.

Classen DC, Evans RS, Pesttnik SL, Horn SD et al .. The timing of the prophylactic administration of antibiotics and the risk of surgical wound infection N Engl J Med 326: 281-6; 1992.

De Michelis B, Modica R., Re .. Treatise of Odontostomatologic Clinic. Ed. Minerva Medica 3 ed. Vol. 1, 1992.
Graziani F, A Help F, Arduino PG, Tonelli M, Gabriele M. Perioperative dexamethasone reduces post-surgical sequelae of wisdom tooth removal. A split-mouth randomized double-masked clinical trial. Int J Oral Maxillofac Surg. 2006 Mar; 35 (3): 241-6.

Gersema L, Baker K. Using corticosteroids in oral surgery. J Oral Maxillofac Surg 50: 270-7; 1992 Haas DA. An update on analgesic for the management of post-operative dental pain. J Canad Dental Assoc 68: 476-82; 2002.

Jackson JL Moore PA, Dionne RA, Hargreaves KM. Compairison of use of nonsteroidal antiinflammatory drugs, ibuprofen and flubiprofen, with methylprednisolone and placebo for acute pain, swelling and trismus following third molar oral surgery. J Ora48: 945-52; 1990

Osbon DB. Postoperative complications following dentoalveolar surgery. Dent Clin North Am. 1973 Jul; 17 (3): 483-504

Spider JR, Szkutnik AJ. Evaluation of Rinse of 12 Chlorexidine Rinse on the Prevention of Alveolar Osteoporosis Oral Surg Oral Med Oral Pathol 72: 524-6;

Reich W, Kriwalsky MS, Wolf HH, Schubert Bleeding complications after oral surgery in outpatients with compromised haemostasis: incidence and management. J. Oral Maxillofac Surg. 2009 Jun; 13 (2): 73.

Robinson PP, Loescher AR, Yates JM, Smith KG. Current management of damage to the inferior alveolar and lingual nerves as a result of removal of third molars. Br J Oral Maxillofac Surg. 2004 Aug;42(4):285-92.

Tonoli A, Arcuri C, Alegiani F. Hemorrhagic complications during oral surgery: prevention and treatment. Dent Cadmos. 1985 Jun 15;53(10):85-8, 91.

The presence of abscess requires a prompt medical and / or surgical treatment.

Abscess is an acute (or chronic) infectious process characterized by a purulent collection located in a newly formed cavity. The acute form presents an impressive symptom with local intense pain, which sometimes radiates to different areas. It tends to drain through the surrounding soft tissue, skin or mucosa, creating a fistula that opens most frequently in the oral cavity, but it can also reach the skin of the face and neck, sometimes giving disfiguring scars when healing occurs (Bucci E 2000). If only medical therapy is not enough, the colliquated abscesses must be surgically treated, so as to favor leakage of the purulent material and, therefore, the decompression of the affected area, resulting in the elimination of pain and increase of local circulation (Daramola OO 2009). The abscess drainage is obtained alternatively with the incision of superficial cutaneous or mucous surfaces or with dental extraction or endodontic therapy (also surgical) or periodontal treatment of the responsible tooth. The incision of an abscess within the oral cavity provides, after an anesthesia for perfrigeration, a minimal mucous membrane incision, in the sloping portion of the swelling, which allows the release of the pus, later favoured by a centripetal manual squeeze. Once obtained the emptying, a review of the newly formed cavity and the antiseptic washings can be performed.

It is therefore possible to insert and leave in situ a medicated gauze or another type of tool useful to ensure the continuity of the drainage and to avoid the closure of surgically opened conduit. This, as long as the wound does not escape more purulent material. An initially empirical antibiotic therapy is performed and then, if there is no adequate response, it’s carried out antibiotic therapy based on antibiogram (Bucci E 2000).

The incision of a skin abscess outside the oral cavity provides, after anesthesia for perfrigeration, minimal skin incision (so-called "stabbing", to minimize the outcomes scarring and to decrease the possibility of meeting nerve endings) in the most part declining swelling (which generally corresponds to a reddish zone and to the zone where palpation appears warmer), which allows the purulent material to escape, subsequently favoured by a manual centripetal squeezing. Obtained emptying, an instrumental revision of the newly formed cavity in the tissues can be performed and washes with antiseptics. Therefore, medicated gauze can be inserted and left in situ, or better, a finger of sterile glove in order to guarantee the patency of drainage and avoid closing the surgically opened conduit until the wound will leak out purulent material. An initially empirical antibiotic therapy is performed and then, if there is no adequate answer, antibiotic therapy is carried out on the basis of the antibiogram (Skucaite N 2009).

Bibliography

Bucci E, di Lauro F. Chirurgia Odontostomatologica. Edizione Florio 2000, Casoria (Napoli).

Daramola OO, Flanagan CE, Maisel RH, Odland RM. Diagnosis and treatment of deep neck space abscesses. Otolaryngol Head Neck Surg. 2009 Jul; 141(1):123-30.

Skucaite N, Peciuliene V, Maciulskiene V. Microbial infection and its control in cases of symptomatic apical periodontitis: a review. Medicina (Kaunas). 2009;45(5):343-50.

In case of acute or chronic odontogenic sinusitis, the cause must be sought and an appropriate medical and/or surgical therapy must be made.

The maxillary sinus could have continuity or contiguity with the roots of some teeth that are the first molar, the third molar, the second molar, the second premolar, the first premolar and the canine (excluding the upper impacted third molar). This situation makes possible the occurrence of an infectious and / or inflammatory sinus disease starting from teeth. However, the inflammatory and / or infectious involvement of the maxillary sinus can occur also after dental extractions, incongruous endodontics, implant surgery and a superinfection of other pathological processes of dental origin. The phlogistic pictures that involve the
maxillary sinus can be acute or chronic and their treatment requires adequate
anamnestic evaluation (to detect the presence of apical periodontitis in the area of interest or a previous dental extraction or a previous root canal treatment or a dental implant placement). With the clinical examination the presence of a necrotic tooth in the posterior region, the site of a previous extraction, a unilateral rhinorrhea and the pain exacerbation at the compressive palpation of the
canine fossa must be sought. The anamnesis must be accompanied by some instrumental examinations. These can be Rx orthopantomography (OPT), x-ray of the nasal and paranasal sinuses, axial computerized tomography (CT/ CBCT) (Bucci E 2000) (De Michelis B 1992).
The treatment of acute forms is mainly medical and is based on the use of antibiotics for 7-10 days. of anti-inflammatories, cortisone and / or via y aerosol therapy (Bailey J 2009). The therapy of chronic forms, which do not require a surgical solution, is based on the use of antibiotics, immunostimulants, antihistamines, corticosteroids sprays for topical use, nasal washes with hydrosaline solutions, inhalation therapies with drugs or thermal waters. Acute and subacute odontogenic sinusitis resistant to medical therapy need further investigations that may require the advice of an otolaryngologist and/or a maxillofacial surgeon. Sometimes it needs for an intervention in association between the aforementioned specialists and the oral surgeon, with endoscopic treatment of the sinus, (Andric M2010) simultaneously with the closure of the oro-antral fistula by the oral surgeon.

Maxillary sinus therapy should be associated with etiologic therapy consisting in the treatment of the cause that determined sinusitis (endosinusal foreign bodies, apical periodontitis, suprainfections of odontogenic pathologies with endosinusal development, iatrogenic causes ...).

The presence of an oro-antral communication can be treated immediately or followed in its clinical evolution with adequate follow-up.

The oro-antral communication is a pathological opening between the oral cavity and the maxillary sinus of varying aetiology, which, if left untreated, could lead to the formation of an oro-antral fistula, consisting of an epithelialised conduit, frequently associated with inflammation of the sinus mucosal. It is necessary distinguish if the communication is with or without interruption of the sinus membrane by using the Valsalva maneuver; in fact, if the membrane is intact and does not let air through, it can be sufficient to wait for the stabilization of the clot and the recommendation to the patient not to mechanically sneeze blocking the nasal passages and avoid blowing his nose for a period of at least two weeks. On the other hand, if the communication is "frank", it can be treated by means of the osteoplasty, the tissue apposition and the suture. Site protection with an appropriate resin plate can sometimes be useful to allow the protected tissues to heal spontaneously. In the case of an oro-antral fistula, the surgical treatment is preceded and followed from an antibiotic, anti-inflammatory and mucolytic treatment that can be both systemic and topical through aerosols. Surgical therapy involves the use of appropriate flaps depending on the size and the position of the fistula (Visscher SH 2010).
The most commonly used flaps are those trapezoidal rolling vestibular or those Rolling from the palate; both provide for the removal of the epithelium and a closure in excess that reduces the chances of reopening (De Michelis B 1992). Other flaps are also foreseen, such as the double lining, which uses the same epithelium that covers the fistulous conduit without removal. When chronic or subacute sinusitis is present for inveterate fistulas the surgical revision of the maxillary sinus is required with appropriate medical support therapy, in as in these cases, any technique tending only to close the fistula would not be able to be decisive. The simultaneous use of resorbable membranes or autologous bone grafts may be planned.

Bibliography

Andric M, Saranovic V, Drazic R, Brkovic B, Todorovic L. Functional endoscopic sinus surgery as an adjunctive treatment for closure of oroantral fistulae: a retrospective analysis .Oral Surg Oral Med Oral Pathol Oral Radiol Endod. 2010.

Bailey J, Change J. Antibiotics for acute maxillary sinusitis.Am Fam Physician. 2009 May 1;79(9):757-8.

Bucci E, di Lauro F. Chirurgia Odontostomatologica. Edizione Florio 2000, Casoria (Napoli)

De Michelis B, Modica R., Re G.. Trattato di Clinica Odontostomatologica. Ed. Minerva Medica 3^ ed. Vol. 1, 1992.

In oral surgery it is necessary to take into consideration the factors that can negatively influence the healing of tissues.

Repairing or healing processes put in place by the body in the presence of surgical or accidental wounds consist in the formation of new connective tissue, result of the evolution of the granulation tissue in scar tissue. There are several factors that can negatively influence the healing processes: general factors such as systemic infections, debilitating diseases, malignant tumors, steroid therapy, altered immune response and local factors like foreign material, necrotic tissue, tension and flap ischemia, infection.

The suture thread must have ideal biomechanical characteristics, in relation to the easy handling, biocompatibility and the ability to retain over time resistance to voltage. The needles to be used are atraumatic ones.

The type of suture depends on the type of wound (oral surgical wounds can be caused by sharp, tear and they can be torn-bruised, with or without loss of substance), but in all, it is of practical cleansing and disinfection of the wound with antiseptic solutions and hemostasis when present a vascular gemizio. In the sharp wound, a suture with single stitches is preferred, starting from center and then extend to the two sides until a complete confrontation of the margins. In the wound from tearing or lacerated-bruised wound without loss of substance is, however, important to regularize the margins to reconstruct as much as possible the original architecture. In lacerated-bruised wounds with loss of substance it is desirable to limit as much as possible, the second intention healing with the suture (Artandi C 1988) (Boltri F 1989) (Bonardini L 1989).

Bibliography

Artandi C, Gallini G, Pasqualini M. Suture in oral surgery. Att Dent, IV (20): 18-22, 1988.

Boltri F. The sutures, in: Treaty of surgical technique, vol 1, Utet, Turin 1989.

Bonardini L, Rosato S. Suture and surgical threads, Edizioni Mediche Italiane, 1989.

In the presence of an impacted teeth, beyond the physiological limits for his eruption or with difficulty of spontaneous eruption due to unfavorable position of the root, the elective treatment is to guide the tooth in the arch, after surgical exposure.

Before surgical procedure, a careful preoperative evaluation with radiographic examinations is a good rule. They are indispensable for defining the position of the impacted tooth, the presence of local complications (cysts, root resorption ...). They have to make according to the clinical findings, in a personalized manner and in increasing order of diagnostic investigation: intraoral Rx OPT, lateral teleradiography of the head, intraoral occlusal Rx, CBCT with three-dimensional reconstruction (Jacobs SG 1999) (Manerva R 2007). Objective of the surgery is to expose the crown to apply the anchoring tools necessary for orthodontic traction.

There are two techniques: the open sky technique and covered technique. In the first one the tooth is exposed to the oral environment with removal of covering mucosa or / and bone. It can be performed with: 1) operculum, useful in teeth placed superficially in palatine seat rich in adherent gingiva, in cases where the impacted tooth is superficial and distant from the mucogingival line; 2) apically positioned flap, method indicated in the elements placed vestibularly, near the mucogingival line, which ensures correct coverage of adherent gingiva (SIdCO 2015).

With the technique of covered erupting, after exposure and placement of the traction device, the soft tissues are repositioned at the initial site and sutured. The tool of traction emerges from incision and dental movements, which cannot be clinically evaluated, must be monitored radiographically. The tooth is guided into the arch through the adherent gingiva as in the normal eruptions.

Both techniques require an infiltration anesthesia (local or nerve block anesthesia), depending on the element position. Dental ectopy may require some modification of the anesthetic technique considering the dislocation of the dental apex and of the neurovascular bundle.

The design of the access flap will be related to the chosen surgical technique and to the tooth location. After the flap elevation, of adequate size according to the operative field, the crown can be identified as mucosal or osseous inclusion; in the first case, after the incision, the detachment is carried out exposing the crown. If, instead, there is a bone inclusion, the dental crown is located and the removal of the bone that covers it with rotating or manual instruments is carried out. It is good to start from the most superficial portion, without damaging the enamel and in compliance with adjacent structures. The exposure of the crown must respect the dental follicle without extending beyond the cemento-enamel junction, so that this, during the eruption, unites to the epithelium of the oral mucosa (Bucci E 2000). After application of orthodontic traction and at the end of the intervention, the suture must be performed to place the flap and allow the traction wire to pass without traumatizing the tissues. In the covered technique the suspended suture allows a correct adaptation of the vestibular flap. For the palatine flap single sutures are recommended. The apically positioned flap is sutured apical to the orthodontic bracket with resorbable periosteal sutures.

Bibliography

Bucci E, di Lauro F. Chirurgia Odontostomatologica. Edizione Florio 2000, Casoria (Napoli)

Jacobs SG. Localization of the unerupted maxillary canine: how to and when to.Am J Othod Dentofacial Orthop 1999;3:314-22.

Manerva R, Gracco A. Different Diagnostic Tools for the localization of impacted maxillary canines: clinical considerations. Prog Orthod 2007;1:28-44.

SIdCO, Società Italiana di Chirurgia Odontostomatologica, Chirurgia Odontostomatologica, Edizioni Minerva Medica, 2015.

In the presence of frenulum, the orthodontic, periodontal, prosthetic and aesthetic indications for the surgical intervention can be evaluated.

The frenulum is defined as a fibro-mucous plica that connects the cheeks, lips or tongue to alveolar mucosa, lacking of muscular tissue. There are two median frenuli (upper and lower), four vestibular lateral located at the level of the premolars (two upper and two lower) and one lingual. The upper median frenulum is considered abnormal when it has a papillary connection (it is inserted on the vestibular side of the interincisive papilla) and when it has a trans-papillary connection (the frenulum crosses the interincisive papilla and fits on the palatine side) (Adiaz-Pisan 2006).

Surgery may be the frenulotomy (frenulum resection) or the frenulectomy (complete removal of the frenulum). The surgical technique involves the execution of two incisions in correspondence of the insertion bases. Single sutures of the upper portion only, provides for the closure of the flap in the alveolar mucosa, while the portion of the wound in the adherent gingiva is left to heal by secondary intention. It can also be performed zeta-plastic surgery, less commonly used but described in the literature.

The lower median frenulum starts from the inner surface of the lip up to the lower alveolar process with insertion to the interincisive papilla. In case of indications to surgery, which may be periodontal and prosthetic, the most used surgical technique is the frenulotomy with incision at the alveolar side of the frenulum and healing for second intention (Mozzati M 2008).

The interventions of frenulotomy and frenulectomy can be performed with alternative techniques and tools (electrosurgical units and laser scalpels), according to the clinician.

The lingual frenulum is defined as pathological when its insertion is located near the tongue apex reducing mobility. The indications for intervention are orthodontic, phoniatric, prosthetic, periodontal (Kloclars T 2007) (Powell RN 1982). The surgical technique provides the removal of the frenulum very carefully to the respect of the numerous anatomical structures present on the mouth floor, (Wharton and Rivino - Bartolino ducts, sublingual caruncles, sublingual venous plexus).

After infiltration of local anesthesia in the paramedian site in the oral floor, the frenulum is clamped with an hemostatic forceps and a horizontal incision is made perpendicular to the frenulum. The scalpel blade is kept in contact with the hemostatic forceps and is slipped up to sublingual plica. With scissors, we proceed to the dissection of the submucosal fibers, then the wound margins are sutured with absorbable and single sutures. The effects of the intervention
are evaluated through tongue mobility (Segal LM 2007).

Bibliography

ADiaz-Pisan et al. Midline diastema and frenum morphology in the primary dentition. J Dent Chil. 2006; 73(1): 11-4.

Klockars T. Familial Anchiloglossia (tongue tie). Int J Ped Othorinolaringol 2007; 7:1321-4.

Mozzati et al. Chirurgia Stomatologica biologicamente guidata. Metodiche e tecniche operatorie Vol 4 UTET, Torino 2008.

Powell RN, McEniery TM. A longitudinal study of isolated gingival recession in the mandibular central incisor region of children aged 6-8 years. J Clinical Periodontol 1982; 9(5): 357-64.

Segal LM, Stephenson R, Dawes M et al. Prevalence, diagnosis and treatment of ankiloglossia: methodological review. Ca. Fam Physician 2007; 53(6): 1027-33.

Dental trauma must always be considered a condition of emergency and be treated immediately in order to relieve pain, facilitate the reduction of dislocated teeth, improve the prognosis.

Often in dento-alveolar traumas there is involvement of the cutaneous and mucosal soft tissues (lips, gingival mucosa, frenuli, more rarely tongue). You can have bruises, abrasions, lacerations, penetrating lesions.

Hard dental tissues traumas (according to WHO) consist of coronal infractions (presence of micro fractures or fracture lines), simple coronal fractures (only the enamel is involved as in the incisors borders), uncomplicated coronal fractures (with involvement of the enamel and dentin without pulpal exposure), complicated coronal fractures (with exposure of the pulp), uncomplicated corono-radicular fractures (the trauma affects both the crown and the root without pulp exposure), complicated corono-radicular fractures (the trauma affects the crown and the root with pulp involvement), root fractures (the trauma affects the root of the tooth with fracture of the apical third, of the middle third and of the coronal third).

The traumas of the supporting tissues are: concussion, subluxation, extrusive luxations, dislocations, intrusive luxations, traumatic avulsions.

In the concussion and subluxation there is a slight mobility, sometimes pain or percussion at the simple pressure. In the intrusive dislocation, the tooth goes back into the alveolar process and fractures it. In extrusive luxation there is a partial release of an element from its socket. The lateral luxations are similar to vertical dislocations, but vertical displacement is combined with a lateral displacement. In the avulsion the element moves away from the natural sockets.

Lesions involving bone tissue may consist of a comminuted alveolus fracture

(crushing with compression of the alveolar bone; this situation is associated with the

lateral dislocation and intrusive dislocation); fracture of the socket wall (limited to the vestibular or lingual wall); fracture of the alveolar process (which may or may not involve the alveolus); fracture of the jaw (affects the base of the jaw or maxillary and often alveolar processes; the fracture can affect the alveolus or not) (Dewhurst SN 1998) (De Rossi M 2009).

The diagnosis of the above mentioned conditions includes a clinical examination consisting of evaluation and palpation of the traumatized tissues, in the control of the oral cavity with search for foreign bodies, in the control of any dental mobility in the sagittal and vertical sense, in the relief of abnormalities in the occlusion. Vitality tests and dental reaction must be associated: after the trauma a temporary absence of viability can occur due to post-traumatic shock of the neurovascular bundle; the test must be repeated periodically, which could return positive even after 5-6 months. Important, then, is the radiographic evaluation through the use of intraoral rx, occlusal or iuxtagengival Rx or the orthopantomography. Two radiographic projections are always recommended. The CT cone beam allows to highlight fracture lines on the alveolar bone in the areas of the interdental area not detected with traditional Rx. If inhalation of foreign body is suspected, it is recommended to perform a chest X-ray (Semanur D 2009) (Ceallaigh PO 2007).

The therapy involves the cleansing with physiological solution of the wounds of the traumatized oral mucosa, disinfection, research of foreign bodies and bone fragments and their removal, bleeding control and soft tissue suture. It is also necessary to verify the presence or absence of tetanus coverage.

The presence of simple coronal fractures involves smoothing of the interested area

; in the case of coronal fractures, instead, we proceed to reconstruction with aesthetic materials or to the eventual reattachment of the fractured fragment after rehydration; if the fracture is not complicated we protect dentin with calcium hydroxide, if it is complicated, endodontic therapy is necessary. In the presence of uncomplicated corono-radicular fractures is the same as for uncomplicated coronal fractures; complicated corono-root fractures are treated like root fractures; in the root fractures without necrosis the dental fragments are fixed for 3 weeks until

2 months; in the case of root fractures with necrosis, root canal therapy is performed. In the presence of concussion no therapy is performed, often the trauma remains unknown; in subluxations when we have

a periodontal lesion with dental mobility, we must devitalize the tooth; in the intrusive luxations the dental element frequently erupts again spontaneously in the arch, alternatively an orthodontic guide is necessary. In the event of dislocations the tooth is repositioned in the socket, preferably within 48 hours of the trauma, proceeding with splinting for 2-4 weeks and a possible endodontic therapy if there is root resorption or loss of vitality; traumatic avulsions require replacing techniques, where possible (American
Academy of Pediatric Dentistry Council on Clinical Affairs, 2008-2009) (Andreasen JO 1995, 2007) (Ferrazzano GF 2010).

In clinical cases with a bone involvement, the alveolar structure and the teeth in it must be manually repositioned in correct alignment with splinting (Oikarinen K 1990), which must be maintained for 4-8 weeks; loss of marginal bone support, common situation in the event of a broken alveolar bone wall, may require reconstructive surgery with grafts.

Bibliography

American Academy on Pediatric Dentistry Council on Clinical Affairs. Guideline on management of acute dental trauma. Pediatr Dent 2008-2009;30:175-183.

Andreasen JO, Andreasen FM, Andersson L. Textbook and color atlas of traumatic injuries to the teeth. 4th ed. Oxford: Blackwell; 2007.

Andreasen JO, Borum M. Replantation of 400 avulsed permanent incisors. Endod Dent Traumatol 1995; 11:51-58.

Ceallaigh Po et al. Diagnosis and Management of common maxillofacial injuries in the emergency department. Part 5 Dentoalveolar injuries.2007 24:429-430.

Dewhurst SN, Mason C, Roberts GJ. Emergency treatment of oral dental injures: a review. British J Maxillofacial Surg 1998;36:165-175.
Ferrazzano GF, Orlando S, Ingenito A, Tia M, Sammartino G, Tooth replantation as an alternative to dental implantology in adolescent patients, Eur J of Paediatr Dent, 2010 Dec; 11(4):216-8

Moara De Rossi, Andiara De Rossi et al. Management of a complex dentoalveolar Trauma.Braz.Dent J 2009,20(3):259-262.

Oikarinen K. Tooth splinting: a review of the literature and consideration of the versatility of a wire-composite splint. End Dent Traumatol 1990; 6:237-250.

Semanur DoleKoglu et al. Diagnosis of Jaw and dentoalveolar fractures in a traumatizated patient with cone beam computed tomography. Dental Traumatol Oct, 2009

In some patients the preprosthetic surgery is indicated in order to create a proper osteo-mucosal morphology and adequate structural support for the subsequent positioning of a mobile prosthesis.

In the case of multiple tooth extractions, the affected crest must be regularized. If the regularization of the extraction sites is carried out at different times with respect to the extractions, after local anesthesia, a mucoperiosteal incision is made at the apex of the edentulous ridge with opening of an access flap, possibly drawn with releasing incisions.

The access to the ridge allows the regularization of the bone tissue with appropriate drills under abundant irrigation. The flap is then sutured with single stitches or continuous sutures.

In case of bony prominences (exostoses, "tori") local anesthesia is made

surrounding the intervention area (Pynn BR 1995). The mucoperiosteal incision should be performed distant from bony prominence. If the area of intervention is not well displayed, two releasing incisions must be done. When the prominence is small, remodeling can be carried out with bone files or raspes; when, instead, the bony protuberance is greater the use of rotating instruments under abundant irrigation is possible. Once the bone remodeling has been performed, a palpation should be performed to evaluate if superficial irregularities persist. In case of an excess of the above soft tissues it is necessary for their partial removal. The flap is sutured with single stitches or with continuous suture. In the presence of mucosal hypertrophy not supported by bone, after performing local anesthesia, the surgical excision of the mobile tissue and a single or continuous suture are performed.

Surgery is also recommended for the elimination of fibrous hyperplasia. Small lesions can also heal by secondary intention. In the case of large tissue excisions, it is necessary to cover the exposed area with mucosal or cutaneous grafts or with rolling flaps (Brusati R 1999). An histological analysis is required to exclude the presence of neoplastic tissue (Brusati R 1985).

If the alveolar process is resorbed with consequent superficialization of the muscle insertions, the deepening of fornix is indicated. After local anesthesia, a mucosal incision at the junction between the adherent and non-adherent mucosa is made, without involving the periosteum. A supra-periosteal dissection is performed by using a blade, detaching the muscle fibers from the periosteum. The dissection is completed by the fixation of the soft tissues to the periosteum, more apically, with resorbable suture.

The area may be left to heal by secondary intention or may be covered by a mucosal grafting.

Bibliography

Brusati R, Chiapasco M. Elementi di chirurgia oro-maxillo-facciale. Masson, Milano p. 73; 1999.

Brusati R. Attuali orientamenti in chirurgia pre-protesica maggiori. Dental Cadmos 4: 9-47; 1985.

Pynn BR, Kurys-kos NS., Walker DA, Mayhall JT. Tori mandibularis: a case report and review of the literature. J Can Dent Assoc1995; 61(12): 1057-8.

The finding of a root cystic lesion in the maxillary bone requires a careful diagnosis and a careful assessment of the type of surgical or endodontic treatment to be followed.

The maxillary cysts are predominantly endosseous neoformations of the maxillary bone with predominantly fluid content, consisting of a multi-layered epithelial wall and coated with a fibro-connective capsule. They have different origins and, once have been found, it needs a careful clinical examination to evaluate the condition of the mucous membranes and of the teeth surrounding the lesion. In the case of odontogenic cysts, it is necessary to highlight caries or pulpits or compromised teeth. Pulp vitality tests should be performed for the involved teeth. The diagnosis of cystic lesions also passes through radiographic examinations. The OPT allows to highlight the lesion as a whole; provides the location and the information about relationships with important anatomical structures. For more details, such as the evaluation of the thickness of the cortical is recommended to carry out the CT scan dentascan or CT cone beam (Neyaz Z 2008) (Lizio G 2013) (Soumalain A 2009).

Once a diagnosis has been made, (Motta A 1990), the treatment consists of cystectomy or Partsch II surgery which involves the enucleation of the entire cyst wall or in cystotomy or Partsch I or marsupialization that involves the opening of the cystic cavity in the oral cavity, as the cystic cavity becomes an accessory cavity of the oral cavity; a previous incisional biopsy in large cysts can be provided (Castro-Nunez J 2016) (Matijevic S 2015) (Motamedi MHK 2005).

Cystectomy is performed in all cystic lesions in the absence of loco-regional conditions that do not indicate cystotomy. The latter, on the other hand, have to be preferred in deciduous or mixed dentition, when the germs of permanent teeth are involved or when, in the presence of a follicular cyst, it is decided recovering of the responsible tooth or in very old or compromised patients, where it is not indicated a radical intervention or when, due to the exceptional size of the cystic lesion, there is the real risk of intra or post-operative mandibular fracture and as a preliminary step of the subsequent cystectomy.

About cystectomy, the therapeutic objective is the enucleation of the entire cyst wall, the best one possible rehabilitation of the functionality and / or morphology of the region subjected to intervention with the healing by organization and ossification of the clot inside the residual cavity. The intervention is preceded by a local anesthesia of adequate extension and duration, or general, in relation to the extension of the cystic lesion, to the operating difficulty, to the risks of intraoperative complications and patient compliance. In the presence of teeth involved in the lesion, these can be treated endodontically in a preventive way or monitored after the operation for at least two months for their vitality (Caliskan MK 2004). So, under adequate antibiotic coverage, we proceed to the complete enucleation of the cyst wall with maintenance of the integrity

of the surrounding structures (nasal mucosa and maxillary sinus, nerves and vessels). Where necessary, the apicectomy of the involved and responsible teeth is performed (if they are an obstacle to the cyst enucleation) with intra-operative endodontic closure of the latter and retrograde obturation or extraction of the involved teeth that can not be performed stored for preoperative bone support deficiency or following surgery. The cystic wall removed is fixed in formalin at 10% for histological examination (Slootweg PJ 2009). The intervention yes concludes with the complete covering of the surgical area. The prognostic aspects of cystectomy they are the healing of the cavity consequent to the enucleation of the cyst, with minimal defect of the residual bone, larger in case of large cystic lesions involving both cortices both vestibular and oral; maintaining the vitality and stability of the involved teeth, not endodontically treated in the pre-operative phase and stable before the operation; follow-up up to complete normalization of the clinical-radiographic picture.

With cystotomy, an operculum is created in the cyst wall which places the lesion in communication with the oral cavity; the patency of communication is maintained until healing occurs to obtain the centripetal bone apposition, with progressive reduction until the disappearance of the cyst. The intervention involves local anesthesia, of extension and adequate duration, and the opening of the cystic cavity by extraction of overlying deciduous teeth or incision of soft tissue and possible osteotomy. Thus, an acrylic resin obturator is manufactured and applied which acts as a space maintainer in case of early extraction of deciduous teeth. The residual cavity should be carefully cleaned as well as the obturator. The prognostic aspects of cystotomy are the healing with absence of any residual bone defects; spontaneously repositioning of the germs eventually displaced by the cyst; the eruption of the responsible tooth, in case of follicle cyst; follow-up up to complete normalization of the clinic-radiographic picture.

Bibliography

Caliskan MK. Prognosis of large cysts-like periapical lesions following nonsurgical root canal treatment: a clinical review. Intl Endod Jl 2004, Jun; 37(6):408-16.

Castro-Nunez J, Decompression of Odontogenic Cystic Lesions: Past, Present and Future, J Oral Maxillofac Surg, 2016 Jan;74(1):104

Lizio G, Sterrantino AF, Ragazzini S, Marchetti C, Volume Reduction of Cystic Lesions after Surgical Decompression: a Computerised Three-Dimensional Computed Tomographic Evaluation, Clin Oral Investig, 2013 Sep;17(7):1701-8

Matijevic S, Jovicic B, Bubalo M, Dukic S, Cutovic T, Treatment of a large radicular cyst - enucleation or decompression?, Vojnosanit Pregl, 2015; 72 (4):372-374

Motamedi MHK, Talesh KT. Management of extensive dentigerous cysts. Brit Dent J 2005 feb; 198(4):203-6.

Motta A, Lo Bianco A, Arecuri C, Cystotomia. Preliminary Surgery for a Voluminous Cyst, Dent Cadmos, 1990 Oct 15;58(15):90-6

Neyaz Z, Gadolia A, Gamanagatti S, Mukhopadhyay S. Radiographical approach to jaw lesion. Singapore Med J 2008 Feb; 49(2):165-76.

Slootweg PJ. Lesions of the jaws. Histopathology, 2009, Mar; 54(4):401-18.

Soumalain A, Apajalahti S, Kuhlefelt M, Hagstrom J. Simple bone cyst: a radiological dilemma. Dentomaxillofac Radiol 2009 Mar; 38(3):174-7.

In the presence of neoformations of the oral cavity, decision-making factors that may influence their removal are: the type of neoformation (in relation to its histological characteristics and epidemiology regarding the percentage of recurrence after conservative treatment), location, size, involvement of adjacent structures (e.g. neurovascular bundles, maxillary sinus, nasal cavities) and the type of development (central vs. peripheral).

Benign neoplasms of soft tissues are hyperplastic / hypertrophic volumetric increases or benign tumor (slow and unlimited growth, absence of lymph node and distance metastasis, absence of vascular and nervous infiltration, moderate peripheral delimitation) that affect the mucosa or / and submucosa (muscular, adipose, glandular, vascular and nervous tissues) (Barnes L 2005).

Benign neoformations of the maxillary bones are hyperplastic / hypertrophic volumetric increases, dysplastic (self-limiting growth, absence of peripheral delimitation) or benign tumor (slow and unlimited growth, absence of lymph node and distant metastasis, absence of vascular and nervous infiltration, moderate peripheral delimitation) affecting the bone tissue of the jaw, with predominantly / exclusively extraosseous development (peripheral development) or predominantly / exclusively endosseous development (central development) or

with equivalent extra and endosseous involvement. The origin of neoformations is bone, vascular, nervous or more frequently odontogenic, starting from the embryonic teeth tissues. In the latter case they may be of a mesenchymal, ectodermal or mixed nature, may or may not contain more or less morpho-differentiated and mineralized material and may show a variable degree of infiltration of the adjacent healthy bone tissue.

Surgical treatment of the above mentioned neoplasms includes enucleation and / or curettage which consists in the removal of the neoformation of soft or hard tissues with total preservation of clinically healthy surrounding tissues and / or eventual subsequent removal of 1-2 mm of peri-lesional tissue; excision or removal of the new soft tissue formation including a variable amount of clinically healthy surrounding tissue; resection or removal of neoformation of the maxillary or mandible bones, with central, peripheral or mixed development, comprising a variable degree of clinically healthy bone tissue (0.5-1 cm).

In the field of resection, we can distinguish a marginal resection that consists in the removal of the lesion without interruption of the continuity of the affected bone segment; the partial resection which

provides for the removal of the lesion with interruption of the continuity of the interested bone segment (in the mandible, from a small residual bone defect to a hemimandibulectomy); finally, the total resection with the removal of the lesion together with the whole affected bone (maxillectomy, mandibulectomy).

These surgical techniques aim the eradication of the neoformation, the healing by first intention, when possible,by complete covering of the surgical area with tissue and the preparation of the intervention area to the best functional and aesthetic rehabilitation.

Enucleation surgery is indicated for maxillary cysts and soft tissue neoplasms (eg lipomas, mucocele / retention cysts, pleomorphic adenomas of the minor salivary glands located in non-adherent mucosa) (Mortellaro C 2008).

The surgical technique provides:

- peri-lesional anesthesia with vasoconstrictor;
- longitudinal incision of the mucosa overlying the neoformation;
- removal of the newly formed neoformation;
- regularization of excess mucosa;
- suture;
- fixation of the sample in 10% buffered formalin;
- compilation of a detailed information sheet for the pathologist.

Enucleation with curettage is indicated for non-recurrent or odontogenic tumors,
odontogenic unicistic tumors at low risk of relapse (keratocystic odontogenic tumor,
complex or compound odontoma, cementoblastoma, odontogenic fibroma, and any other tumor that allow a conservative surgical approach in the first instance) (Sammartino G 2006). The indications for this type of treatment may also include non-odontogenic tumors with bone involvement such as cemento-ossifying fibroma, osteoma, giant cell granuloma, endosseous hemangiomas and eosinophilic granuloma.

The surgical technique provides:

- preventive endodontic treatment of the involved teeth, that can be preserved;
- local anesthesia, of adequate extension and duration, or general, in relation to the extension of the neoformation, to the operating difficulty, to the risks of intra-operative complications and to the patient compliance;
- antibiotic prophylaxis;

- complete removal of the neoformation, with maintenance of the integrity of the surrounding structures (nasal mucosa and sinus cavity, nerves and vessels);
- eventual apicoectomy or extraction of the involved teeth, when not maintained due to pre-operative or postoperative bone support deficit;
- fixation of 10% formalin surgery for histological examination;
- reconstitution of the continuity of the bone segment if it has been interrupted;
- complete covering of the surgical area;
- compilation of a detailed information sheet for the pathologist.

Excision surgery is indicated for the removal of fibromas, papillomas /warts, soft tissue hemangiomas, inflammatory and traumatic hyperplasia / hypertrophy. Other clinical indications are represented by ameloblastoma, mixoma and relapses of other neoformations previously treated with conservative techniques (Sammartino G 2006). In these cases, therefore, the excisional intervention is represented by a partial or marginal resection (Pogrel MA 2009) (Sachs SA 2006)

The surgical technique provides:

- peri-lesional anesthesia with vasoconstrictor;
- orientation of the neoformation to be subjected to sampling;
- stabilization of the intervention area;
- incision of the oral mucosa with an elliptic surface and a cuneiform section: . on the minor axis and on each side of the lesion, extension of about 2-3 mm in clinically healthy tissue, with a similar extension in depth and below the lesion; 2 to 3 times extension on the major axis respect to the minor one, in relation to the needs of the suture;
- multilayered suture, in case of involvement of the submucosa or / and for aesthetic / functional reasons; not necessary in adherent gingiva (second intention healing with surgical pack or / and protective mask);
- fixation of the sample in 10% buffered formalin;
- compilation of a detailed information sheet for the pathologist.

Prognostic factors for the soft tissue neoformations are the absence of peripherals margin infiltration of clinically healthy tissue; the good healing of the surgical wound with minimal aesthetic or / and functional defects; the continuous clinical follow-up and supportive exams (TC, RMN) 6 months after.
For the neoformation of the maxillary bone, the healing is a prognostic factor consequent to the removal of the neoformation with residual bone defect, wider in the case of involvement of both

corticals, vestibular and oral; maintaining vitality and stability of the involved teeth, not endodontically treated in the pre-operative phase and stable before intervention; the semiannual follow-up up to the complete normalization of the clinical and radiographical picture and then biannual, or sometimes protracted up to ten years after the operation in the case of injuries at risk of recurrence. In cases of large injuries of the maxillary bone and not easily diagnosed, a first biopsy may be indicated to evaluate the lesion and then establish a more or less radical approach of the intervention (diagnostic doubts among odontogenic cysts and keratocysts and / or unicistic ameloblastomas.

Bibliography

Barnes L, Eveson JW, Reichart P, Sindransky D. World Health Classification of Tumours. Parthology and Genetics. Head and Neck Tumours. International Agency for Research on Cancer (IARC) Press, Lyon 2005.

Mortellaro C, Dall'Oca S, Lucchina AG, Castiglia A, Farronato G, Fenini E, Marenzi G, Trosino O, Cafiero C, Sammartino G, Sublingual Ranula: A closer look to its surgical management, J Craniofac Surg, 2008, Jan;19(1):286-90

Pogrel MA, Montes DM. Is there a role for enucleation in the management of ameloblastoma? Int. J. Oral Maxillofac. Surg. 2009; 38: 807–812.

Sachs SA. Surgical Excision With Peripheral Ostectomy: A definitive, yet conservative, approach to the surgical management of ameloblastoma. J Oral Maxillofacial Surg 2006; 64:476-83.

Sammartino G, Zarrelli C, Urciuolo V, Di Lauro AE, Di Lauro F, Santarelli A, Giannone N, Lo Muzio L, Brit J Oral Maxillofac Surg, 2007, Jun ;45(4) :306-10

The presence of salivary calculi in the anterior two thirds of the duct (in front of the lower first molar in the case of the submandibular gland), in the absence of sever impairment of the glandular parenchyma, provides a conservative surgical approach. Instead, in presence of parenchymal compromise it is necessary the transcutaneous exeresis of the whole interested gland.

Salivary calculi (sialoliths) are concretions consisting of calcium salts and organic substances, located more frequently in the ductal system of the major salivary glands, in particular of the submandibular and rarely parotid glands (Fusconi M 2016). The clinical picture more
Frequently associated with the presence of salivary calculi is that of salivary colic
causing acute pain localized to the affected gland, which also appears swollen; the colic is caused by the spastic contraction induced by intraluminal obstruction, usually starting at the pre-prandial, on the occasion of an increased functional request. For the presence of intraductal stones, a sialoadenitis or an inflammation of the salivary gland consequent to the ascending infection of the glandular parenchyma may occur, more often chronic, sometimes acute.

Objectives of the surgical treatment of sialolithiasis in the absence of parenchymal impairment are the complete removal of all the present intraductal calculi, to prevent the posterior dislocation of the calculus or its fragments within the duct, the creation of a neostoma at level of the surgical incision of the mucosa and the duct
and the maintenance of the neostoma patency over time (Combes J 2009) (Baurmash HD 2004).
Surgery requires a diagnostic evaluation based on a positive history for
pre-prandial salivary colic; a clinical examination with palpation of the calculi by combined extra and intraoral maneuvers; inferior occlusal rx (in the case of submandibular gland calculati) using exposure times of 50-75% lower than standard, with sialography of the affected gland (alternatively or as integrative examination to the ultrasound) and with ultrasound when it is necessary to visualize the glandular parenchyma and the presence of intraglandular concretions and of the posterior third of the duct (Kim JH 2016).
The removal of salivary calculi is always surgical, except in the case of calculi of 1-2 mm in diameter that can sometimes be removed with the use of substances improving the salivation associated with the expansion of the ductal papilla by retrograde cannulation.

The intervention includes:

- local anesthesia with vasoconstrictor;
- application of a suture posterior to the calculus, so as to determine a non-stenosis constriction of the duct and preventing the posterior dislocation of the calculus during the subsequent surgery phases;
- incision of the oral mucosa and of the underlying ductal wall in correspondence with the calculus;
- removal of all the concretions present;
- combined bimanual squeezing of the glandular body after removal of the suture;
- suture of the edges of the mucosal incision to the corresponding flaps of the ductal incision;
- possible insertion and suturing in place (for 2 - 3 days) of a medicated gauze or a
- tube of plastic material, for about 1 cm inside the portion of the duct posterior to the neostoma (4,%).

Prognostic factors are the disappearance of the symptomatology, the outflow of the saliva from the neostoma, an annual follow-up, to verify the patency of the neostoma over time.

Bibliography

Baurmash Harold D. Submandibular Salivary Stones: Current Management Modalities. J Oral Maxillofacial Surg 2004; 62:369-78.

Combes J, Karavidas K, McGurk M. Intraoral removal of proximal submandibular stones – an alternative to sialadenectomy Int J Oral Maxillofac Surg 2009; 38:813–6.

Fusconi M, Petrozza V, Schippa S, de Vincentiis M, Familiari G, Pantanella F, Cirenza M, Iebba V, Battaglione E, Greco A, Gallipoli C, Campo F, Gallo A, Bacterial Biofilm in Salivary Gland Stones: Cause or Consequence?, Otolaryngol Head Neck Surg, 2016 Mar;154(3):449-53

Kim JH, Aoki EM, Cortes AR, Abdala-Junior R, Asaumi J, Arita ES, Comparison of the diagnostic performance of panoramic and occlusal radiographs in detecting submandibular sialoliths, Imaging Sci Dent, 2016 Jun;46(2):87.92

The oral surgeon come into contact with a series of patients suffering from systemic diseases and for which, the surgery, even if trivial, can be defined "at risk", both for the characteristics of the systemic diseases themselves, both for the therapies.

The close collaboration between the oral surgeon and the primary physician, basic or specialist, is fundamental.

In general, patients "at risk" should be treated in the simplest and a-traumatic way, choosing among the available techniques and approaches, less invasive possible ones, in the attempt to limit the possible side effects to the maximum.

The advancement of knowledge, together with the development of scientific research, has allowed the growth of a population of patients who, despite suffering from systemic diseases, are kept in relative good health thanks to the use of modern therapies.

The group of diseases is wide and may represent a relative or absolute contraindication compared to the degree of compensation of the disease itself. For example, a compensated diabetic patient poses little significant problems in the execution of the surgery, while, on the contrary, a non-compensated diabetic patient can pose a much more relevant problem.

In short, the systemic pathological conditions to take into consideration are: diabetic patients, (Di Lauro 2000) (Sadeghi R 2014) patients with cardiovascular disease (hypertension, ischemic heart disease), cardio-surgery patients, (Della Valle A 2003) (Sammartino G 2011) hepatopathy patients, (Hong CH 2012) allergic patients, pregnant patients, transplanted patients, (Ward BB 2006) (Helenius-Hietala J 2016) dialysis patients, geriatric patients, patients taking bisphosphonates (Sammartino G 2011) (Khan A 2016) etc ...

Although the compensation is reached, the collaboration of the oral surgeon with the primary physicians of the patients is essential, intended both as primary care doctors or specialists.

In general, patients "at risk" should be treated in the simplest and a-traumatic way, choosing among the available techniques and approaches, less invasive possible ones, in the attempt to limit the possible side effects to the maximum; in the management of such patients, then, the problem of medical support therapy will arise, if necessary, for example, in surgical emergency, the broad-spectrum antibiotic therapy in non-compensated diabetic patients or associated antibiotic therapy in the patient with cardiovascular problems to avoid
complications such as bacterial endocarditis, linked to transient bacteraemia of eac surgery at the level of the oral cavity, in the presence of a reduced or poor cardiovascular system functionality.
Another problem often present in patients "at risk" is that of haemostasis, which can be linked to genetic diseases as well as to anticoagulant and anti-aggregating therapies (cardiovascular patients and cardiac surgery) or hematopoietic deficits (hepatopathy patients); new and old techniques (use of hemocomponents, PRP, PRF, PRGF) and the collaboration with the hematology centers (pool of platelets) can help to avoid the suspension of the therapy that, although protected by
partially equivalent treatments (heparinization), subjects the patients to a thromboembolic risk.
Nonetheless, the patients taking bisphosphonate therapy should also be addressed, to chemotherapy and radiotherapy of the head neck region, which may pose problems related to duration, the therapy quality, intended as a class of drugs, and concomitant diseases. It goes noted that, about the management of the latter clinical conditions, there is not a total *agreement* in the literature today.

Bibliography

Hong Della Valle A, Sammartino G, Marenzi G, Tia M, Di Lauro AE, Ferrari F, Lo Muzio L, Prevention of postoperative bleeding in anticoagulated patients undergoing oral surgery: use of platelet-rich plasma gel, J Oral Maxillofac Surg, 2003, Nov;61(11):1275-8

Di Lauro F, Bucci E. Chirurgia odontostomatologica con note di patologia. Editore Florio, 2000.

Helenius-Hietala J, Aberg F, Meurman JH, Nordin A, Isoniemi H, Oral Surgery in Liver Transplant Candidates: a Retrospective Study on Delayed Bleeding and Other Complications, Oral Surg Oral Med Oral Pathol Oral Radiol, 2016, May;121(5):490-5

Hong CH, Scobey MW, Napenas JJ, Brennan MT, Lockhart PB, Dental Postoperative Bleeding Complications in Patients with Suspected and Documented Liver Disease, Oral Dis, 18 (2012) 661-666

Khan A, Morrison A, Cheung A, Hashem W, Compston J, Osteonecrosis of the Jaw (ONJ): Diagnosis and Management in 2015, Osteoporos Int, 2016 Mar;27(3):853-9

Sammartino G, Dohan Ehrenfest DMN, Carile F, Tia M, Bucci P, Prevention of hemorrhagic complications after dental extractions into open heart surgery patients under anticoagulant therapy: the use of leukocyte and platelet-rich fibrin, J Oral Implantol, 2011 Dec;37(6):681-90

Sadeghi R, Taleghani F, Farhadi S, Oral Health Related Quality of Life in Diabetic Patients; J Dent Res Dent Clin Dent Prospects, 2014 Fall;8(4):230-4
Sammartino G, Marenzi G, Cioffi I, Teté S, Mortellaro C, Implant Therapy in Irradiated Patients, J Craniofac Surg, 2011 Mar;22(2):443-5

Ward BB, Weideman EM, Long-term Postoperative Bleeding after Dentoalveolar Surgery in the Pretransplant Liver Failure Patient, J Oral Maxillofac Surg, 64(2006), 1469-74

Regarding the clinical recommendations about Implantology and Endodontic Surgery, please refer to the clinical recommendations of the specific work groups (Implantology, Endodontics)

ORAL IMPLANT THERAPY

Oral implant therapy is a treatment method indicated for the replacement of missing teeth or those with a poor prognosis. It is a reliable therapy with a high success rate, accepted by the international scientific and dental community (Ekelund et al 2003, Ferrigno N et al 2002, Jemt T, Johansson J 2006, Fitzpatrick B 2006, Astrand P, et al 2008, Moraschini V et al 2015, Astrand P et al 2002, Attard NJ, Zarb GA 2003, Behneke A et al 2000, Blanes RJ et al 2007, Buser D et al 1997, Lekholm U et al 2006, Lekholm U et al 1999, Naert I et al 2002, Rasmusson L et al 2005, Romeo E et al 2002, Albrektsson T et al 1986, Smith DE, Zarb GA 1989, Esposito M et al 1998, Lang NP et al 2004, Misch CE et al 2008).

It is important to stress that increased knowledge and improvement of diagnostic and therapeutic procedures in the dental field now extend the potential for recovering compromised teeth. So, every effort should be made to achieve this and, resorting to tooth extraction only when essential (Thomas MV, Beagle JR. 2006, Holm- Pedersen P et al 2007, Torabinejad M et al 2007, Morris MF 2009, Tomasi C et al 2008, Gotfredsen K et al 2008).

Any prosthetic rehabilitation, including implant-supported work, is intended to resolve previous edentulism or replace hopeless teeth and can be carried out in different ways according to the needs of patients and their clinical, systemic and local conditions (Eckert SE, Laney WR. 1989, Bragger U et al 2001, Chee W, Jivraj S 2006, Pjetursson BE et al 2007, Bragger U et al 2007, Pjetursson BE, Lang NP 2008, Jung RE et al 2008, do Nascimento C et al 2008, Sailer I et al 2012, Hsu YT et al 2012, Wittneben JG et al 2014, Millen C et al 2015, Jemt T 2008, De Rouck T et al 2008, den Hartog L et al 2008, Chen ST, Buser D 2014).

Implant-supported prosthetic rehabilitation requires a surgical operation and the construction of a dental prosthesis. It must be performed with the use of appropriate instrument and dedicated technology. In order to achieve an optimal result, clinicians must first establish treatment indications and check any contraindications, inform the patient properly, make appropriate medical, diagnostic and prognostic assessments, perform the necessary preventive and/or therapeutic treatments in order to reduce the risk of complications and, last but not least, implement a proper clinical protocol. The success of prosthetic treatment on implants is greatly influenced by patient participation in a hygienic and occlusal monitoring programme (Hultin M et al 2007, Quirynen M et al 2007, Salvi GE, Zitzmann NU 2014, Monje A et al 2016).

The structural requirements for implant surgery are the same as for any other branch of dentistry. For this reason, it is not essential to have a dedicated operating theatre but simply a dental surgery in which proper hygiene, disinfection and sterile procedures are observed. The set of equipment and instruments considered satisfactory for optimal clinical performance includes a dental unit with good lighting and surgical aspiration, a dedicated surgical drilling unit, an x-ray device and dedicated sterile instruments.

Dental implants are “medical devices” and must therefore be covered by certification accrediting that they meet biocompatible safety requirements and that they comply with the functional and aesthetic purposes for which they are used (ISO 7405: 2008. Lautenschlager EP, Monaghan P 1993, Bachle M, Kohal RJ 2004, Esposito M et al 2005, Tschernitschek H et al 2005, Esposito M et al 2007, Kotsovilis S et al 2009; Subramani K et al 2009, Hashim D 2016).

The certification required for marketing in Italy ensures that the material product characteristics declared by the manufacturer comply with standards laid down in EU legislation.

In particular, the comparison, selection and processing of raw materials (for implants and for other biomaterials used in implants) must comply with international standards and European Directive 93/42 EC concerning certificate of origin, biocompatibility, toxicity, and allergenicity and safety. To ensure maximum transparency regarding the traceability of implants in use, it is recommended to attach and save documents issued by the manufacturer that can be used to identify the implant used together with clinical documentation relating to the individual case and give patients data identifying the type and specific characteristics of the implant used.

Implants must be packaged under sterile conditions for single-use and must no longer be used (even if re-sterilised) if the pack is no longer intact or after the expiry date indicated by the manufacturer.

Indications and contraindications to implant surgery

Each method has specific indications and contraindications and comes with its own attendant advantages and disadvantages and different treatment times and costs. Rehabilitation costs will inevitably be affected by the investments made by practitioners to ensure medium and long-term safety and reliability.

Elective indications for implant therapy are as follows:

- instability and/or lack of retention of a full mobile prosthesis;
- instability and/or lack of retention of a removable prosthesis;
- psychological distress associated with wearing a removable prosthesis;
- fixed rehabilitation of edentulous sites;
- fixed rehabilitation of edentulous sites interspersed with several teeth;
- replacement of teeth in a visible area;
- replacement of one or more irrecoverable teeth;
- replacement of one or more teeth in the presence of healthy adjacent teeth;
- replacement of one or more teeth adjacent to unreliable prosthetic abutments;
- fixed rehabilitation of an entire arch.

Absolute contraindications include:

- patient systemic conditions constituting an absolute impediment to any type of oral surgical procedure, to be identified on a case-by-case basis; (Hwang O, Wang HL. 2006)
- incomplete skeletal growth. (Bryant SR, Zarb GA 1998, Mankani N et al 2014)

Relative contraindications that may rule out implant therapy are as follows:

- clinical conditions and lifestyles (Scully C et al 2007, Hwang O, Wang HL, 2007, Mombelli A, Cionca N 2006, Zitzmann NU et al 2008, Bornstein MM et al 2009, Ripamonti CI et al 2009 Chadha GK et al 2013) declared when the medical history is taken and for which the dentist has suggested that there is a need for change with the aim of eliminating or reducing the risk of treatment failure. Examples of such conditions include: a state of serious drug dependency (Hwang O, Wang HL 2006) physical and/or mental deficiencies (Alcouffe F 1991) that prevent or make it very difficult to carry out proper oral hygiene operations at home, heavy smoking (Klokkevold PR, Han TJ 2007, Heitz-Mayfield LJ, Huynh-Ba G 2009, Chrcanovic BR et al 2015, Moraschini V et al. 2016), untreated or unsuccessfully treated periodontitis and poor patient compliance (Van der Weijden GA, et al 2005, Schou S et al 2006, Karoussis IK et al 2007, Schou S. 2008, Ong CT et al 2008, Al-Zahrani MS 2008, Renvert S, Persson GR 2009, Heitz-Mayfield LJ, Huynh-Ba G 2009, Renvert S, Persson GR 2009, Zangrando MS et al 2015, Sousa V et al 2015, Oerks J et al 2016) etc.;
- Presence of a residual bone ridge that is unsuitable (in terms of quantity, quality and morphology) to accommodate an implant with adequate dimension to perform the functions required, where surgical procedures for the correction of these anatomical conditions are not feasible or subject to high rates of failure or complications (Martin W et al 2009);
- inadequacy of the space required to construct a morphologically and functionally suitable prosthetic device, if procedures that could be implemented to change the situation are not feasible or if they are feasible but involve an unfavourable cost/benefit ratio (Martin W et al 2009).

Restoration of teeth and periodontal tissues to a satisfactory state of health is an essential requirement before subjecting patients to implant treatment and allows some risk factors for long-term implant survival to be reduced.

The adoption of prosthetic rehabilitation on implants must always be considered among other available rehabilitation operations whenever it can be assumed that the patient will enjoy a long-term functional and aesthetic outcome.

Prosthetic therapy on implants must be carried out using technologically appropriate equipment and instruments

Diagnosis

Before carrying out prosthetic treatment on implants, it is important to carry out an in-depth diagnostic assessment based on a thorough medical and dental history, clinical examination, x-ray examinations, laboratory and/or instrumental tests and a study of plaster models.

Taking a medical history makes it possible to collect information on any systemic diseases, medical treatments followed and lifestyles (e.g. poor oral hygiene and smoking) that are associated with a greater risk for surgery and/or achieving implant success. A dental history provides information on previous oral diseases, causes of tooth loss and any dental treatments carried out.

The clinical examination includes an objective examination of the face. As part of this, it is important to assess the smile line and physically examine the oral cavity in order to check the health or otherwise of the mucosa, periodontal tissues (Zangrando MS et al 2015, Sousa V et al 2015, Derks J et al 2016) and residual teeth, periodontal biotype, presence or absence of keratinised mucosa (Gobbato et al 2013), occlusion, intermaxillary ratios, morphology and sizes of edentulous sites (Cawood JI, Howell RA 1991), morphology of adjacent and contralateral teeth, position of opposing teeth, presence of signs of parafunctions (Sahin S et al 2002, Lobbezoo F et al 2006, Chrcanovic BR et al 2015) and degree of mouth opening.

Conventional radiographic methods (intraoral x-ray, orthopantomography and teleradiography) often provide enough information to establish the feasibility of implant therapy and planning (Miles DA, Van Dis ML 1993, Monsour PA, Dudhia R 2008, Vazquez L et al 2008). Under certain and anatomical and topographic conditions, a second-level check must be carried out. This involves a computed tomography (CT) scan, which allows three-dimensional imaging of the implant sites together with an approximate evaluation of bone quality. As an example, this test can be used whenever there is a reduction in available bone volume or in the presence of noble anatomic structures, such as the inferior alveolar nerve or the maxillary sinus. This method can be used when the available information is insufficient to allow proper planning (Almog DM et al 2006, Guerrero ME et al 2006, Harris D et al 2012).

Laboratory and/or instrumental examinations (blood tests, ECG etc.) or consultation with the patients treating physician may be necessary if systemic diseases are present and/or when the practitioner thinks it wise to supplement information obtained from the medical history and diagnostic procedure. A study of plaster models mounted in an articulator and supplemented by a diagnostic wax-up, if necessary and at the discretion of the practitioner, allows a more thorough evaluation of the edentulous area and its

relations with the adjacent teeth and the opposing arch to allow accurate prosthetic design on a case-by-case basis. It is strongly recommended that prosthetic rehabilitation treatment on implants should be based on prosthetic design (Eckert SE, Laney WR 1989, Pjetursson BE, Lang NP 2008).
The patient must be kept properly informed about his/her clinical conditions, the various rehabilitation options and achievable outcomes. An interview is therefore the most important and appropriate tool that practitioners can use to understand a patient's needs and expectations, his/her motivation for the implant-supported prosthetic rehabilitation and his/her expected level of cooperation with the proposed rehabilitation option. The interview can also provide accurate information on clinical problems, surgical and prosthetic procedures, advantages and disadvantages compared to other achievable therapeutic options and their long-term maintenance, possible risks and complications, need for subsequent regular check-ups, likelihood of early and/or late failure, methods of intervention in case of failure and criteria for patient co responsibility.

Implant-supported prosthetic rehabilitation treatment requires thorough diagnostic assessment beforehand and appropriate prosthetic design.

Particular attention should be paid to patients who have demonstrated susceptibility to periodontal disease (history of periodontitis) and/or have inadequate oral hygiene. Such patients must be properly informed of the possible complications and risks associated with the condition and must be encouraged to practice proper oral hygiene and undergo any necessary dental and periodontal treatment before implant insertion.

Particular attention must be paid to the possible presence of systemic diseases, medical treatments followed and lifestyles (e.g. Smoking) which may involve a greater risk for surgery and/or a successful outcome for the implant.

Clinical and anatomical conditions for implant surgery

The dentist's main aim is to maintain and restore the oral cavity's state of health. This condition is essential and indispensable before the patient can be allowed to undergo a rehabilitation procedure. For this reason, implant therapy is generally one of the last stages of the treatment plan. Restoration of oral health conditions reduces certain risk factors affecting long-term implant survival.
One of the basic prerequisites to be observed before implant-supported prosthetic rehabilitation can be carried out is having a sufficient volume of residual bone in toothless areas (Cawood JI, Howell RA 1991). Lack of bone can make it difficult to insert implants of appropriate size or induce the practitioner to accept compromises that will expose the treatment to early or late failure.

Insufficient bone volume is a very common condition that can now be overcome by techniques designed to adapt bone volume to implant size. Surgical bone augmentation techniques designed for different clinical conditions can be performed beforehand or at the same time as implant placement (Wallace SS, Froum SJ 2003, Esposito M et al 2006, Donos N et al 2008, Pjetursson BE et al 2008, Rocchietta I et al 2008, Tan WC et al 2008, Tonetti MS, Hammerle CH 2008, Esposito M et al 2009, Nkenke E, Stelzle F 2009, Chiapasco M, Zaniboni M 2009, Lutz R et al 2015, Sanz- Sanchez I et al 2015).

In certain patients and under particular circumstances, if the bone morphology is not optimal, practitioners can insert tilted implants, insert narrow size implants or, in cases of extreme atrophy, insert implants that fit the residual bone morphology. These procedures cannot be applied indiscriminately in all clinical situations (Del Fabbro M et al 2012, Menini M et al 2012, Klein MO et al 2014, Lemos CA et al 2016. Food and Drug Administration HHS 2014, Linkow LI et al 2016, Kapur KK 1989, Duda M et al 2016, Yanase RT et al 1994 Moore DJ, Hansen PA 2004).

In edentulous areas to be rehabilitated using implant-supported prostheses, the presence of a sufficient volume of residual bone is fundamental. Where feasible and indicated, bone augmentation techniques can be applied before or during implant insertion or implants sized, shaped and angled to fit the residual bone anatomy can be used.

Implant insertion timing and procedures and biomechanical load

Recent scientific findings on bone tissue healing processes and changes in implant shape and surface properties have allowed a reduction in bone integration time and thus treatment time.

A reduction treatment times is one of the objectives to be achieved in implant therapy with a view to improving patient welfare and minimising functional, aesthetic and psychological distress due to having one or more missing teeth (Kent G 1992, Zimmer CM 1992, Cibirka RM et al 1997, Fueki K et al 2007, Thomason JM et al 2007, Emami E et al 2009, Thomason J 2010, McGrath C et al 2012 , Kashbour WA et al 2015).

When an irrecoverable, acutely inflamed tooth has to be extracted, an appropriate waiting time is normally observed before implant placement. This may be between 6 and 12 weeks if an early placement method is used or more than 12 weeks if the practitioner prefers to wait for the post-extraction socket to heal fully. With certain patients and cases, implant surgery can be performed immediately post-extraction (Chen ST et al 2004, Hammerle CH et al 2004, Esposito MA 2006, Quirynen M et al 2007, Atieh MA et al 2009, Esposito M et al 2010). Immediate implant insertion must be considered a complex procedure and can only be considered under ideal anatomical bone and/or

gum conditions (for example, thick gingival biotype, intact residual alveolar walls, presence of bone apical to the apex of the relevant tooth) and must be performed by experienced clinicians, particularly in situations where the case also has an aesthetic impact (Buser D et al 2017).

Only with selected patients and in special cases is it possible to perform early or immediate insertion of a prosthesis, with or without functional loading. These procedures are supported by encouraging clinical results, particularly concerning rehabilitation of cases of total mandibular and maxillary edentulism. Although existing reports in the literature have investigated the possibility of performing prosthetic rehabilitation with immediate loading even in partially edentulous patients, this method cannot be applied indiscriminately in all situations (Misch CE et al 2004, Cochran DL et al 2004, Esposito M et al 2007, Kawai Y Taylor JA 2007, Bergkvist G et al 2008, Sennerby L, Gottlow J 2008, Esposito M et al 2009, Roccuzzo M et al 2009, Degidi M et al 2010, Degidi M et al 2013, Papaspyridakos P et al 2014, Schimmel M et al 2014, Schrott A et al 2014, Gallucci GO et al 2014, De Bruyn H et al 2014).

Where clinical conditions compromise primary implant stability (e.g. limited bone quality and quantity and immediate loading), implants can be joined together.

Joining the implants together can decrease the effect of displacement forces, making it possible to improve the prognosis of implant-supported prosthetic therapy when combined with appropriate management of static and dynamic occlusal forces (Salvi GE, Bragger U 2009, Sanz M, Naert I 2009, Gross MD 2008, Koyano K, Esaki D 2015, Millen C et al 2015, Wittneben JG et al 2014, Naert I et al 2012, Chang M et al 2013, Vigolo P et al 2015, Vigolo P et al 2012, Weber HP, Sukotjo, 2007).

Connection systems are normally based on the use of a bar or superstructure that joins the implants together and can be screwed, cemented (Vigolo P et al 2012, Cochran DL et al 2004, Gallucci GO et al 2014) or welded intraorally (Degidi M et al 2010, Degidi M et al 2013). The connection must be carried out using reliable, state-of-the-art methods.

During implant-supported prosthetic rehabilitation, fixed or removable provisional prostheses can be used while awaiting post-insertion implant osseointegration in order to ensure satisfactory aesthetic and functional conditions. These will vary depending on the type and extent of the edentulism and the patient's needs.

Because of a need to limit early functional loads that can destabilise the implants during the osseointegration stage, the provisional prosthesis must be designed, constructed and used in such a way as not to interfere with implant site healing and the osseointegration process. To this end, when possible, tooth-supported provisional procedures are to be preferred over removable solutions with mucosal support.

Only in certain cases is it possible to make implant-supported provisional prostheses, with or without functional loading, immediately after surgical implant placement.
The design and construction of permanent prostheses in oral implant therapy is one of the most crucial stages for achieving predictable long-term success. The precision of the interface between the prosthesis and implants and achievement of an appropriate occlusal fit (Gross MD 2008, Koyano K, Esaki D 2015) are two crucial factors when it comes to achieving a favourable biological response and long-term prognosis following rehabilitation.
Any inaccuracies, irregularities or gaps facilitate plaque build-up, exposing the patient to infections and inflammations of the peri-implant tissues (do Nascimento C et al 2008); they can also affect the stability and mechanical performance of the system as a whole (Millen C et al 2015).
With regard to the type of connection between prosthesis and implant, be it screwed or cemented, no significant differences have been reported to date in the literature in terms of prosthetic success and survival (Chee W 2006, Vigolo P et al 2012, Sailer I et al 2012, Wittneben JG et al 2014).

In order to ensure patients undergoing implant-supported prosthetic treatment enjoy satisfactory aesthetic and functional conditions, a provisional prosthesis can be used provided it is designed, constructed and used in such a way as not to interfere with healing of the implant site and the osseointegration process.

When possible, tooth-supported provisional procedures are to be preferred over removable solutions with mucosal support.

Accuracy of the prosthetic-implant interface and achievement of an appropriate occlusal fit are crucial to ensure a good prognosis.

Implant-supported prosthetic rehabilitation and follow-up

Following implant rehabilitation, healthy maintenance of peri-implant tissues and of the entire oral cavity requires a healthy lifestyle, good oral hygiene at home and regular dental check-ups.
Patients must be properly informed that non-compliance with home cleaning instructions and regular dental check-ups and can lead to an increase in the risk of infectious and inflammatory complications affecting tooth, periodontal and peri-implant tissues (Hultin M et al 2007, Quirynen M et al 2007, Salvi GE, Zitzmann NU 2014, Monje A et al 2016).
As part of the regular check-ups, in addition to encouraging patients to continue good plaque control, it is advisable to probe peri-implant tissues to detect the possible existence of an inflammatory infectious

condition that, when present, requires appropriate treatment. Similarly, it is advisable to perform regular occlusal checks and take early action if prosthetic complications are identified.

X-ray checks, when necessary, can confirm (but not replace) a clinical diagnosis, monitor the accuracy and stability of prosthetic components and verify that the marginal bone level has been maintained.

To conclude, implant-supported prosthetic rehabilitation depends on numerous factors that, when taken altogether, contribute to the achievement of long-term clinical success. Particularly important among these are: thorough diagnosis, an appropriate treatment plan, correct implementation of surgical and prosthetic procedures, an implant system that complies with current regulations, the operator's skills and, last but not least, acceptance of joint responsibility by patients.

Prosthetic rehabilitation on implants is therefore a very worthwhile form of treatment from a technological, scientific and professional viewpoint.

Bibliography

Al-Zahrani MS. Implant therapy in aggressive periodontitis patients: a systematic review and clinical implications. Quintessence Int. 2008;39(3):211-5.

Albrektsson T, Zarb GA, Worthington P, Eriksson AR. The long-term efficacy of currently used dental implants: a review and proposed criteria of success. J Oral Maxillofac Implants 1986;1:11-25.

Alcouffe F. Psychological considerations in implantology. J Parodontol. 1991;10(2):133-42.

Almog DM, Benson BW, Wolfgang L, Frederiksen NL, Brooks SL. Computerized tomography-based imaging and surgical guidance in oral implantology. J Oral Implantol. 2006;32(1):14-8.

Astrand P, Ahlqvist J, Gunne J, Nilson H. Implant treatment of patients with edentulous jaws: a 20-year follow-up. Clin Implant Dent Relat Res. 2008;10(4):207-17.

Astrand P, Engquist B, Anzén B, Bergendal T, Hallman M, Karlsson ,, Kvint S, Lysell L, Rundcrantz T. Nonsubmerged and submerged implants in the treatment of the partially edentulous maxilla. Clin Implant Dent Relat Res. 2002;4(3):115-27.

Atieh MA, Payne AG, Duncan WJ, Cullinan MP. Immediate restoration/loading of immediately placed single implants: is it an effective bimodal approach? Clin Oral Implants Res. 2009;20(7):645-59.

Attard NJ, Zarb GA. Implant prosthodontic management of partially edentulous patients missing posterior teeth: the Toronto experience. J Prosthet Dent. 2003;89(4):352-9.

Bachle M, Kohal RJ. A systematic review of the influence of different titanium surfaces on proliferation, differentiation and protein synthesis of osteoblast-like MG63 cells. Clin Oral Implants Res. 2004;15(6):683- 92.

Behneke A, Behneke N, d'Hoedt B. The longitudinal clinical effectiveness of ITI solid-screw implants in partially edentulous patients: a 5-year follow-up report. Int J Oral Maxillofac Implants. 2000;15(5):633-45.

Bergkvist G, Nilner K, Sahlholm S, Karlsson U, lindh C. (Department of Prosthetic Dentistry, Faculty of Odontology, Malmo University, Malmo, Sweden): Immediate loading of Implants in the Edentulous Maxilla: Use of an Interim Fixed Prosthesis Followed by a Permanent Fixed Prosthesis: A 32-Month Prospective Radiological and Clinical Study. Clin Implant Dent Relat Res. 2008 Apr 1

Blanes RJ, Bernard JP, Blanes ZM, Belser UC. A 10-year prospective study of ITI dental implants placed in the posterior region. I: Clinical and radiographic results. Clin Oral Implants Res. 2007;18(6):699-706.

Bornstein MM, Cionca N, Mombelli A. Systemic conditions and treatments as risks for implant therapy. Int J Oral Maxillofac Implants. 2009;24 Suppl:12-27.

Bragger U, Aeschlimann S, Burgin ,, Hammerle CH, lang NP. Biological and technical complications and failures with fixed partial dentures (FPD) on implants and teeth after four to five years of function. Clin Oral Implants Res. 2001;12(1):26-34.

Bragger U, lang NP, Zwahlen M. Comparison of survival and complication rates of tooth-supported fixed dental prostheses (FDPs) and implant-supported FDPs and single crowns (SCs). Clin Oral Implants Res. 2007;18 Suppl 3:97-113.

Bryant SR, Zarb GA. Osseointegration of oral implants in older and younger adults. Int J Oral Maxillofac Implants. 1998;13(4):492-9.

Buser D, Chappuis V,, Belser UC, Chen S.Implant placement post extraction in esthetic single tooth sites: when immediate, when early, when late? Periodontol 2000. 2017 Feb;73(1):84-102

Buser D, Mericske-Stern R, Bernard JP, Behneke A, Behneke N, Hirt HP, Belser UC and lang NP. long-term evaluation of non-submerged ITI implants. Part 1: 8-year life table analysis of a prospective multi-center study with 2359 implants. Clin Oral Implants Res, 1997; 8:161-172.

Cawood JI, Howell RA. A classification of the edentulous jaws. Int J Oral Maxillofac Surg. 1988;17(4):232-6

Chadha GK, Ahmadieh A, Kumar S, Sedghizadeh PP. Osseointegration of dental implants and osteonecrosis of the jaw in patients treated with bisphosphonate therapy: a systematic review. J Oral Implantol. 2013 Aug;39(4):510-20.

Chang M, Chronopoulos V,, Mattheos N Impact of excessive occlusal load on successfully-osseointegrated dental implants: a literature review. J Investig Clin Dent. 2013 Aug; 4(3):142-50.

Chee ,, Jivraj S. Screw versus cemented implant supported restorations. Br Dent J. 2006 21;201(8):501-7.

Chen ST, Buser D. Esthetic outcomes following immediate and early implant placement in the anterior maxilla--a systematic review.Int J Oral Maxillofac Implants. 2014;29 Suppl:186-215.

Chen ST, Wilson TG Jr, Htimmerle CH. Immediate or early placement of implants following tooth extraction: review of biologic basis, clinical procedures, and outcomes. Int J Oral Maxillofac Implants. 2004;19 Suppl:12-25.

Chiapasco M, Zaniboni M. Clinical outcomes of GBR procedures to correct peri-implant dehiscences and fenestrations: a systematic review. Clin. Oral Impl. Res. 20 (Suppl. 4), 2009; 113-123.

Chrcanovic BR, Albrektosson T, Weeneberg A. Bruxism and dental implants: A meta-analysis. Implant Dent 2015: 24(5): 505-516

Chrcanovic BR, Albrektsson T, Wennerberg A. Smoking and dental implants: A systematic review and meta- analysis. J Dent. 2015 May;43(5):487-98.

Cibirka RM, Razzoog M, Lang BR. Critical evaluation of patient responses to dental implant therapy. J Prosthet Dent. 1997;78(6):574-81.

Cochran DL, Morton D, Weber HP. Consensus statements and recommended clinical procedures regarding loading protocols for endosseous dental implants. Int J Oral Maxillofac Implants. 2004;19 Suppl:109-13.

De Bruyn H, Raes S, Ostman PO, Cosyn J.Immediate loading in partially and completely edentulous jaws: a review of the literature with clinical guidelines. Periodontol 2000. 2014 Oct;66(1):153-87.

De Rouck T, Collys K, Cosyn J. Single-tooth replacement in the anterior maxilla by means of immediate implantation and provisionalization: a review. Int J Oral Maxillofac Implants. 2008;23(5):897-904.

Degidi M, Nardi D, Piattelli A. A Six-Year Follow-up of Full-Arch Immediate Restorations Fabricated With an Intraoral Welding Technique Implant Dent. 2013 Jun;22(3):224-31.

Degidi M, Nardi D, Piattelli A. Immediate loading of the edentulous maxilla with a definitive restoration supported by an intraorally welded titanium bar and tilted implants. Int J Oral Maxillofac Implants. 2010 Nov-Dec;25(6):1175-82

Del Fabbro M, Bellini CM, Romeoi D, Francetti L. Tilted implants for the rehabilitation of edentulous jaws: a systematic review. Clin Impl Dent Rel Res 2012: 14(4): 612-621

den Hartog L, Slater JJ, Vissink A, Meijer HJ, Raghoebar GM. Treatment outcome of immediate, early and conventional single-tooth implants in the aesthetic zone: a systematic review to survival, bone level, soft- tissue, aesthetics and patient satisfaction. J Clin Periodontol. 2008;35(12):1073-86.

Derks J1, Schaller D2, Hakansson J2, Wennstrom JL2, Tomasi C2, Berglundh T2 Effectiveness of Implant Therapy Analyzed in a Swedish Population: Prevalence of Peri-implantitis. J Dent Res. 2016 Jan;95(1):43-9.

do Nascimento C, Barbosa RE, Issa JP, Watanabe E, Ito IY, Albuquerque RF Jr. Bacterial leakage along the implant-abutment interface of premachined or cast components. Int J Oral Maxillofac Surg. 2008;37(2):177- 80.

Donos N, Mardas N, Chadha V. Clinical outcomes of implants following lateral bone augmentation: systematic assessment of available options (barrier membranes, bone grafts, split osteotomy). J Clin Periodontol. 2008;35(8 Suppl):173-202.

Duda M1, Matalon S, Lewinstein I, Harel N, Block J, Ormianer Z. One Piece Immediately Loaded Implants

Versus 1 Piece or 2 Pieces Delayed: 3 Years Outcome. Implant Dent. 2016 Feb;25(1):109-13.

Eckert SE, laney WR. Patient evaluation and prosthodontic treatment planning for osseointegrated implants. Dent Clin North Am. 1989;33(4):599-618.

Ekelund JA, lindquist lW, Carlsson GE and Jemt T. Implant treatment in the edentulous mandible: a prospective study on Branemark system implants over more than 20 years. Int J Prosthodont, 2003;16:602- 608.

Emami E, Heydecke G, Rompré PH, de Grandmont P, Feine JS.Impact of implant support for mandibular dentures on satisfaction, oral and general health-related quality of life: a meta-analysis of randomized- controlled trials. Clin Oral Implants Res. 2009;20(6):533-44.

Esposito M, Grusovin MG, Achille H, Coulthard P, Worthington HV. Interventions for replacing missing teeth: different times for loading dental implants. Cochrane Database Syst Rev. 2009;(1):CD003878.

Esposito M, Grusovin MG, Coulthard P, Thomsen P, Worthington HV. A 5-year follow-up comparative analysis of the efficacy of various osseointegrated dental implant systems: a systematic review of randomized controlled clinical trials. Int J Oral Maxillofac Implants. 2005;20(4):557-68.

Esposito M, Grusovin MG, Coulthard P, Worthington HV. The efficacy of various bone augmentation procedures for dental implants: a Cochrane systematic review of randomized controlled clinical trials. Int J Oral Maxillofac Implants. 2006;21(5):696-710.

Esposito M, Grusovin MG, Felice P, Karatzopoulos G, Worthington HV, Coulthard P. Interventions for replacing missing teeth: horizontal and vertical bone augmentation techniques for dental implant treatment. Cochrane Database Syst Rev. 2009 7;(4):CD003607.

Esposito M, Grusovin MG, Willings M, Coulthard P, Worthington HV. The effectiveness of immediate, early, and conventional loading of dental implants: a Cochrane systematic review of randomized controlled clinical trials. Int J Oral Maxillofac Implants. 2007;22(6):893-904.

Esposito M, Hirsch JM, lekholm ,, Thomsen P. Biological factors contributing to failures of osseointegrated oral implants. (I). Success criteria and epidemiology. Eur J Oral Sci. 1998;106(1):527-51.

Esposito M, Murray-Curtis l, Grusovin MG, Coulthard P, Worthington HV. Interventions for replacing missing teeth: different types of dental implants. Cochrane Database Syst Rev. 2007;(4):CD003815

Esposito M, Grusovin MG, Polyzos IP, Felice P, Worthington HV.Timing of implant placement after tooth extraction: immediate, immediate-delayed or delayed implants? A Cochrane systematic review. Eur J Oral Implantol. 2010 Autumn;3(3):189-205.

Esposito MA, Koukoulopoulou A, Coulthard P, Worthington HV. Interventions for replacing missing teeth: dental implants in fresh extraction sockets (immediate, immediate-delayed and delayed implants). Cochrane Database Syst Rev. 2006;(4):CD005968

Ferrigno N, laureti M, Fanali S, Grippaudo G. A long-term follow-up study of non-submerged ITI implants in the treatment of totally edentulous jaws. Part I: Ten-year life table analysis of a prospective multicenter study with 1286 implants. Clin Oral Implants Res. 2002;13(3):260-73.

Fitzpatrick B. Standard of care for the edentulous mandible: a systematic review. J Prosthet Dent. 2006;95(1):71-8.

Food and Drug Administration, HHS.Dental devices; reclassification of blade-form endosseous dental implant. Final order. Fed Regist. 2014 Jun 18;79(117):34623-5.

Fueki K, Kimoto K, Ogawa T, Garrett NR. Effect of implant-supported or retained dentures on masticatory performance: a systematic review. J Prosthet Dent. 2007; 98(6):470-7.

Gallucci GO, Benic GI, Eckert SE, Papaspyridakos P, Schimmel M, Schrott A, Weber HP.Consensus statements and clinical recommendations for implant loading protocols. Int J Oral Maxillofac Implants. 2014;29 Suppl:287-90.

Gobbato L, Avila-Ortiz G, Sohrabi K, Wang CW, Karimbux N. The effect of keratinized mucosa width on peri- implant health: a systematic review. Int J Oral Maxillofac Implants. 2013 Nov-Dec;28(6):1536-45.

Gotfredsen K, Carlsson GE, Jokstad A, Arvidson Fyrberg K, Berge M, Bergendal B, Bergendal T, Ellingsen JE, Gunne J, Hofgren M, Holm B, Isidor F, Karlsson S, Klemetti E, Lang NP, Lindh T, Midtbo M, Molin M, Narhi T, Nilner K, Owall B, Pjetursson B, Saxegaard E, Schou S, Stokholm R, Thilander B, Tomasi C, Wennerberg A. Implants and/or teeth: consensus statements and recommendations. J Oral Rehabil. 2008; 35 Suppl 1:2-8.

Gross MD. Occlusion in implant dentistry. A review of the literature of prosthetic determinants and current concepts. Aust Dent J. 2008 Jun;53 Suppl 1:S60-8.

Guerrero ME, Jacobs R, Loubele M, Schutyser F, Suetens P, van Steenberghe D. State-of-the-art on cone beam CT imaging for preoperative planning of implant placement. Clin Oral Investig. 2006;10(1):1-7.

Hammerle CH, Chen ST, Wilson TG Jr. Consensus statements and recommended clinical procedures regarding the placement of implants in extraction sockets. Int J Oral Maxillofac Implants. 2004;19 Suppl:26- 8.

Harris D, Horner K, Grondahl K, Jacobs R, Helmrot E, Benic GI, Bornstein MM, Dawood A, Quirynen

M.E.A.O. guidelines for the use of diagnostic imaging in implant dentistry 2011. A consensus workshop organized by the European Association for Osseointegration at the Medical University of Warsaw. Clin Oral Implants Res. 2012 Nov;23(11):1243-53.

Hashim D, Cionca N, Courvoisier DS, Mombelli A.A systematic review of the clinical survival of zirconia implants. Clin Oral Investig. 2016 Sep;20(7):1403-17.

Heitz-Mayfield LJ, Huynh-Ba G. History of treated periodontitis and smoking as risks for implant therapy. Int J Oral Maxillofac Implants. 2009;24 Suppl:39-68.

Holm-Pedersen P, Lang NP, Muller F. What are the longevities of teeth and oral implants? Clin Oral Implants Res. 2007;18 Suppl 3:15-9.

Hsu YT, Fu JH, Al-Hezaimi K, Wang HL. Biomechanical implant treatment complications: a systematic review of clinical studies of implants with at least 1 year of functional loading. Int J Oral Maxillofac Implants. 2012 Jul-Aug;27(4):894-904.

Hultin M, Komiyama A, Klinge B. Supportive therapy and the longevity of dental implants: a systematic review of the literature. Clin Oral Implants Res. 2007;18 Suppl 03:50-62.

Hwang D, Wang HL. Medical contraindications to implant therapy: part I: absolute contraindications. Implant Dent. 2006;15(4):353-60.

Hwang D, Wang HL. Medical contraindications to implant therapy: Part II: relative contraindications. Implant Dent. 2007;16(1):13-23.

ISO 7405:2008. Dentistry - Evaluation of biocompatibility of medical devices used in dentistry International Organization for Standardization. 2008.

Jemt T, Johansson J. Implant treatment in the edentulous maxillae: a 15-year follow-up study on 76 consecutive patients provided with fixed prostheses. Clin Implant Dent Relat Res. 2006;8(2):61-9.

Jemt T. Single implants in the anterior maxilla after 15 years of follow-up: comparison with central implants in the edentulous maxilla. Int J Prosthodont. 2008 Sep-;21(5):400-8.

Jung RE, Pjetursson BE, Glauser R, Zembic A, Zwahlen M, Lang NP. A systematic review of the 5-year survival and complication rates of implant-supported single crowns. Clin Oral Implants Res. 2008;19(2):119- 30.

Kapur KK. Veterans Administration Cooperative Dental Implant Study--comparisons between fixed partial dentures supported by blade-vent implants and removable partial dentures. Part II: Comparisons of success rates and periodontal health between two treatment modalities. J Prosthet Dent. 1989 Dec;62(6):685-703.

Karoussis IK, Kotsovilis S, Fourmousis I. A comprehensive and critical review of dental implant prognosis in periodontally compromised partially edentulous patients. Clin Oral Implants Res. 2007;18(6):669-79.

Kashbour WA, Rousseau NS, Ellis JS, Thomason JM. Patients' experiences of dental implant treatment: A literature review of key qualitative studies. J Dent. 2015 Jul;43(7):789-97.

Kawai Y, Taylor JA. Effect of loading time on the success of complete mandibular titanium implant retained overdentures: a systematic review. Clin Oral Implants Res. 2007;18(4): 399-408.

Kent G. Effects of osseointegrated implants on psychological and social well-being: a literature review. J Prosthet Dent. 1992;68(3):515-8.

Klein MO, Schiegnitz E, Al-Nawas B. Systematic review on success of narrow-diameter dental implants. Int J Oral Maxillofac Implants. 2014;29 Suppl:43-54.

Klokkevold PR, Han TJ. How do smoking, diabetes, and periodontitis affect outcomes of implant treatment? Int J Oral Maxillofac Implants. 2007;22 Suppl:173-202.

Kotsovilis S, Fourmousis I, Karoussis IK, Bamia C. A systematic review and meta-analysis on the effect of implant length on the survival of rough-surface dental implants. J Periodontol. 2009;80(11):1700-18.

Koyano K, Esaki D. Occlusion on oral implants: current clinical guidelines. J Oral Rehabil. 2015 Feb;42(2):153-61

Lang NP, Berglundh T, Heitz-Mayfield LJ, Pjetursson BE, Salvi GE, Sanz M. Consensus statements and recommended clinical procedures regarding implant survival and complications. Int J Oral Maxillofac Implants. 2004;19 Suppl:150-4.

Lautenschlager EP, Monaghan P. Titanium and titanium alloys as dental materials. Int Dent J. 1993;43(3):245-53.

Lekholm U, Grondahl K, Jemt T. Outcome of oral implant treatment in partially edentulous jaws followed 20 years in clinical function. Clin Implant Dent Relat Res. 2006;8(4):178-86.

Lekholm U, Gunne J, Henry P, Higuchi K, Lindén U, Bergstrom C, van Steenberghe D. Survival of the Branemark implant in partially edentulous jaws: a 10-year prospective multicenter study. Int J Oral Maxillofac Implants. 1999;14(5):639-45.

Lemos CA, Ferro-Alves ML, Okamoto R, Mendonça MR, Pellizzer EP. Short dental implants versus standard dental implants placed in the posterior jaws: A systematic review and meta-analysis. J Dent. 2016 Apr;47:8- 17.

Linkow LI, Winkler S, Shulman M, Dal Carlo L, Pasqualini ME, Rossi F, Nardone M: A new look at the blade implant. J Oral Implantol. 2016 Aug;42(4):373-80

Lobbezoo F, Brouwers JE, Cune MS, Naeije M. Dental implants in patients with bruxing habits. J Oral Rehabil. 2006;33(2):152-9.

Lutz R, Neukam FW, Simion M, Schmitt CM. Long term outcomes of bone augmentation on soft and hard tissue stability: a systematic review. Clin Oral Impl Res 2015 26 suppl 11: 103-122

Mankani N1, Chowdhary R, Patil BA, Nagaraj E, Madalli P. Osseointegrated dental implants in growing children: a literature review. J Oral Implantol. 2014 Oct;40(5):627-31.

Martin W, Lewis E, Nicol A. Local risk factors for implant therapy. Int J Oral Maxillofac Implants. 2009;24 Suppl:28-38.

McGrath C, Lam O, Lang N. An evidence-based review of patient-reported outcome measures in dental implant research among dentate subjects.J Clin Periodontol. 2012 Feb;39 Suppl 12:193-201.

Menini M, Signori A, Tealdo T, Belivalcqua M, Pera F, Ravera G, Pera P. Tilted implants in the immediate loading rehabilitation of the maxilla: a systematic review. J Dent Res 2012 91(9): 821-827.

Miles DA, Van Dis ML. Implant radiology. Dent Clin North Am. 1993 Oct;37(4):645-68.

Millen C, Bragger U, Wittneben JG. Influence of prosthesis type and retention mechanism on complications with fixed implant-supported prostheses: a systematic review applying multivariate analyses.Int J Oral Maxillofac Implants. 2015 Jan-Feb;30(1):110-24.

Misch CE, Hahn J, Judy KW, Lemons JE, Linkow LI, Lozada JL, Mills E, Misch CM, Salama H, Sharawy M, Testori T, Wang HL; Immediate Function Consensus Conference. Workshop guidelines on immediate loading in implant dentistry. November 7, 2003. J Oral Implantol. 2004;30(5):283-8.

Misch CE., Perel ML., Wang HL., Sammartino G, Galindo-Moreno P., Trisi P., Steigmann M., Rebaudi A., Palti A., Pikos Ma., Schwartz-Arad D., Choukroun J., Guiterrez-Perez JL., Marenzi G., Valavanis DK.. Implant success, survival, and failure: the International Congress of Oral Implantologists (ICOI) Pisa Consensus Conference. Implant Dent. 2008 Mar;17(1):5-15. Implant Dentistry (2008), p. 5-15, ISSN: 1056-6163

Mombelli A, Cionca N. Systemic diseases affecting osseointegration therapy. Clin Oral Implants Res. 2006;17 Suppl 2:97-103.

Monje A, Aranda L, Diaz KT, Alarc6n MA, Bagramian RA, Wang HL, Catena A. Impact of Maintenance Therapy for the Prevention of Peri-implant Diseases: A Systematic Review and Meta-analysis. J Dent Res. 2016 Apr;95(4):372-9

Monsour PA, Dudhia R. Implant radiography and radiology. Aust Dent J. 2008;53 Suppl 1:S11-25.

Moore DJ1, Hansen PA. A descriptive 18-year retrospective review of subperiosteal implants for patients with severely atrophied edentulous mandibles. J Prosthet Dent. 2004 Aug;92(2):145-50.

Moraschini V, Poubel LA, Ferreira VF, Barboza Edos S. Evaluation of survival and success rates of dental implants reported in longitudinal studies with a follow-up period of at least 10 years: a systematic review. Int J Oral Maxillofac Surg. 2015 Mar;44(3):377-88.

Moraschini V1, Barboza Ed2. Success of dental implants in smokers and non-smokers: a systematic review and meta-analysis. Int J Oral Maxillofac Surg. 2016 Feb;45(2):205-15.

Morris MF, Kirkpatrick TC, Rutledge RE, Schindler WG. Comparison of nonsurgical root canal treatment and single-tooth implants. J Endod. 2009;35(10):1325-30.

Naert I, Koutsikakis G, Duyck J, Quirynen M, Jacobs R, van Steenberghe D. Biologic outcome of implant- supported restorations in the treatment of partial edentulism. part I: a longitudinal clinical evaluation. Clin Oral Implants Res. 2002;13(4):381-9

Naert I1, Duyck J, Vandamme K.Occlusal overload and bone/implant loss. Clin Oral Implants Res. 2012 Oct;23 Suppl 6:95-107.

Nkenke E, Stelzle F. Clinical outcomes of sinus floor augmentation for implant placement using autogenous bone or bone substitutes: a systematic review. Clin. Oral Impl. Res. 20 (Suppl. 4), 2009; 124-133.

Ong CT, Ivanovski S, Needleman IG, Retzepi M, Moles DR, Tonetti MS, Donos N. Systematic review of implant outcomes in treated periodontitis subjects. J Clin Periodontol. 2008;35(5):438-62.

Papaspyridakos P, Chen CJ, Chuang SK, Weber HP.Implant loading protocols for edentulous patients with fixed prostheses: a systematic review and meta-analysis.Int J Oral Maxillofac Implants. 2014; 29 Suppl:256- 70.

Pjetursson BE, Bragger U, Lang NP, Zwahlen M. Comparison of survival and complication rates of tooth- supported fixed dental prostheses (FDPs) and implant-supported FDPs and single crowns (SCs). Clin Oral Implants Res. 2007;18 Suppl 3:97-113.

Pjetursson BE, lang NP. Prosthetic treatment planning on the basis of scientific evidence. J Oral Rehabil. 2008;35 Suppl 1:72-9.

Pjetursson BE, Tan WC, Zwahlen M, lang NP. A systematic review of the success of sinus floor elevation and survival of implants inserted in combination with sinus floor elevation. J Clin Periodontol. 2008;35(8 Suppl):216-40.

Quirynen M, Abarca M, Van Assche N, Nevins M, van Steenberghe D. Impact of supportive periodontal therapy and implant surface roughness on implant outcome in patients with a history of periodontitis. J Clin Periodontol 2007;34(9):805-15.

Quirynen M, Van Assche N, Botticelli D, Berglundh T. How does the timing of implant placement to extraction affect outcome? Int J Oral Maxillofac Implants 2007;22 Suppl:203-23.

Rasmusson l, Roos J and Bystedt H. A 10-year follow-up study of titanium dioxide-blasted implants. Clin Implant Dent Relat Res, 2005; 7:36-42.

Renvert S, Persson GR. Periodontitis as a potential risk factor for peri-implantitis. J Clin Periodontol 2009;36 Suppl 10:9-14

Ripamonti CI, Maniezzo M, Campa T, Fagnoni E, Brunelli C, Saibene G, Bareggi C, Ascani l, Cislaghi E. Decreased occurrence of osteonecrosis of the jaw after implementation of dental preventive measures in solid tumour patients with bone metastases treated with bisphosphonates. The experience of the National Cancer Institute of Milan. Ann Oncol 2009 Jan;20(1):137-45.

Rocchietta I, Fontana F, Simion M. Clinical outcomes of vertical bone augmentation to enable dental implant placement: a systematic review. J Clin Periodontol. 2008;35(8 Suppl):203-15.

Roccuzzo M, Aglietta M, Cordaro l. Implant loading protocols for partially edentulous maxillary posterior sites. Int J Oral Maxillofac Implants. 2009;24 Suppl:147-57.

Romeo E, Chiapasco M, Ghisolfi M, Vogel G. long-term clinical effectiveness of oral implants in the treatment of partial edentulism. Seven-year life table analysis of a prospective study with ITI dental implants system used for single-tooth restorations. Clin Oral Implants Res. 2002;13(2):133-43.

Sahin S, Cehreli MC, Yalçin E. The influence of functional forces on the biomechanics of implant-supported prostheses--a review. J Dent. 2002;30(7-8):271-82.

Sailer I, Muhlemann S, Zwahlen M, Hammerle CH, Schneider D. Cemented and screw-retained implant reconstructions: a systematic review of the survival and complication rates.Clin Oral Implants Res. 2012 Oct; 23 Suppl 6:163-201.

Salvi GE, Bragger U. Mechanical and technical risks in implant therapy. Int J Oral Maxillofac Implants. 2009;24 Suppl:69-85.

Salvi GE, Zitzmann NU, The effect of anti-infective preventive measures on the occurrence of biologic complications and implant loss: A systematic Review. Int J Oral Maxillofac Impl 2014: 29 (suppl) 292-307

Sanz M, Naert I; Working Group 2. Biomechanics/risk management (Working Group 2). Clin Oral Implants Res. 2009;20 Suppl 4:107-11.

Sanz-Sanchez I, Ortiz-Vigon A, Sanz-Martin I, Figuero E, Sanz M. Effectiveness of lateral bone augmentation on the alveolar crest dimension: A systematic review and meta-analysis. J Dent Res 2015 94 (9 suppl) 128S- 142S.

Schimmel M, Srinivasan M, Herrmann FR, Muller F. Loading protocols for implant supported overdentures in the edentulous jaw: a systematic review and meta-analysis. Int J Oral Maxillofac Implants 2014 29 Suppl 271- 286

Schou S, Holmstrup P, Worthington HV, Esposito M. Outcome of implant therapy in patients with previous tooth loss due to periodontitis. Clin Oral Implants Res. 2006;17 Suppl 2:104-23.

Schou S. Implant treatment in periodontitis-susceptible patients: a systematic review. J Oral Rehabil. 2008;35 Suppl 1:9-22.

Schrott A, Riggi-Heiniger M, Maruo K, Gallucci GO. Implant loading protocols for partially edentulous patients with extended edentulous sites--a systematic review and meta-analysis. Int J Oral Maxillofac Implants. 2014; 29 Suppl:239-55.

Scully C, Hobkirk J, Dios PD. Dental endosseous implants in the medically compromised patient. J Oral Rehabil. 2007 Aug;34(8):590-9.

Sennerby L, Gottlow J. Clinical outcomes of immediate/early loading of dental implants. A literature review of recent controlled prospective clinical studies. Aust Dent J. 2008;53 Suppl 1:S82-8.

Smith DE, Zarb GA.. Criteria for success of osseointegrated endosseous implants. J Prosthet Dent. 1989;62(5):567-72.

Sousa V, Mardas N, Farias B, Petrie A, Needleman I, Spratt D, Donos N. A systematic review of implant outcomes in treated periodontitis patients.Clin Oral Implants Res. 2015 Sep 18. doi: 10.1111/clr.12684. [Epub ahead of print}

Subramani K, Jung RE, Molenberg A, Hammerle CH. Biofilm on dental implants: a review of the literature. Int J Oral Maxillofac Implants. 2009;24(4):616-26.

Tan WC, Lang NP, Zwahlen M, Pjetursson BE. A systematic review of the success of sinus floor elevation and survival of implants inserted in combination with sinus floor elevation. Part II: transalveolar technique. J Clin Periodontol. 2008;35(8 Suppl):241-54.

Thomas MV, Beagle JR. Evidence-based decision-making: implants versus natural teeth. Dent Clin North Am. 2006;50(3):451-61.

Thomason JM, Heydecke G, Feine JS, Ellis JS. How do patients perceive the benefit of reconstructive dentistry with regard to oral health-related quality of life and patient satisfaction? A systematic review. Clin Oral Implants Res. 2007;18 Suppl 3:168-88.

Thomason JM. The Use of Mandibular Implant-retained Overdentures Improve Patient Satisfaction and Quality of Life. J Evid Based Dent Pract. 2010;10(1):61-63.

TOMASI, C., WENNSTROM, J. L., & BERGLUNDH, T. (2008). Longevity of teeth and implants - a systematic review. Journal of oral rehabilitation, 35 suppl 1, 23

Tonetti MS, Hammerle CH; European Workshop on Periodontology Group C. Advances in bone augmentation to enable dental implant placement: Consensus Report of the Sixth European Workshop on Periodontology. J Clin Periodontol. 2008;35(8 Suppl):168-72.

Torabinejad M, Anderson P, Bader J, Brown LJ, Chen LH, Goodacre CJ, Kattadiyil MT, Kutsenko D, Lozada J, Patel R, Petersen F, Puterman I, White SN. Outcomes of root canal treatment and restoration, implant- supported single crowns, fixed partial dentures, and extraction without replacement: a systematic review. J Prosthet Dent. 2007;98(4):285-311.

Tschernitschek H, Borchers L, Geurtsen W. Nonalloyed titanium as a bioinert metal--a review. Quintessence Int. 2005;36(7-8):523-30.

Van der Weijden,GA, van Bemmel KM, Renvert S. Implant therapy in partially edentulous, periodontally compromised patients: a review. J Clin Periodontol. 2005;32(5):506-11.

Vazquez L, Saulacic N, Belser U, Bernard JP. Efficacy of panoramic radiographs in the preoperative planning of posterior mandibular implants: a prospective clinical study of 1527 consecutively treated patients. Clin Oral Implants Res. 2008;19(1):81-5.

Vigolo P, Mutinelli S, Zaccaria M, Stellini E. Clinical evaluation of marginal bone level change around multiple adjacent implants restored with splinted and nonsplinted restorations: a 10-year randomized controlled trial. Int J Oral Maxillofac Implants. 2015 Mar-Apr;30(2):411-8.

Vigolo P, Mutinelli S, Givani A, Stellini E. Cemented versus screw-retained implant-supported single-tooth crowns: a 10-year randomised controlled trial. Eur J Oral Implantol. 2012 Winter;5(4):355-64.

Wallace SS, Froum SJ. Effect of maxillary sinus augmentation on the survival of endosseous dental implants. A systematic review. Ann Periodontol. 2003;8(1):328-43.

Weber HP, Sukotjo C. Does the type of implant prosthesis affect outcomes in the partially edentulous patient? Int J Oral Maxillofac Implants. 2007;22 Suppl:140-72.

Wittneben JG, Millen C, Bragger U. Clinical performance of screw- versus cement-retained fixed implant- supported reconstructions--a systematic review. Int J Oral Maxillofac Implants. 2014; 29 Suppl:84-98.

Yanase RT, Bodine RL, Tom JF, White SN. The mandibular subperiosteal implant denture: a prospective survival study. J Prosthet Dent. 1994 Apr;71(4):369-74.

Zangrando MS, Damante CA, Sant'Ana AC, Rubo de Rezende ML, Greghi SL, Chambrone L. Long-term evaluation of periodontal parameters and implant outcomes in periodontally compromised patients: a systematic review. J Periodontol. 2015 Feb;86(2):201-21.

Zimmer CM, Zimmer WM, Williams J, Liesener J. Public awareness and acceptance of dental implants.Int J Oral Maxillofac Implants. 1992;7(2):228-32.

Zitzmann NU, Margolin MD, Filippi A, Weiger R, Krastl G. Patient assessment and diagnosis in implant treatment. Aust Dent J. 2008;53 Suppl 1:S3-10.

GNATHOLOGY

Gnathology is the branch of dentistry that focuses on the diagnosis and treatment of a wide group of clinical conditions, disorders and pathologies which cause abnormalities in the sensitivity and/or movements of the stomatognathic system. Some of the above-mentioned conditions present with signs and symptoms in comorbidity with other functional districts and systems that, even if not directly linked to everyday dental practice, force the dentist to have a pivotal role within complex differential diagnosis pathways, which may require the involvement of other medical specialists.

In the field of gnathology, the pathologies that are more frequently faced by dentists are temporomandibular disorders (TMDs), non-odontogenic orofacial pain, parafunctions, bruxism, as well as sleep movement and respiratory disorders, including obstructive sleep apnea.

Gnathology studies the static, dynamic, functional, parafunctional, dysfunctional and pathological relationship between teeth (i.e., dental occlusion), temporomandibular joints (TMJs) and the neuromuscular correlates which are involved in movements of mouth and tongue. In particular, it deals with the knowledge, study and management of dental occlusion also in terms of the relationship with other dental branches. The clinical conditions, diagnostic analyses (both clinical and instrumental) and the gnathological therapeutical management of occlusion must be considered as fundamental cultural heritage of dentistry. One must highlight that gnathological principles should be applied transversally in every dental discipline which deals with modifying and reconstructing occlusion (orthodontics, prosthodontics, conservative treatments), from the simplest to the most complex patient.

Temporomandibular disorders

TMDs include a group of painful and/or dysfunctional conditions which may be of inflammatory or degenerative nature and which affect the temporomandibular joints, the jaw muscles, and the related structures which are in anatomic and functional relationship with them (Scrivani 2008).

The most frequent signs and symptoms are pain, altered and limited mandibular movements and joint sounds. In some cases, there is an acute onset, with symptoms of different severity that often evolve positively spontaneously. In other cases, a chronic condition develops, with persistent pain and a variety of physical, behavioral, psychological, and psychosocial symptoms similar to those of patients affected by chronic pain.

The most frequent conditions which are clinically observed are muscle (myofascial) pain, disc displacement (with or without reduction), and arthrosis (Schiffman 2014).

The etiology of temporomandibular disorders is biopsychosocial.

For diagnostic purposes,the most widely diffused international criteria are:

-The International Association for the Study of Pain (IASP);

-The International Headache Society (IHS) (The International Headache Classification: ICHD-II) (Cephalalgia 2005)

-The American Academy of Orofacial Pain (De Leeuw 2008);

-The Research Diagnostic Criteria for Temporomandibular Disorders (RDC/TMD), which evolved into the DC/TMD (Diagnostic Criteria for Temporomandibular Disorders - 2014; http://www.rdc-tmdinternational.org/tmdassessmentdiagnosis/dctmd.aspx). The (R)DC/TMD must be considered the reference classification system (Schiffman 2014).

For the diagnosis, medical history and clinical assessment are fundamental. It is nonetheless important to exclude other possible causes of movement impairment, and altered oral-mandibular function, such as dental pathologies (e.g., caries, periodontal diseases), tumors (e.g., maxillary, intracranial, skull basis), pathologies of other facial structures (e.g, salivary glands), primary and secondary headaches, trigeminal neuropathy, and systemic disorders (e..g., temporalis arteritis, rheumatoid arthritis, connective tissue diseases).

Anamnesis should focus on pain especially in case of chronic pain, and it must include an evaluation of psychosocial aspects.

Clinical examination should provide an intraoral examination, paying particular attention to dental and occlusal aspects, as well as an evaluation of jaw movements both quantitatively and qualitatively (observation of opening and closing and measuring the opening and lateral ranges of movement). In addition, joint sounds evoked with jaw movement should be recorded because of their importance to diagnose disc displacements and arthrosis. And finally, jaw muscle palpation and inspection is needed. In view of the many conditions that may have similar clinical signs and symptoms, the clinical examination should include also neck palpation and an evaluation of cranial nerves.

Additional examinations are required based on the need to confirm or get deeper into the clinical suspicion which emerges from anamnesis and clinical examination.

Orthopantomography is the basic, most useful and immediate instrument for screening. Diagnostic assessment of hard tissues can be achieved with Computerized Tomography (CT, also "Cone Beam"), whilst plain TMJ radiology is obsolete. Bone scintigraphy should be reserved for growth or developmental abnormalities. Magnetic Resonance Imaging (MRI) allows to study the articular disc, intra-articular fluids, condylar vascularization and, in general, articular and periarticular soft tissues and haw muscles. One should bear in mind that further diagnostic screening must be carefully prescribed by the clinician and must be executed only if the outcome may influence the therapeutic approach (Gonzalez 2008).

When considering therapy, data from the scientific literature support, in the majority of TMDs, a conservative, reversible, non-invasive, non-surgical approach (Greene 2015, Carlsson 2009). In

particular: *counseling* - information, reassurance, lowering of functional demands (ie parafunction control), physical therapy and physiotherapy, drugs (e.g., non-steroidal anti-inflammatory drugs, myorelaxants, tricyclic antidepressants for short periods), intraoral devices (i.e., oral splints – without any evidence of superiority of any particular design. One should opt for an individually-designed appliance with personalized instructions and careful monitoring of the patient) (Klasser 2009).

On the contrary, invasive/surgical treatments should be reserved to irreversible, painful structural changes of the TMJs that do not respond to conservative treatments. In such cases, there is a wide variety of procedures, ranging from minor (i.e., arthrocentesis) to major surgery (i.e., open surgery) (Guo 2009). Such procedures are not frequently needed but it is useful to know that the clinical conditions which most often require invasive/surgical treatment are disc displacement without reduction and arthrosis.

The etiology of TMDs has not been fully clarified yet. There is no up-to-date evidence showing that malocclusions, tooth loss and occlusal interferences may directly cause temporomandibular disorders.

In the case of patients with TMD symptoms who also require or ask for occlusal treatment for prosthetic or orthodontic needs, TMD symptoms should be solved first by means of reversible therapy. For example, in case of a prosthetic rehabilitation, the clinician should adopt resin provisional restorations until the occlusal and symptomatic stability is obtained.

Patients with chronic pain, independently by its source, should be referred to specialist centers. When a patient presents with a disc displacement without reduction and acute articular luxation, one should urgently attempt at unlocking the joint and promptly refer the patient to expert and trained operators.

For the diagnosis of temporomandibular disorders it is important to rule out other causes of orofacial pain or jaw movement/oromandibular function alterations.

The wide majority of temporomandibular disorders can be managed with conservative, reversible, non-invasive, non-surgical approaches.

In the case of structural painful and irreversible TMJ disorders that do not respond to conservative treatments, surgical/invasive options can be considered.

When a patient is affected by TMJ dysfunction and a prosthetic/orthodontic treatment is also needed, the temporomandibular disorders are the ones that should be treated first.

Orofacial pain

Pain in the oral and facial area has a relevant impact from a biopsychosocial viewpoint; it has a 17-26% prevalence within the general population, with 7-11% of people showing chronic pain. Orofacial pain of non-dental origin can be due to several conditions affecting nearby structures or distant districts from the oral cavity and can have musculoskeletal, neurological or vascular origin (Rebnton 2012).

Sources of orofacial pain can be located in:

- Muscles/ligaments/soft tissues (e.g., TMJ pain, facial arthromyalgia, myofascial pain, idiopathic/atypical orofacial pain, salivary glands pathologies, optical nerve neuritis, burning mouth syndrome, candidiasis, tumors -both malignant and benign-, pathologies of the maxillary sinus, of the nasopharynx, of the central nervous system, etc)
- Dento-alveolar structures (e.g., dentinal pathologies, periodontal disease, maxillary sinusitis, atypical dental pain, etc)
- Neurological/vascular structures (e.g., trigeminal neuralgia, glossopharyngeal neuralgia, recurrent headache, post-herpetic neuralgia, cranial arteritis, pre-trigeminal neuralgia, Ramsay-Hunt syndrome)

Differential diagnosis requires knowledge, experience and skills, with particular regard to history taking.

A thorough examination of pain involves features of time onset, intensity, location, duration, quality, frequency, precipitating and relieving factors, as well as associated signs and symptoms.

Risk factors for orofacial pain chronicity are: widespread pain, female gender, age, and psychological features. In particular, all painful conditions, even if located at other body districts, may be comorbid with orofacial pain.

Thus, for the general dentist, differential diagnosis may be a concern. For such reason, it is recommended that, when chronic orofacial pain is not ascribable to an easily diagnosable TMD in a straightforward manner, the patient is referred to specialist centers/clinicians for proper treatment

Orofacial pain may be due to several conditions, the differential diagnosis of which are often beyond the clinical skills of an average general dentist. Thus, (s)he has to cooperate with non-dental colleagues during the diagnostic pathway, especially when facing patients with chronic pain.

The primary target should be pain control and avoidance of chronic pain onset.

Parafunctions and Bruxism

Parafunctions are conditions which show a high prevalence in the general population. They may occur during sleep or when awake, and it is essential to distinguish the essential forms – which are more common- from the secondary ones. The latter are mainly linked to the use of drugs (e.g., SSRI) or substances (e.g., cocaine, amphetamine, ecstasy) but also to neurological or psychiatric conditions. Management of secondary parafunctions is achieved by cooperating with the general practitioner.
Diagnosis of parafunctions is important for the management of TMDs and to avoid complications in case of prosthodontic (especially when implants or reduce periodontal support are present) and orthodontic rehabilitations.
The relationship of bruxism with TMDs is a matter of debate, Nonetheless, it is quite obvious that controlling clenching-related overload in a patient with TMD has a fundamental role in the treatment regimen as it reduces the load on muscoloskeletric structures of the stomatognathic system and must, therefore, be taken into account by the clinician.
Parafunctions represent a group of para-physiological oral activities, that is to say, activities which are not meant to satisfy the so-called primary needs for which the masticatory system is needed (swallowing, speech, chewing, oro-facial posture etc). They are involuntary and affect about 20% of the population, with a higher prevalence of awake parafunctions with respect to sleep parafunctions.
The most common wake parafunctions are clenching and grinding. Vicious habits such as lip and nail biting, holding objects in between dental arches, leaning on one's chin, thumb sucking, tongue and lip movements and performing mandibular movements are all performed with no functional utility and prove to be of interest for the dental practitioner.
In dentistry, bruxism is particularly important for the effects it can have on teeth, periodontium and generally on the oral cavity. Clenching and grinding are forms of bruxism. The definition is as follows: bruxism is an oral condition which is characterized by a "repetitive activity of masticatory muscles which manifests itself as clenching or grinding of teeth and/or maintenance of the mandible in a fixed position with contracted muscles, even in absence of dental contact"t. Bruxism has two distinct circadian manifestations: awake and sleep bruxism (Lobbezoo 2013).

Awake bruxism diagnosis is based on medical history and clinical assessment. This allows for a high margin of error, but at present, we lack adequate instruments for on-time monitoring of masticatory muscles when awake.

Awake parafunctions and bruxism can be mistaken for other movements which are related to neurological conditions: dystonias, dyskinesia, etc. A fundamental diagnostic criterium is how voluntarily controllable the movement is.

Bruxism and other awake parafunctions are managed by means of behavioural interventions: educating the patient and behavioural treatment rationale, presentation of the role played by stress and by negative psychological factors which may exacerbate and maintain it, self-monitoring parafunctional behaviours and developing a personal management plan.

Sleep bruxism is to some extent independent from awake bruxism. Prevalence of sleep bruxism is around 8% in the general adult population. Medical history, clinical data (such as tooth wear) and typical symptoms – possibly confirmed by relatives- are needed for the diagnosis of sleep bruxism. It is important to underline how such a diagnosis can show a margin of error ("possible" or "probable" bruxism, whether it is based only on anamnestic data or integrated with clinical evaluation). It is fundamental to have a third person confirm episodes of sleep bruxism, as self-report alone is not reliable and therefore insufficient under a diagnostic perspective. Polysomnography (PSG) does provide a firm diagnosis, but such an exam cannot be performed in a dental clinic, due to the unfavorable cost/benefit ratio. This must also be related to the fact that bruxism does not significantly compromise sleep (Macaluso, 1998). The use of portable devices is not justified.

Treatment is based on conservative management including oral splints plus a cognitive-behavioural approach and, in severe cases, drug therapy for short periods (Manfredini, 2015). Our therapeutic goal as dentists, in those cases of no comorbidity with TMDs or other pathologies, is to prevent tooth damage and to reduce discomfort for relatives living with the patient (in terms of sounds). When considering shape and design there are no clear indications which direct towards the choice of one particular splint or another, but one should opt for individually manufactured ones and such devices should be adequately robust.

As an important remark, it should be noticed that oral appliances do not make an individual stop bruxing, and that in some cases(patients who snore or are affected by OSAS) they could even increase an associated apnea.

Bruxism and parafunctional habits secondary to drugs and substances should be ruled out anamnestically. Diagnosis is based on history and clinical evaluation.

Awake parafunctions and awake bruxism should be managed with cognitive-behavioural approaches mainly

Oral appliances for sleep bruxism are indicated to prevent tooth wear and to reduce grinding sounds. In patients with comorbid sleep apnea, caution due to the possible worsening of apnea is recommended.

Sleep respiratory disturbances: snoring and obstructive sleep apnea

For such section pleae refer to "National guidelines for prevention and dental treatment of OSAS http://www.salute.gov.it/imgs/C_17_pubblicazioni_2484_allegato.pdf

Temporomandibular disorders in the pediatric age

Temporomandibular disorders are more frequent in adults, but some signs and symptoms can be present in children (16-68%) and adolescents as well. The high variability of prevalence data is due to the lack of methodological homogeneity across the various studies on the topic and to the lack of coordination when adopting diagnostic criteria in the young.

In the pediatric age, females are more frequently affected by TMDs than males (Magnusson, 2005), to the point that gender is considered a risk factor for the onset of TMDs (LeResche, 2007). Disc displacement and facial pain of different nature are the most frequent conditions observed during adolescence (Magnusson 2005; Michelotti 2016). An association has been sometimes found with vicious habits such as nail biting and signs/symptoms of TMD, thus indicating the need to eradicate such habits early on in life. The approach to the management of TMDs in adolescents is not different from adults, especially considering that signs and symptoms are poorly correlated with features of dental occlusion or skeletal characteristics and to the need of an orthodontic treatment (Manfredini, 2016).

In short, temporomandibular disorders in childhood and adolescence should be diagnosed and managed based on the same principles than adulthood (Wahlund, 2015).

Three conditions deserve special focus in the youngsters: fractures, juvenile rheumatoid arthritis, and bruxism.

- Fractures

Condylar fractures account for about 26-40% of mandibular fractures. The higher incidence of condylar fractures in children than adults may be explained by the unfavorable bone marrow-cortical ratio in children, who have only a thin cortical layer. The prevalence of condylar fractures is likely underestimated because of the mild symptoms that often accompany them. The most frequent clinical signs are soft tissue lesions (abrasions, chin lesions) that are present in a different area with respect to the area of the fracture (indirect trauma). Besides, facial asymmetry with chin deflection, pain and swelling in the affected TMJ area, post-traumatic malocclusion with incisor midline deflection toward

the affected side in case of monolateral fractures, contralateral posterior open bite when fracture is monolateral or anterior open bite when the fracture is bilateral, antalgic muscle contracture with reduced jaw opening.

The most severe consequence of untreated or undiagnosed fractures is bone ankylosis, with functional impairment and abnormality of skeletal growth which gives rise to dento-skeletal malformations. The dentist has to intercept such a negative evolution and refer the patient to a maxillo-facial surgeon. Other less severe consequences can be: face asymmetry, with mandible deflection toward the affected side in monolateral fractures, or anterior open bite with micrognathia in bilateral cases, progressive limitation of jaw movements, asymmetry of jaw movements, loss of vertical dimension of occlusion, occlusal plane inclination, weakness of jaw muscles from the affected side, degenerative joint disease. Children between 8 and 12 years of age can have a progressive adaptation of the condyle or a compensation within 2-3 years from trauma.

Treatment is based on cycles of functional, orthodontic-gnathological-orthopedic appliances and physiotherapy, and aims at: restoring jaw function, restoring a stable occlusion, and controlling growth of the skull basis which must be symmetrical. The choice of treatment device is conditioned by the clinical assessment and skeletal features of the patient. Within the first year of treatment, full symptom remission should be achieved, to promote a physiological bone growth. Sometimes, functional therapies can be reactivated for short periods of times. In children aged under 8 years, the need for surgical reduction of the fracture is rare.

- Juvenile rheumatoid arthritis

It is the most frequent arthritis of the pediatric age, and it may affect the temporomandibular joint, with intra- and extra-oral changes. Pain can be absent. Among the most frequent orofacial impairments, there are: retrognathia, micrognathia, anterior open bite, facial asymmetry, and jaw functional limitation. The rheumatologist has a key role in the early diagnosis, and should refer the young patient to the dentist for an evaluation. Sometimes, diagnosis should be suspected by the dentist, based on clinical examination and imaging. Treatment is multidisciplinary, involving the rheumatologist as the main figure. Along with addressing the primary disease, treatment should be directed to pain management (if present) and to orthodontic treatment. Physical therapy and speech therapy could be useful complementary strategy to improve function.

- Bruxism in children

Bruxism in children may have a physiological meaning, but it can also be a warning sign of emotional distress (Emodi-Perlman 2012). Sleep bruxism shows a comorbidity with sleep respiratory disturbances. Thus, if the parent refers teeth grinding, the child should also be evaluated for snoring and obstructive sleep apnea (Carra, 2011). Anamnesis can be taken by means of questionnaires to be filled

out by parents. Children with respiratory disorders usually have peculiar facial features, including adenois facies, reduced maxillary arch width, ogival palatal vault, small and retruded mandible, long face, crossbite, increased overjet and oral breathing. It is thus important to plan for an orthodontic evaluation (Alexander, 2013).

Bibliography

Scrivani SJ, Keith DA, Kaban LB. Temporomandibular Disorders. N Engl J Med 2008;359:2693-705.

Schiffman E, Ohrbach R, Truelove E, Look J, Anderson G, Goulet Jp, List T, Svensson P, Gonzalez Y, Lobbezoo F, Michelotti A, Brooks Sl, Ceusters W, Drangsholt M, Ettlin D, Gaul C, Goldberg Lj, Haythornthwaite Ja, Hollender L, Jensen R, John Mt, De Laat A, De Leeuw R, Maixner W, Van Der Meulen M, Murray Gm, Nixdorf Dr, Palla S, Petersson A, Pionchon P, Smith B, Visscher Cm, Zakrzewska J, Dworkin Sf; International RDC/TMD Consortium Network, International Association For Dental Research; Orofacial Pain Special Interest Group, International Association For The Study Of Pain. Diagnostic Criteria For Temporomandibular Disorders (DC/TMD) for clinical and research applications: Recommendations ff the International RDC/TMD Consortium Network And Orofacial Pain Special Interest Group†. J Oral Facial Pain Headache. 2014 Winter;28(1):6-27.*

Headache Classification Subcommittee of the International Headache Society (IHS). The International Classification of Headache Disorders, 2nd Edition, 1st revision (ICHD-IIR1). Cephalalgia 2004; 24 suppl 1: 1-160 (1st revision: Cephalalgia 2005; 25: 460-465).

de Leeuw R (Editor). The American Academy of Orofacial Pain. Orofacial Pain: Guidelines for Assessment, Diagnosis, and Management, Fourth Edition. Quintessence Publishing, Chicago, 2008.

Gonzalez YM, Greene CS, Mohl ND. Technological devices in the diagnosis of temporomandibular disorders. Oral Maxillofac Surg Clin North Am. 2008 May;20(2):211-20.

Greene Cs, Obrez A. Treating temporomandibular disorders with permanent mandibular repositioning: is it medically necessary? Oral Surg Oral Med Oral Pathol Oral Radiol 2015; 119: 489-98.

Carlsson GE. Critical review of some dogmas in prosthodontics. J Prosthodont Res. 2009 Jan;53(1):3-10.

Klasser GD, Greene CS. Oral appliances in the management of temporomandibular disorders. Oral Surg Oral Med Oral Pathol Oral Radiol Endod. 2009 Feb;107(2):212-23.

Guo C, Shi Z, Revington P. Arthrocentesis and lavage for treating temporomandibular joint disorders. Cochrane Database of Systematic Reviews 2009, Issue 4.

Renton T, Durham J, Aggarwal VR. The classification and differential diagnosis of orofacial pain. Expert Rev. Neurother. 2012;12(5), 569–76.

Aggarwal VR, Lovell K, Peters S, Javidi H, Joughin A, Goldthorpe J. Psychosocial interventions for the management of chronic orofacial pain (Review) The Cochrane Library 2011, Issue 1

Lobbezoo F, Ahlberg J, Glaros AG, Kato T, Koyano K, Lavigne GJ, de Leeuw R, Manfredini D, Svensson P, Winocur E. Bruxism defined and graded: an international consensus. J Oral Rehabil. 2013 Jan;40(1):2-4.

Macaluso GM, Guerra P, Di Giovanni G, Boselli M, Parrino L, Terzano MG. Sleep bruxism is a disorder related to periodic arousals during sleep. J Dent Res 1998; 77: 565-73.

Manfredini D, Ahlberg J, Winocur E, Lobbezoo F. Management of sleep bruxism in adults: a qualitative systematic literature review. J Oral Rehabil. 2015; 42: 862-874.

American Academy of Sleep Medicine. International Classification Of Sleep Disorders – Third Edition (ICSD-3)- Update 2014

Zhu Y, Long H, Jian F, Lin J, Zhu J, Gao M, Lai W. The effectiveness of oral appliances for obstructive sleep apnea syndrome: A meta-analysis.Volume 43, Issue 12, December 2015, Pages 1394–1402.

Magnusson T, Egermarki I, Carlsson GE: A prospective investigation over two decades on signs and symptoms of temporomandibular disorders and associated variables. A final summary. Acta Odontol Scand 2005; 63:99-109.

LeResche L, Mancl LA, Drangsholt MT, Huang G, Von Korff M: Predictors of onset of facial pain and temporomandibular disorders in early adolescence. Pain 2007; 129:269-278.

Michelotti A, Iodice G, Piergentili M, Farella M, Martina R. Incidence of temporomandibular joint clicking in adolescents with and without unilateral posterior cross-bite: a 10-year follow-up study. J Oral Rehabil. 2016 Jan;43(1):16-22

Manfredini D, Stellini E, Gracco A, Lombardo L, Nardini LG, Siciliani G. Orthodontics is temporomandibular disorder-neutral. The Angle Orthodontist: July 2016, Vol. 86, No. 4, pp. 649-654.

Wahlund K, Nilsson IM, Larsson B. Treating temporomandibular disorders in adolescents: a randomized, controlled, sequential comparison of relaxation training and occlusal appliance therapy. J Oral Facial Pain Headache. 2015; 29: 41-50.

Emodi-Perlman A, Eli I, Friedman-Rubin P, Goldsmith C, Reiter S, Winocur E. Bruxism, oral parafunctions, anamnestic and clinical findings of temporomandibular disorders in children. J Oral Rehabil 2012; 39: 126-35.

Carra MC, Huynh N, Morton P, Rompré PH, Papadakis A, Remise C, Lavigne GJ. Prevalence and risk factors of sleep bruxism and wake-time tooth clenching in a 7- to 17-yr-old population. Eur J Oral Sci. 2011; 119: 386-94.

Alexander NS, Schroeder JW Jr. Pediatric obstructive sleep apnea syndrome. Pediatr Clin North Am. 2013 Aug;60(4):827-40.

PROSTHETIC THERAPY

Prosthodontics is the dental specialty pertaining to the diagnosis, treatment planning, rehabilitation, and maintenance of the oral function, comfort, appearance, and health of patients with clinical conditions associated with missing or deficient teeth and/or maxillofacial tissues by using biocompatible substitutes.

With the **fixed prosthodontics** it is possible to restore and / or replace the teeth with artificial substitutes that can not be removed from the mouth by the patient; the **partial or total removable prosthodontics** is concerned with the replacement of teeth and contiguous structures for edentulous or partially edentulous patients by artificial substitutes that are readily removable from the mouth by the patient; **the implant prosthodontics** is concerned with the selection, planning, development, placement, replacement of missing teeth and/or associated structures, and maintenance of restoration(s) with dental implants.

The decision to make a prosthetic restoration is determined by several factors, including: the general health of the patient, the type of edentulism and the condition of the remaining teeth, the periodontal situation and the maintenance of oral hygiene, the occlusal relations and the oral function, motivation and aspirations of the patient. In the treatment planning, an analysis of the advantages, disadvantages and long-term consequences of the prosthetic treatment, an examination of the factors that lower the probability of clinical success and an estimate of the costs are indispensable.

For all the fixed prostheses, the presence of abutment teeth suitable for structure, position in the arch and prognosis is required. A fixed prosthesis can also be indicated as part of a restorative treatment involving the use of implants.

In all the situations, the advantages of prosthetic therapy must justify the treatment and counterbalance its possible disadvantages. Furthermore, the realization of a prosthesis must be undertaken only in situations in which the restorative treatment is clearly capable of improving the patient's oral and psychological health or satisfying a specific request. The replacement of incongruous prostheses must be conditioned to the understanding and effective management of the causes behind this failure.

There are numerous factors to be considered in the construction of a prosthetic rehabilitation.

The possible replacement due to failure of previously made prostheses involves a careful evaluation of the causes that could have determined it.

The decision to make a fixed prosthesis depends largely on the number, position, condition and support structures of the abutment teeth and the analysis of edentulous spaces.

A removable complete denture provides for replacement of the missing natural dentition and associated jaw structures for those patients who have already lost all their natural teeth or whose natural teeth are no longer maintainable.

Overdentures allow patients intended to carry a total prosthesis to retain one or more teeth or natural roots in order to provide, at least temporarily, a more favorable support and stability for the removable prosthesis that will be built.

Since the removable complete denture is the last therapeutic option, it must be designed and constructed in order to allow the preservation of the residual oral structures as much as possible.

The partial removable denture temporarily or permanently replaces the missing teeth keeping the remaining natural teeth as retainer of the removable structure. It is realized when the number and / or the arrangement of the residual teeth are not suitable for a fixed prosthesis. The choice between a fixed prosthesis and a removable partial denture depends to a large extent on the number, position, condition and structures of support of the abutment teeth and the analysis of edentulous spaces.

The implant prosthesis, fixed or removable, is supported and retained in part or whole by dental implants both in the total edentoulism and in the partial and in the single ones. The replacement by osseointegrated implants of one or more missing teeth is subject to the presence of quantity and quality of the bone, native or regenerated, that allow the proper positioning of the implants, in order to achieve a result more predictable and lasting as possible. The implants can also be used when the number or state of the natural elements are not suitable to support a fixed prosthesis.

Diagnosis and treatment planning

Before any prosthetic therapy, diagnosis and treatment planning are mandatory (Kornman 1987, Lang 1996, Lobene 1986, Mombelli 1992, Clark 1990).

Treatment planning allow to determine the sequence of the appropriate clinical interventions in order to achieve the therapeutic goals agreed with the patient, on the basis of his motivation, priorities and expectations (Abbott 1984, Abrams 1986, ADA 1995, Bader 1995, Friedman 1985, Hall 1994, Wilkinson 1990).

The diagnosis and planning must be based on the medical and oral anamnestic records, on an intra- and extra-oral objective examination performed with a standardized procedure to ensure the completeness of the investigation, to suggest the need for any in-depth studies, allowing uniform clinical judgment, allowing a useful collection for audit activities and serving as an opportunity for ongoing professional training (Kress 1987, Rosenberg 1988, Shugars 1995, Sondell 1997, Tedesco 1994).

Treatment planning is a fundamental point for the success of a dental treatment.

Planning must be based on a clinical examination, on the results of investigations, on an assessment of

the patient's wishes and expectations.

Although a patient-centered approach is ideal, the patient's contribution is invariably subjective; the difficulty in planning a treatment consists, therefore, in satisfying both the patient's subjectivity and the most up-to-date professional protocols related to clinical care, also bearing in mind that the patient's motivation to achieve the desired results is an important prerequisite for the effectiveness of the treatment.

A strategy aimed at the restoration of oral health must be the basis of every treatment plan.

The plan must be realistic with respect to the knowledge and experience of the dentist, the current therapeutic principles, the expected biological response, procedures and materials; it must include, whenever possible, different therapeutic options and priorities that can be determined on the basis of the medical and dental history, the patient's wishes expectations and motivation, and on the basis of expected costs, the probability of a regular attendance of scheduled appointments, of cario-receptivity, plaque control.

A prosthetic treatment plan must:

1. **express an informed and complete approach to the treatment;**
2. **include all the possible treatment options and, after having examined them, choose the most suitable for that particular patient in relation to his specific requests;**
3. **guarantee a sequence and a timing appropriate to the planned therapy;**
4. **solve the patient's current problem;**
5. **allow a return to oral health for the patient;**
6. **offer the maximum probability of long-term benefit;**
7. **evaluate the prognosis, including any side effects e complications;**
8. **minimize the risks of misunderstanding and possible litigation**
9. **foster an ongoing relationship of trust with the patient;**
10. **facilitate the planned therapy, maintenance and regular checkups;**
11. **be effective and efficient;**
12. **satisfy the patient's needs and expectations, as long as they are realistic.**

For the purpose of the longevity of a restoration, as well as for the health of natural dentition, good oral hygiene practice, periodic professional checkups and a correct therapy are decisive.

Bibliography

Abbott FB. Psychological assessment of the prosthodontic patient before treatment. Dent Clin of North Am 1984; 28: 361-367.

Abrams RA, Ayers CS, Vogt Petterson M. Quality assessment of dental restorations: a comparison by dentists and patients. Community Dent Epidemiol 1986;14: 317-319.

American Dental Association House of Delegates. Dental Practice Parameters. Parameters for oral health conditions. 1996.

Bader JD, Shugars DA. Variation in dentists' clinical decision. J Public Health Dent 1995; 55: 181-188. Chiche G, Pinault A. L'estetica nella protesi fissa anteriore. Cap. 1-2, pag. 13-52. Resch Editrice, 1995.

Di Febo G. La protesi nella malattia parodontale. in "Parodontologia" (a cura di Calandriello M, Carnevale G, Ricci G) Pag. 589, Editrice Cides Odonto. Edizioni internazionali, 1986.

Friedman JW. Development of criteria and standards for dental care. Dent Clin North Am, 1985: 29: 465-475.

Hakestam U, Karlsson T, Soderfeldt B, Rydèn O, Glantz PO. Does the quality of advanced prosthetic dentistry determine patient satisfaction? Acta Odontol Scand 1997; 55: 365-371.

Hall WB, Roberts EW, LaBarre EE. Decision making in dental treatment planning. Mosby-Year Book, 1994.

Karasneh J, Al-Omiri MK, Al-Hamad KQ, Al Quran FA. Relationship between patients' oral health-related quality of life, satisfaction with dentition, and personality profiles . J Contemp Dent Pract. 2009;10(6):49-56.

Kress G. Improving patient satisfaction. International Dental Joumal 1987; 37: 117-122.

Rosenberg MM, Kay HB, Keough BE, Holt RL. Periodontal and prosthetic management for advanced cases. Quintessence Publishing Co., 1988.

Shugars DA, D. Bader. Practice Parameters in Dentistry: Where do we stand? JADA, 1995; 126: 1134-1143.

Sondell K., Soderfeldt B. Dentist-patient communication: A review of relevant models. Acta Odontol Scand 1997; 55: 116-126.

Tedesco L, Garlapo DA. Social and economic factors in prosthodontic practice and education. Joumal of Prosthetic Dentistry 1994; 71:310-315.

Wilkinson MD. Treatment plans and cost estimates. Br Dental J 1990; 168 (12): 446-458

Preliminary exams for prosthetic treatment

Independently from which therapeutic choice is selected, it is better to collect the most complete documentation as possible.

Extraoral examination

- Observation of facial asymmetries, analysis of smile and orientation of incisal and occlusal planes
- Palpation of the temporomandibular joints and related structures, both in static and in dynamics
- Palpation of the lymphatic glands

Intraoral examination

- Examination of soft oral tissues including lips, tongue and floor of mouth
- Periodontal examination based on periodontal probing, detection of dental mobility, evaluation of oral hygiene (Almas 1986, Armitage 1996, Armitage 1995, Haffajee 1994, Kornman 1987, Lang 1996, Lobene 1986, Mombelli 1986, Mombelli 1986). Refer to the clinical recommendations in periodontology for the details of the periodontal examination.
- Systematic examination of all the surfaces of the teeth to evaluate existing restorations, caries, loss of dental substance
- Vitality test of the teeth and evaluation of needs of endodontic treatments, and of needs of retreatments
- Analisys of masticatory function and occlusion, both in maximum intercuspidation and in the lateral and protrusive mandibular movements (Ash 1995, Bell 1990, Clark 1990, Dawson 1996, Dawson 1995).
- Evaluation of the vertical dimension of occlusion (VDO)
- Evaluation of the problem reported by the patient, if he can point out a specific tooth or an area of the oral cavity
- Examination of existing restorations to assess marginal adaptation and seal, retention, function and biological acceptance
- -Evaluation of the appearance of the teeth in terms of shape and color in relation to the patient's age. Analysis of the phonation.

The study of plaster diagnostic models, possibly mounted on an articulator, is useful for the development of the treatment plan (Dawson 1989, Lytla 1990, Mc Kee 1997, Okeson 1996, Wiskott 1995).

Intraoral X-rays examinations are indicated when they represent a useful complement to the diagnosis and treatment plan (Lang 1977, Stheeman 1995, US DHHS 1988, Van der Stelt 1993*)*.

The method indicated for intraoral X-rays is the parallel beam technique with paralleling aids. The use of orthopantomography can be indicated as a possible in-depth diagnosis on the basis of clinical-anamnestic details, as well as the use of CT or "cone beam" systems (White 2008).

The use of preoperative photographic documentation, though not essential, may be helpful during the therapy.

Bibliography

Almas K, Bulman JS, Newman HN. Assessment of periodontal status with CPITN and conventional periodontal indices. J Clin Periodontol 1991; 18: 654-659.

Armitage GC. Clinical evaluation of periodontal diseases. Periodontol 2000, 1995; 39-53. Armitage GC. Periodontal Diseases: Diagnosís. Annals Periodontol 1996; 1: 37-215. Ash MM, Ramfjord SP. Occlusion. 4th ed. WB Saunders, Philadelphia, 1995.

Bell WE. Orofacial pain classification, diagnosis, management, 4th ed. Year Book Medical Publishers, Chicago, 1990.

Clark GT, Seligman DA, Solberg WK, Pullinger AG. Guidelines for the treatment of temporomandibular disorders. J Craniomandib Disord Facial Oral Pain 1990; 4: 80-88.

Curley A, Hatcher DC. Cone beam CT--anatomic assessment and legal issues: the new standards of care. J Calif Dent Assoc. 2009;37(9):653-62.

Dawson PE. A classification system for occlusions that relates maximal intercuspation to the position and condition of the temporomandibular joints. J Prosthet Dent 1996; 75: 60-66.

Haffajee AD, Socransky SS. Microbiological etiological agents of destructive periodontal diseases. Periodontology 2000 1994; 5: 66-77.

Kornman KS. Nature of periodontal diseases: Assessment and diagnosis. J Periodont Res 1987; 22: 192-204. Lang N, Hill R. Radiographs in periodontics. J Clin Periodontol 1977; 4: 16-28.

Lang NP, Tonetti MS. Periodontal diagnosis in treated periodontitis. Why, when and how to use clinical parameters. Journal of Clinical Periodontology, 1996; 23: 240-250.

Lobene RR, Weatherford T, Ross NM, Lamm RA, Menaker L. A modified ginigival index for use in clinical trials. Clin Prev Dent 1986; 8: 3-6.

Lytle JD. Clinician's index of occlusal discase: defínition, recognition and management. Int J Periodont Restorative Dent 1990; 10: 102-123.

McKee JR. Comparing condylar position repeatability for standardized versus nonstandardized methods of achieving centric relation. J Prosthet Dent 1997; 77:280-284.

Mombelli A, Graf H. Depth-force patterns in periodontal probing. J Clin Periodontol 1986; 13: 126-130.

Mombelli A, Muhle T, Frigg R. Depth-force patterns of periodontal probing. Attachment-gain in relation to probing force. J Clin Periodontol 1992; 19: 295-300.

Okeson JP, ed. Orofacial pain: Guidelines for assessment, diagnosis, and management. Quintessence Publishing Co, Chicago 1996.

Stheeman SE, van't Hof MA, Mileman PA, van der Stelt PF. Use of the Delphi technique to develop standards for quality assessment in diagnostic radiology. Community Dent Health 1995; 12: 194-199.

US Department of Health and Human Services. "The selection of Patients for Xray Examinations. Dental Radiographic Examinations". Rockville: Public Health Service Food and Drug Administrations, 1988.

Van der Stelt PF. Modern radiographic methods in the diagnosis of periodontal disease. Adv Dent Res. 1993; 7: 158- 162.

White SC. Cone-beam imaging in dentistry. Health Phys. 2008;95(5):628-37.

Clinical documentation, presentation of the treatment plan to the patient, informed consent

Before starting the treatment, it is necessary to obtain a valid consent from the patient.

For the consent to be valid, it is necessary to explain to the patient the purpose, the nature, the possible side effects, the risks and the chances of success of the treatment, not forgetting to propose possible alternatives (Ghafurian 2009, Kinderknecht 1995). It is a good practice, even if not mandatory, especially for complex rehabilitations, to preserve any documentation related to the specific clinical case.

The patient must be aware that all the information collected will be considered confidential (Hoad-Reddick 1988, Kay 1997, Newman 1995).

The ideal dental clinic documentation, depending also on the current law, should record all relevant medical / dental / social anamnesis; report any adverse reactions to products and / or materials that can be used in the dental field; record the dental, periodontal, occlusal and oral hygiene conditions of the patient; record the reason of the patient for the visit; record all the treatments performed; include radiographs and correspondence; contain an accurate note of any complaints and the action taken; record missed visits and related consequences; provide details of the interviews held with the patient, including treatments that the patient refuses or does not cooperate with; provide a means to identify the patient; indicate periodic recalls for patients (Hoad-Reddick 1988, Kay 1997).

When a patient agrees to start a treatment plan, there must be a clear agreement with the dentist, defining the aims and nature of the treatment, the patient's responsibilities, the costs and the level of effort required to ensure success. Although the agreement may be verbal or implicit, it is prudent to obtain a consensus for the sake of greater clarity for both parties.

Consent is dependent on the ability to understand and develop a clear and balanced judgment. If the treatment plan has to be changed, the changes and their implications must be clearly explained to the patient (Levine 1995). The various treatment options can be presented to the patient verbally, providing all the necessary explanations. In complex and difficult cases a clear cost exposure is mandatory, in relation to the different therapeutic options, to avoid possible misunderstandings.

In complex and difficult cases characterized by at least one of the following characteristics: techniques not commonly used in dental practice; therapies not known to most patients or difficult to understand; experimentation with new techniques and / or materials; use of biomaterials; care given to minors or mentally impaired patients, in all those cases it is better to have a written consent.
The treatment plan may include recommendations for good prosthetic device maintenance, expected outcomes and risks, various future follow-up options, number and frequency of check ups; it can also provide indications regarding the prognosis and an estimate of the presumed duration of the reconstructive works; it must also provide an accurate estimate of the immediate and long-term costs, as well as the deadlines and payment methods (Creugers 1994, Garbin 2008, Libby 1997, Scurria 1998, Valderhaug 1993, Walton 1986*).*

Bibliography

Creugers NHJ, Kayscr AF, van't Hof MA. A meta-analysis of durability data on conventional fixed bridges. Community Dent Oral Epidemiol 1994; 22: 448-452.

Garbin CA, Garbin AJ, Saliba NA, de Lima DC, de Macedo AP. Analysis of the ethical aspects of professional confidentiality in dental practice. J Appl Oral Sci. 2008 ;16(1):75-80.

Ghafurian R. Dental school patients' understanding of informed consent. J Dent Educ. 2009 ;73(12):1394-400.

Hoad-Reddick G, Grant AA. Prosthetic status: the formation of a schedule. J Prosthet Dent, January 1988.

Kay E, Locker D. Effectiveness of oral health promotion: a review. London: Health Education Authority, 1997.

Kinderknecht KE, Hìlsen KL, Attanasio R, DeSterno C. Informed consent for the prosthodontic patient with Temporomandibular Disorder. J Prosthod, 1995; 4: 205-209.

Levine RA, Shanaman RH. Translating clinical outcomes to patient value: an evidence-based treatment approach. Int J Periodontics Restorative Dent 1995; 15: 186-200.

Libby Greg, Michael R, Arcuri, William E. LaVelle, Lisa Hebl. Longevity of fixed partial dentures. Journal of Prosthetic Dentistry, 1997; 78: 127-131.

Scurria S, Bader JD, Daniel A. Meta-analysis of fixed partial denture survival: Prostheses and abutments. Joumal of Prosthetic Dentistry 1998; 79; 459-464.

Valderhaug J, Ellingsen JE, Jokstad A. Oral Hygiene, periodontal conditions and carious lesions in patients treated with dental bridges: A 15-year clinical and radiographic follow-up study. J Clin Periodontal, 1993; 20: 482-89.

Walton JN, Gardner F, Agar R. A survey of crown and fixed partial denture failures: length of service and reasons for replacement. Journal of Prosthetic Dentistry 1986; 56, 416-421.

Decision tree of prosthetic treatment

The prosthetic treatment plan can be divided into several phases, where each clinical phase results from the previous one. At the end of each phase a revaluation must be made that can also lead to a revision and / or modification of the previously established treatment.

It may be useful to schematize the sequence of the phases of the prosthetic treatment in a "decision tree".

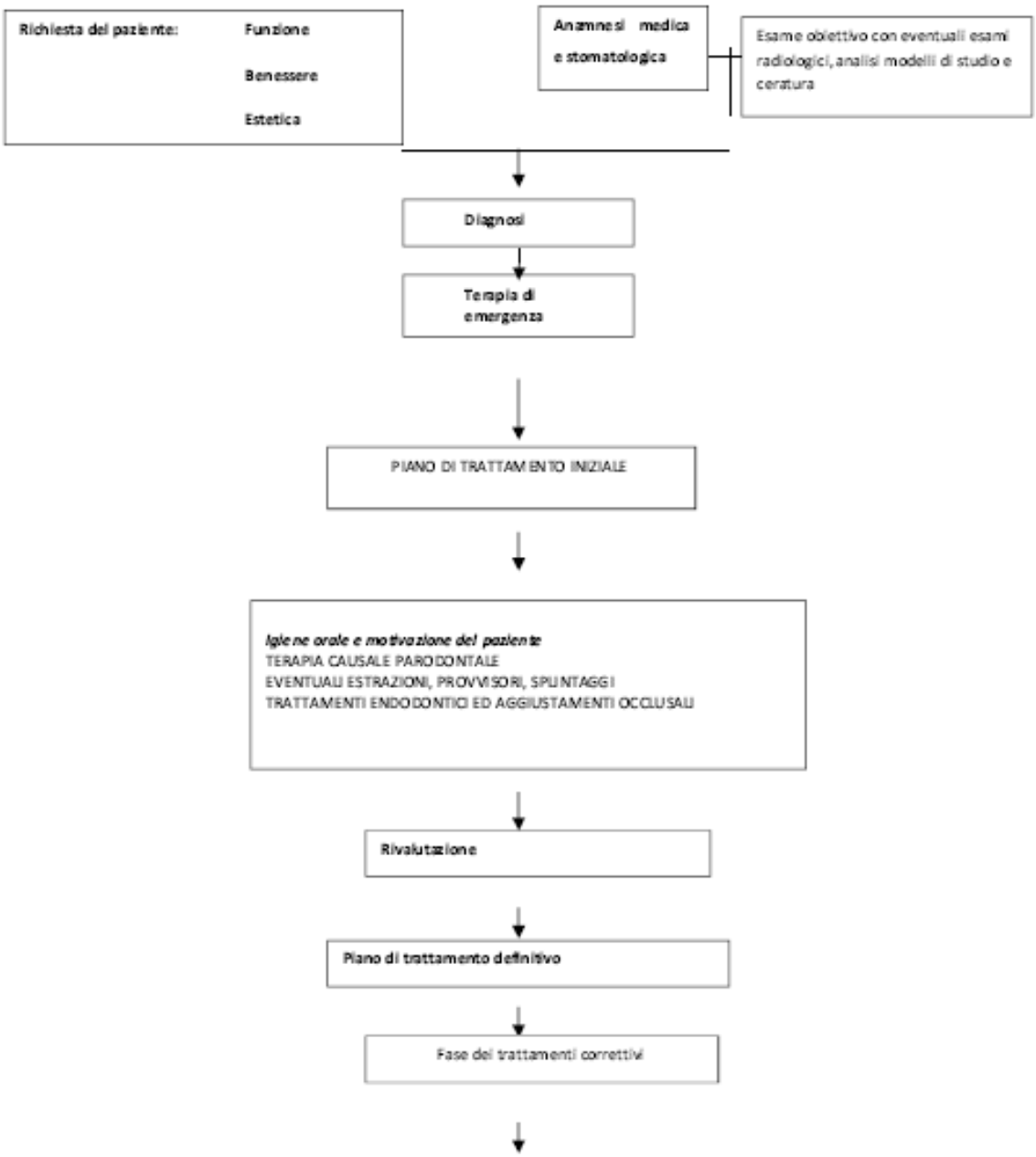

Pianificazione e terapia

della I fase correttiva

- conservativa + endodonzia
- provvisori
- chirurgia parodontale

Rivalutazione 2

Verifica del raggiungimento degli obiettivi desiderati

TERAPIA PROTESICA DEFINITIVA

Preparazioni definitive

Ribasatura e/o rimarginazione dei provvisori

Valutazioni occlusali ed estetiche finali

Impronte definitive

Registrazioni occlusali

Valutazioni della progettazione odontotecnica

Prova fusione

Prova occlusale ed estetica

Cementazione

Terapia di supporto

Occlusion in prosthetic treatment

Each prosthetic therapy requires, in the diagnostic phase, an adequate examination of the dental occlusion and of the patient's masticatory function (Beyron 1973, Carlsson 2009). In most prosthetic therapies, the static reference position of the occlusion between the antagonistic arches ("maximum intercuspation position") and the dynamic occlusal relationships not need to be changed (conformative approach) (Wassell 1998, Celenza 1984a, Celenza 1984b, , McNeill 1997, Carlsson 2009).

Specific clinical conditions may make it necessary, for the achievement of the therapeutic goals, a modification of both static and dynamic occlusal relationships (reorganizative approach) (Wassell 1998, Celenza 1984a, Celenza 1984b, McNeill 1997, Dawson 2007). As a general rule, a conformative approach is adopted: in cases in which the existing relationships allow the realization of the programmed prosthetic therapy; the residual dentition can be used as a reference for the static and dynamic aspects of the new prosthetic restoration: in the presence of occlusal ratios judged physiological (McNeill1997).

A reorganization approach is adopted in cases in which the existing relationships do not allow the execution of the planned prosthetic therapy; when the residual dentition can not be used as a reference for the development of the static and dynamic aspects of the prosthetic restoration; when other clinical and / or functional parameters evaluated by the operator performing the treatment indicate the need to reset the existing occlusal scheme (McNeill 1997).

In the presence of a maximum stable intercuspidation it is better to avoid changes on the dental surfaces not strictly involved in prosthetic therapy (Celenza 1984a). In the absence of precise reconstructive needs, interventions aimed to modify the type of disclusion present in the patient must be avoided.

In patients suffering from dysfunctional symptoms, although the prosthetic treatment may be necessary due to edentulism or dental needs, it is not the therapy of choice for the resolution of temporomandibular pathologies (De Boever 2000a, De Boever 2000b). As a general criterion, in patients presenting symptoms of temporomandibular dysfunction (chronic or acute non-dental facial pain, joint pain, muscle pain, severe restrictions of mandibular movements), prosthetic therapies should not be undertaken before a diagnosis has been made and reversible therapy has shown a stable regression of symptoms over time (De Boever 2000a, De Boever 2000b, Okeson 2008).

In clinical conditions that require a reorganizative approach, there are different techniques to register the new maxillo-mandibular static relationship. Most techniques refer to a position at the articular level ("centric relation position") (Keshvad 2000a, b, 2001, Dawson 2007, Celenza 1984b, Becker 2000).

There are numerous techniques to register the maxillo-mandibular spatial position: the choice of the method should be related to the compatibility of the registered position with an adequate function and to the reproducibility of the position itself. (McNeill 1997, Dawson 2007, Celenza 1984b).

Concerning the dynamic occlusal relationships, in treatments that involve a reorganizative approach, in general three types of therapeutic schemes are defined according to programmed eccentric contacts (McNeill 1997, Dawson 2007):

- mutually protected occlusion with canine guidance: an occlusal scheme in which the posterior teeth prevent excessive contact of the anterior teeth in maximal intercuspal position, and the anterior teeth disengage the posterior teeth in all mandibular excursive movements, with the canine on the working side guiding the lateral movement.

- group-function occlusion: multiple contact relations between the maxillary and mandibular teeth in lateral movements on the working-side whereby simultaneous contact of several teeth acts as a group to distribute occlusal forces.

- balanced occlusion: the bilateral, simultaneous occlusal contact oftheanterior andposterior teeth in excursive movements; It finds the main indication in the field of removable total denture.

The registration of the maximum intercuspal position is indicated if a conformative approach is adopted (Wassell 1998, Celenza 1984a). The registration of the mandibular position in centric relation is indicated if a reorganizative approach is adopted (Wassell 1998, Celenza 1984b). With the implants the neuromuscular control works differently from natural teeth (Klineberg 1999, Van Steenberghe 2006).
Although there are evidences of different levels of sensitivity and different mechanisms of occlusal contact control, there is currently no evidence regarding the use of specific occlusal strategies. (Gross 2008, Carlsson 2009).

A proper examination of the dental occlusion and of the patient's masticatory function is mandatory for every prosthetic therapy.

There are several materials to register the jaw relationship; they should be able to: quickly and accurately record the details of the occlusal and axio-occlusal dental surfaces; guarantee a working time adequate to position correctly the jaws, providing at the same time a rapid transition to the solid state; be dimensionally stable and cut out without deformation once hardened.
The techniques adopted for the removal, cleaning, decontamination, identification and storage procedures should not produce errors.
The clinical utility of the instrumental systems currently available for the functional evaluation of the occlusion can be evaluated according to the application field:

- diagnosis: the low sensitivity and specificity of the analysis systems makes them not significant for diagnostic purposes. None of the available systems (analysis of static relationship, mandibular movement, muscular activity, dental contacts, posture) is helpful, compared to the clinical examination (Baba 2000, Klasser & Okeson 2006, Lund 1995).
- control of the therapeutic effects: the low repeatability inhibits the possibility to compare measurements taken at different times. The hypothesis of testing the effects of prosthetic therapy by measurements is interesting, but does not find support in the literature (Tsolka 1992, Dao 1988, Lund 1995, Baba 2000, Klasser & Okeson 2006).
- prosthetic design and construction: the extra-oral reproduction of the spatial position of the occlusal table and the simulation of mandibular movements by articulators should allow a simplification of the prosthetic construction and clinical fitting. There is a large amount of literature on this topic, of a medium-low qualitative level, and contrasting conclusions (Lundeen 1978, Becker & Kaiser 1993, Carlsson 2009a, Dawson 2007, McNeill 1997, Pokorny 2008, Shillinburg 1997, Wiskott & Belser 1995, Koolstra 2002).

In prosthetic therapies involving few occlusal surfaces, the relevance of this information is poor. In prosthetic therapies involving most of the occlusal surfaces, the use of an articulator involves the setting of data regarding the spatial position and the movements of the mandible. These values can be arbitrarily set, using average data measured on population presumed to be adequate for the patient, or measured on the specific patient. There is no scientific evidence to prefer one of the methods. In the absence of evidence, the choice of the approach is empirical, based on the cost / benefit ratio according to the established goals (occlusal patterns, type of contacts, materials).

The literature concerning the comparison between electronic or computerized systems and mechanical systems does not highlight differences in data reproducibility (Kukukkles 2005, Petrie 2003).

Bibliography

Baba K, Tsukiyama Y, Clark GT. Reliability, validity, and utility of various occlusal measurement methods and techniques. J Prosthet Dent. 2000;83:83-9.

Becker CM, Kaiser DA, Schwalm C. Mandibular centricity: centric relation. J Prosthet Dent. 2000;83:158-60. Becker CM, Kaiser DA. Evolution of occlusion and occlusal instruments. J Prosthodont 1993;2:33-43. Beyron H. Occlusion: point of significance in planning restorative procedures. J Prosthet Dent. 1973;30:641-52. Carlsson GE. Critical review of some dogmas in prosthodontics. J Prosthodont Res. 2009 ;53:3-10.

Carlsson GE. Dental occlusion: modern concepts and their application in implant prosthodontics. Odontology 2009; 97:8-17.

Celenza FV. The theory and clinical management of centric positions: I. Centric occlusion. Int J Periodontics Restorative Dent. 1984;4:8-26.

Celenza FV. The theory and clinical management of centric positions: II. Centric relation and centric relation occlusion. Int J Periodontics Restorative Dent. 1984;4:62-86.

Dao TT, Feine JS, Lund JP. Can electrical stimulation be used to establish a physiologic occlusal position? J Prosthet Dent 1988; 60(4):509-14.

Dawson PE. Functional occlusion. Mosby, St. Luis, 2007.

Gross MD. Occlusion in implant dentistry. A review of the literature of prosthetic determinants and current concepts. Aust Dent J 2008; 53:S60–S68.

De Boever JA, Carlsson GE, Klineberg IJ. Need for occlusal therapy and prosthodontic treatment in the management of temporomandibular disorders. Part I. Occlusal interferences and occlusal adjustment. J Oral Rehabil. 2000 May;27(5):367-79.

De Boever JA, Carlsson GE, Klineberg IJ. Need for occlusal therapy and prosthodontic treatment in the management of temporomandibular disorders. Part II: Tooth loss and prosthodontic treatment. J Oral Rehabil. 2000 Aug;27(8):647-59.

Keshvad A, Winstanley RB. An appraisal of the literature on centric relation. Part I. J Oral Rehabil. 2000;27:823- 33.

Keshvad A, Winstanley RB. An appraisal of the literature on centric relation. Part II. J Oral Rehabil. 2000; 27:1013-23.

Keshvad A, Winstanley RB. An appraisal of the literature on centric relation. Part III. J Oral Rehabil. 2001;28:55- 63.

Klasser GD, Okeson JP. The clinical usefulness of surface electromyography in the diagnosis and treatment of temporomandibular disorders. JADA 2006;137:763-71.

Klineberg I, Murray G. Osseoperception: sensory function and proprioception. Adv Dent Res 1999; 13; 120. Koolstra JH. Dynamics of the human masticatory system. Crit Rev Oral Biol Med 2002;13:366-376 .

Kucukkles N., Ozkan H., Ari-Demirakaya A., Cilingirturk A.M. Compatibility of mechanical and computerized axiographs: A pilot study. J Prosth dent 2005; 94:190-194.

Lund JP, Widmer CG, Feine JS. Validity of diagnostic and monitoring tests used for temporomandibular disorders. J Dent Res. 1995;74:1133-43.

Lundeen HC, Shryock EF, Gibbs CH. An evaluation of mandibular border movements: their character and significance. J Prosthet Dent 1978; 40: 442-52.

McNeill C (ed.). Science and practice of occlusion. QuintessencePublishing, Chicago, 1997. Okeson JP. Management of temporomandibular disorders and occlusion. 6th edition, Mosby, St. Luis, 2008.

Petrie C.S., WoolseyG.D., Williams K. Comparison of recordings obtained with computerized axiography and mechanical pantography at 2 time intervals. J Prostodontics 2003; 12: 102-110.

Pokorny PH, Wiens JP, Litvak H. Occlusion for fixed prosthodontics: a historical perspective of the gnathological influence. J Prosthet Dent. 2008; 99:299-313.

Shillingburg HT, Hobo S, Whitsett LD. Fundamentals of fixed prosthodontics, 3rd ed., Quintessence Publishing Co., Chicago, 1997.

Tsolka P, Woelfel JB, Man WK, Preiskel HW. A laboratory assessment of recording reliability and analysis of the K6 diagnostic system. J Craniomand Disord 1992; 6:273-80.

Van Steenberghe D, Jacobs R. Jaw motor inputs originating from osseointegrated oral implants. J Oral Rehabil. 2006; 33:274-81.

Wassell RW, Steele JG, Welsh G. Considerations when planning occlusal rehabilitation: a review of the literature. Int Dent J. 1998;48:571-81.

Wiskott HW, Belser UC. A rationale for a simplified occlusal design in restorative dentistry: historical review and clinical guidelines. J Prosthet Dent. 1995;73:169-83.

Fixed prosthodontics

The fixed prostheses allow the restoration and / or replacement of the natural teeth with artificial teeth that cannot be removed by the patient.
In all circumstances, the advantages must justify the treatment and counterbalance the negative effects.

The restoration must be accomplished when the advanced restorative treatment is clearly capable of improving the patient's oral and psychological health.

For all the fixed prostheses the presence of abutments suitable for quality, location and prognosis is required. A fixed prosthesis can also be indicated in a restorative treatment involving implants.

The replacement of incongruous prostheses must be preceded by the knowledge and control of the causes behind the failure.

Indications for the use of full crowns and partial restorations
1. restore and / or improve the shape, function and appearance of deteriorated, worn or fractured teeth, in case of contraindication or clinical failure of simpler restorations;
2. reduce the risk of fractures in widely restored teeth, including posterior teeth endodontic treated;
3. change the shape, size and inclination of the teeth for aesthetic or functional purposes.

Indications for the use of "bridge" prosthetic devices
1. replace one or more teeth functionally or aesthetically important;
2. avoid teeth movements and improve occlusal stability;
3. improve functional comfort.

Operative steps in fixed prosthesis:
1. reduction of the natural tooth
2. impression registration
3. placing of interim prosthesis

4. one or more try-in of the final restoration
5. cementation of the final restoration
6. regular controls

Tooth reduction

The preparation of the natural teeth must be performed aiming to preserve as much as possible the dental substance, following the existing anatomy and creating, at the same time, the space necessary for the realization of a correct prosthesis. *(*Schillingburg 1981). The choice of the preparation design must be based on the prosthetic clinical project, the marginal periodontium, the aesthetic needs and the restorative material (Pascoe 1978, Dehoff 1989, Gavelis 1981). In particular, it is necessary to consider the anatomy, the degree of coronal destruction, the presence of restorations (fillings, post and cores), the relationships with the adjacent teeth and soft tissues, possible malpositions and consequent need for realignment , occlusal relationships and function *(*Martignoni 1987, Kuwata 1980). It is essential to design a preparation that respects the correct ratio between retention and taper, providing resistance and retention (Ayad 2009, Nordlamder 1988, Parker 1993, Parker 1991, Wiskott 1996*).* I it is necessary to splint several teeth it is important to check the parallelism of the abutments in relation to the insertion axis, eliminating any undercuts to allow a correct fitting of the prosthesis (Mc Lean 1979, 1980). It is recommended to make a preparations with clearly detectable margins, appropriate geometry (Syu 1993, Donovan 1985). When possible, it is recommended to achieve the periodontal health before completing the prosthetic and restorative treatments; the margin more favorable to the health of the periodontium is positioned coronally to the marginal gingiva (Bader 1991, Lang 1983*).* If the margins of the restoration extend into the gingival sulcus, it is preferable to have an adequate band of adherent gingiva. The placement of the margins in the intrasulcular compartment can be indicated for aesthetic reasons, presence of subgingival cavities, presence of margins of pre-existing restorations or need for greater retention (Richter-Snapp 1988, Carnevale 1990, 1983, Di Febo 1986, Chiche 1995*).*

The preparation of the natural tooth must be carried out preserving as much as possible the dental substance and following the anatomy of the tooth, compatibly with the planned prosthetic design and the materials that will be used for the restoration.

A correct retention / taper ratio associated with an adequate form of resistance is the basis of a good tooth preparation.

The choice of the preparation design is consequent to the prosthetic clinical project, to the biological and functional characteristics and to the aesthetic results desired.

Bibliography

Ayad MF, Johnston WM, Rosenstiel SF. Influence of tooth preparation taper and cement type on recementation strength of complete metal crowns. J Prosthet Dent. 2009 Dec;102(6):354-61.

Bader JD, Rozier RG, McFall WT, Ramsey DL. Effect of crown margins on periodontal conditions in regularly attending patient. J Prosthet Dent, 65: 75-79, 1991.

Carnevale G, Di Febo G, Fuzzi M. A retrospective analysis of the perio-prosthetic aspect of teeth re-prepared during periodontal surgery. J Clin Periodontal, 17: 313-16, 1990.

Carnevale G, Freni SS, Di Febo G. Soft and hard tissue wound healing following tooth preparation to the alveolar crest. Int. J. Of Periodont Rest. Dent. 6, 37, 1983.

Chiche G, Pinault A L'estetica nelle protesi fisse anteriori. Resch Editrice Verona 1995, Cap. 6, p. 115-142.

Dehoff PH, Anusavice KJ. Effect of metal design on marginal distortion of metal ceramic crowns. J Dent Res 1989; 63: 1327.

Di Febo G. La protesi nella malattia parodontale. In "Parodontologia" (a cura di Calandriello M, Carnevale G, Ricci G.) pag. 549, Editrice Cides Odonto, Edizioni internazionali, 1986.

Donovan T, Prince J. An analysis of margin configurations for metal-ceramic crowns. J Prosthet Dent, 53: 153-57, 1985.

Gavelis JR, Monrency JD, Riley ED, Sozio RB. The effect of various finish line preparations on the marginal seal and occlusal seat of full crown preparations. J Prosthet Dent, 45: 138-45, 1981.

Kuwata M. Theory and Practice for Ceramo-metal Restorations. Chicago: Quintessence, 1980.

Lang NP, Kiel RA, Anderhalden K. Clinical and microbiological effects of subgingival restorations with overhanging on clinically perfect margins. J Clin Periodontol 10: 563, 1983.

Martignoni M, Schonenberger AJ. Precisione e contorno nella ricostruzione protesica. Quintessenz Verlags Berlin, 1987.

McLean JW. The Science and Art of Dental Ceramics. Vol I. The nature of dental ceramics and their clinical use. Quintessence Publishing Co, Inc, Chicago, 1979.

McLean JW. The Science and Art of Dental Ceramics. Vol II: Bridge design and laboratory procedures in dental ceramics. Quintessence Publishing Co, Inc, Chicago, 1980.

Nordlander J, Weir D, Stoffer W, Ochi S. The taper of clinical preparations for fixed prosthodontics. J Prosthet Dent, 60: 148-51, 1988.

Parker MH, Calverly MJ, Gardner FM, Gunderson RB. New guidelines for preparation taper. J Prosthod, 2: 61-66, 1993.

Parker MH, Malone KH, Trier AC, Striano TS. Evaluation of resistance form for prepared tooth. J Prosthet Dent, 66: 730-33, 1991.

Pascoe D. Analysis of the geometry of finishing lines for full crown restorations. J Prosthet Dent 1978; 40:157.

Richter-Snapp K, Aquilino SA, Svare CW, Turner KA. Change in marginal fit as related to margin design, alloy type and porcelain proximity in porcelain-fused-to-metal restorations. J Prosthet Dent, 60: 435-39, 1988.

Shillingburg HT, Hobo S, Whitsett LD. Fundamentals of fixed prosthodontics, 2nd ed., Quintessence Publishing Co., Chicago, 1981.

Syu J, Byrne G, Laub LW, Land MF. Influence of finish-line geometry on the fit of crowns. Int J Prosthodont, 6: 25-30, 1993.

Wiskott HWA, Nicholls JI, Belser US. The relationship between abutment taper and resistance of cemented crowns to dynamic loading. Int J Prosthodont 1996; 9: 117-30.

Impression

The impression for the working model must be as precise as possible and contain all the information necessary for the manufacture of the prosthesis. A correct impression must accurately reproduce the prepared dental tissues and highlight the margins of the preparation, reproduce the other teeth in the arch, the edentulous spaces and the surrounding soft tissues (Bomberg et al. 1988, Johnson et al. 1998, Nishigawa et al. 1998, Winstanley et al. 1997). To obtain an accurate and stable impression, it is necessary to have healthy periodontal tissues, adequate dental preparations, a good knowledge of the materials and of the impression techniques. For the correct detection of the entire prepared dental surface it is necessary to highlight the marginal and sub marginal zones of the teeth (ADA Council, 1996; Ciesco et al., 1989; Davis & Powers 1994; Dixon, 1994). In case of intrasulcular preparations vertical and horizontal retraction of the free gingiva are necessary, positioning a retraction cord or using other existing methods for the displacement of the gingiva. In any case, soft tissue management and moisture control during the impression registration must be effective and not traumatic. (Corso et al. 1996, Eames et al. 1991, Flemmig et al. 1991, Hung et al. 1992). It is recommended that the impression material is selected on the base of chemical, physical and handling properties best suited to the clinical problems.

Each impression material has different handling characteristics and must therefore be used in accordance with the manufacturer's instructions. Once hardened, all impression materials must be able to withstand decontamination procedures (ADA Council 1996, Ciesco et al. 1989).

Standard impression trays and individual trays can be used.

In restorations with multiple elements, an individual tray is recommended when using impression elastomers.

In general, the impression trays must be extended enough to support the impression material in relation to the structures to be recorded, must be rigid, include occlusal stops and any features required to promote retention of the impression material through a specific adhesive; in addition, the impression tray must be able to withstand autoclaving, if reusable (Gelbard et al. 1994, Martignoni & Schonenberger, 1987, Laufer et al., 1996, Johnson et al. 1998). Once removed, the impression should be thoroughly rinsed, and checked for precision with the use of a magnification system in order to

verify the integrity of the margins, then decontaminated and well preserved in order to avoid damage, deformation or contamination.
The impression of the antagonist arches must assure good dental stability and an acceptable detection of the morphological details. (Hung et al. 1992, Purk et al. 1998, Rios et al. 1996, Nishigawa et al. 1998, Winstanley et al. 1997, Laufer et al. 1996, Johnson et al. 1998).

The impression for the working model must contain all the information necessary for the construction of the prosthesis.

In order to obtain an accurate and dimensionally stable impression it is necessary that periodontal tissues are healthy, that the dental preparations are adequate and that there is a good knowledge of the materials and of the impression techniques.

Each impression material must have characteristics such as: precise reproduction of details, good dimensional stability, elasticity and resistance to distortion, wettability (low surface tension), smoothness (fluidity), thixotropy, biocompatibility with oral tissues and compatibility with model materials (plaster and others), good processing and setting times, storage duration and low costs; it must be used in accordance with the manufacturer's instructions (Schulz et al. 1991; Shawell et al. 1988, Tan et al. 1996, Corso et al. 1996, Eames et al. 1991, Flemmig et al. 1991, Winstanley et al. 1997).
Important is the total processing time that must never be exceeded. This processing time is considered as the maximum period of time that passes from the beginning of the mixing until the impression tray is inserted in the mouth.. Mixing time is important in order to achieve homogeneous mixing of the dosed components.
The hardening time of the material is the minimum time from the beginning of the mixing until the removal from the mouth, in order to avoid permanent and significant deformations. (Davis & Powers 1994, Dixon 1994, Tan et al. 1996, Corso et al. 1996, Schulz et al. 1991, Rios et al. 1996, Nishigawa et al. 1998, Winstanley et al. 1997).

The impression materials must be used following the working characteristics and the indications provided by the manufacturers.

Once the impressions have been registered, models have to be poured with materials with details reproduction precise as the impression material has. Surface hardness and abrasion resistance have also

to be considered for model materials. The materials used for the models are: gypsum, resin-based materials, electrodeposited copper or silver, low melting temperature metals and refractory materials. The choice among this materials denpedns also on the impression material used. Times to develop the models recommended by the manufacturers have to be respected.

Some materials, such as polyethers, are sensitive to thermal changes, it is important to use the appropriate precautions in the transfer from the study to the laboratory.

Bibliography

ADA Council on Scientific Affaire and ADA Council on Dental Practice. Infection control recommendations for the dental office laboratory. J.Am Dent Assoc 1996; 127: 672 – 80.

Ahlholm P, Sipilä K, Vallittu P, Jakonen M, Kotiranta U Digital Versus Conventional Impressions in Fixed Prosthodontics: A Review. J Prosthodont. 2016

Bomberg TJ, Goldfogel MH, Hoffman W, Bomberg SE. Considerations for adhesion of impression materials to impression trays. J Prosthet Dent 1988; 60: 681.

Ciesco JN, Malone WFP, Sandrik JL, Mazur B. Comparison of elastomeric impression materials used in fixed Prosthodontics. J Prosthet Dent1989; 45: 89.

Chochlidakis KM, Papaspyridakos P, Geminiani A, Chen CJ, Feng IJ, Ercoli C. Digital versus conventional impressions for fixed prosthodontics: A systematic review and meta-analysis. J Prosthet Dent. 2016 Aug;116(2):184-190

Corso M, Abanomy A, Di Canzio J, Zurakowski D, Morgano SM. The effect of temperature changes on the dimensional stability of polyvinyl siloxane ad polyether impression materials. J Prosthet Dent 1996; 79: 626-31.

Davis BA, Powers JM. Effect of immersions disinfection on properties of impressions materials. J. Prosthodont 1994; 3: 31-4.

Dixon DL, Breeding LC, Moseley JP. Custom Impression trays. Part II: Removal forces. J. Prosthet Dent.1994; 71: 316-318.

Eames WB, Wallace SW, Suway NB, Rogers LB. Accuracy and dimensional stability of elastomeric impression materials. J Prosthet Dent 1991; 42: 159.

Flemmig TF, Sorensen JA, Newman MG, Nachnani S. Gingival enhancement in fixed prosthodontics. Part II J Prosthet Dent 1991; 65:365.

Gelbard S, DMD, J . Aoskar, DMD, M. Zalikint, DMD, and Noah Stern , DMD, MSD. Effect of impression materials and techniques on the marginal fit of metal castings. J Prosthet Dent 1994; 71: 1-5.

Hung SH, Purk JH, Tira DE, Eick JD. Accuracy of one-step versus two-step putty wash addition silicone impression technique. J Prosthet Dent 1992; 67: 583.

Johnson GH, Chellis KD, Gordon GE, Lepe X. Dimensional stability and detail reproduction of irreversible hydrocolloid and elastomeric impressions disinfected by immersion. J Prosthet Dent 1998; 79: 446-53.

Laufer BZ, Baharav H, Ganor Y, Cardash HS. The effect of marginal thickness on the distortion of different impression materials. J Prosthet Dent 1996; 76: 466-71.

Martignoni M, Schonenberger A. Precisione e contorno nella ricostruzione protesica. Quintessenz, Berlin, 1987.

Nishigawa G, Sato T, Suenaga K, Minagi S. Efficacy of tray adehesives for the adhesion of elastomer rubber impression materials to impression modeling plastics for border molding. J Prosthet Dent 1998; 79: 140-4.

Purk JH, Willis MG, Tira DE, Eick D, Hung SH. The effects of different storage conditions on polyether and polyvinylsiloxane impressions. J Am Dent Assoc 1998; 129: 1014-21.

Rios MdP, Morgano SM, Stein RS, Rose L. Effects of chemical disinfectant solutions on the stability and accuracy of thedental impression complex. J Prosthet Dent 1996; 76: 8-14.

Schulz HH, Schewickerath H. L'impronta in Odontoiatria . Scienza e tecnica dentistica edizioni internazionali srl Milano.1991.

Shawell HM. Mastering the art of tissue management during provisionalization and biologic final impressions. Int J Periodont Rest Dent 1988; 8 (3) : 25

Tan E, Chai J, Wozniak WT. Working time of elastomeric impression materials determined by dimensional accuracy. In J Prosthodont 1996; 9: 188-86.

Tsirogiannis P, Reissmann DR, Heydecke G. Evaluation of the marginal fit of single-unit, complete-coverage ceramic restorations fabricated after digital and conventional impressions: A systematic review and meta-analysis. J Prosthet Dent. 2016 Sep;116(3):328-335

Winstanley RB, Carrote PV, Johnson A. The quality of impressions for crown end bridges received at commercial dental laboratories.Br Dent J 1997; 183: 209 – 13.

Provisional fixed prosthesis

In fixed prosthetic rehabilitations, provisional has a fundamental role as it allows to analyze and test the function, aesthetics, phonetics and biological integration of the restoration and the consent of the patient before proceeding with the final prosthesis. (Fradeani 2002, Koop 1993).

As well as having a protective function on the dentin, provisional serve to maintain the position of the prepared teeth, to maintain and improve periodontal health, to replace the missing teeth or to change the shape and function of the teeth, to restore an ideal occlusal stability and a suitable vertical dimension (Di Febo 1986).

The provisional prostheses are therefore to be considered, if well constructed, adapted and functionalized in the mouth, a valid test of the final prosthesis.

The provisional must have a good adaptation and a good marginal fit, precise and polished margins, a correct design of the pontics and adequate interproximal spaces to favour oral hygiene and periodontal health. Resistance to fracture and to decementation during normal masticatory function, abrasion resistance and occlusal stability are necessary characteristics in order to remain in the oral cavity even for a long period (Bonfiglioli 1994, Koumjian 1990). This adaptation period is mandatory when the vertical occlusion dimension needs to be modified to establish a physiologically acceptable new position.

A correct vertical occlusion dimension is essential for a valid function, for an adequate free space, for comfort, for a satisfactory phonetics and an optimal aesthetics.

The direct or indirect technique can be used for the construction of the provisional.

The direct technique involves the construction of the provisional in the dental office, using prefabricated teeth or pouring self-curing resin inside a matrix, for example an acetate template. This technique is used mainly in small rehabilitations (single restorations, short bridges), when the shape and the functionality of the tooth must remain unchanged.

The indirect technique is always used in cases where significant aesthetic and / or occlusal changes are necessary; provisional is constructed in the dental laboratory, reproducing the diagnostic wax-up. The preliminary provisional can be used to guide dental preparations, modifying aesthetics and correcting dental malposition.

Before the definitive work can be carried out, it may be necessary to make a second provisional to further improve the functional and aesthetic aspect.

The main characteristics of provisional prostheses are the ease with which they can be modified by relining or aesthetically.

The materials used to make the provisional prosthesis with the above characteristics are the acrylic resins (polymethyl methacrylate).

These materials have an adequate aesthetic result, good dimensional stability, no bad taste, ease of processing both in the laboratory and in the clinical phases, minimum absorption of oral fluids. They can be modified easily, but have a certain polymerization shrinkage, so the provisional shells can be slid and relined to further improve the marginal precision of both preliminary or extemporaneous provisionals and the second provisionals. (Grajower 1979, Moulding 1990, 1991).

Before relining provisionals the interferences inside the shell, the marginal closure, the interferences of the intermediate elements must be evaluated, and during the relining the patient has to be guided in the correct vertical dimension and occlusal relationship to minimize the work of adaptation and functionalization to the chair.

For the temporaries that must remain in the mouth for some time, hot-cured resins are preferable, which have superior resistance to wear and bending, less absorption of liquids and less discolouration.

Composite materials can also be used, having superior strength and higher precision and aesthetic characteristics, but are more difficult to reline; their manufacturing cost can also be higher.

The provisional prosthesis must have a good fit and a good marginal seal, precise and polished margins, a correct design of the pontics and adequate interproximal spaces to favor oral hygiene and periodontal health. They represent a valid test of the final prosthesis.

Bibliography

Bonfiglioli R. Restaurations provisoires simples et complexes: technologies de laboratoire. Realities cliniques Vol. 5 n° 1 1994 pp. 101-110.

Chiche G. Improving marginal adaptation of provisional restorations. Quintessence Int 1990; 21: 325.

Di Febo G. La protesi nella malattia parodontale. In Parodontologia. (a cura di Calandriello M, Carnevale G, Ricci G.) Pag. 549, Editrice Cides Odonto. Edizioni internazionali, 1986.

Fradeani M, Barducci G. Trattamento protesico. Approccio sistematico all'integrazione estetica, biologica e funzionale. Vol 2 Pag 124-146.

Grajower R, Shaharbani S, Kaufman E. Temperature rise in pulp chamber during fabrication of temporary self-curing crowns. J Prosthet Dent 1979; 41: 535.

Koop F. Esthetic principles for full crown restorations. Part II. Provisionalization. J Esthet Dent 1993; 5: 258-264. Koumjian JH, Holmes JB. Marginal accuracy of provisional restorative materials. J Prosthet Dent 1990; 63: 639-42.

Moulding MB, Loney RW. The effect of cooling techniques on intrapulpal temperature during direct fabrication of provisional restorations. Int J Prosthodont 1991; 4:325.

Moulding MB, Teplitsky PE. Intrapulpal temperature during fabrication of provisional restorations. Int J Prosthodont 1990; 3:299.

Wang RL, Moore BK, Goodacre CJ, Swartz ML, Andres CJ. A comparison of resins for fabricating provisional fixed restorations. Int J Prosthodont 1989; 2:173.

ORTHODONTICS AND GNATHOLOGY

The stomatognathic system - a complex “multi-functional system” comprising the maxilla and the mandible, the dentoalveolar arches, the neuromuscular system and the temporo-mandibular joints - performs vital functions such as swallowing, breathing, speaking and chewing. When its various components are in balance the stomatognathic system grows and develops harmoniously. However, some adverse factors can influence its normal development thus causing malocclusions.

The primary aim of orthodontics and gnathology, two disciplines studying dental, maxillary and facial dysgnathias, is to identify any pathogenic damage at an early stage “by creating the conditions to bring natural growth back to its biological norm”.

In orthodontics and gnathology, diagnosis is fundamental to assess a clinical condition and subsequently place it into the context of individual growth.

Malocclusions that clinically can appear similar may show substantial differences both in terms of three-dimensional causes and the presence of more complex concurrent factors that sometimes require different treatment priorities (Bjork 1996).

Typically, patients affected by malocclusions are still growing. However, adult patients are increasingly turning to a dentist who is specialised in orthodontics. These patients have substantially different individual requirements and objective clinical needs often requiring an interdisciplinary approach.

Apart from the syndromic patients, where malocclusions are often pathognomonic in relation to the overall syndromes, facial and dentomaxillary features can be the result of an interaction between genetic, family and environmental factors affecting growth and development of the dento-maxillofacial complex thus causing malocclusions (e.g., Class III malocclusion).

As regards the etiopathogenesis of malocclusions, functional alterations (e.g., oral habits such as tongue thrust, thumb and lip sucking, postural alterations, oral breathing, etc.) are the main factors causing malocclusions because they can maintain alterations between intra- and extra-oral musculature resulting in morpho-functional changes at dentoalveolar and/or skeletal level (Ackerman 2009, Agenter 2009).

Local etiopathogenic factors also include dental factors. Traumatic avulsion of deciduous teeth – usually maxillary incisors - when there is no adequate assessment of medium and/or long term effects on corresponding permanent teeth, destructive caries or premature extraction of deciduous teeth – usually first and second deciduous molars – without adequate space maintenance, can reduce the length of the arch and lead to malocclusions.

An overall assessment of various factors is necessary for an accurate diagnosis of malocclusions.

When recording patients’ medical histories, it is important to: a) focus on information on family members’ occlusal features and orthodontic problems to see whether there are similar clinical conditions (e.g., Class III, dental anomalies, etc.); and b) find out whether there were traumas in early

childhood that caused skeletal alterations (e.g., mandibular traumas having an impact on temporo-mandibular joints and on the onset of asymmetries) or dental traumas in deciduous dentition (because of their consequences on corresponding permanent teeth (e.g., dislocation, dilaceration, developmental anomalies, etc.) or in permanent dentition.

Extra-oral clinical examination is useful to establish facial types (mesiofacial, brachyfacial or dolichofacial types) and profiles (concave, convex or flat) and to assess the aesthetics of face~~s~~ and smile~~s~~.

Functional examination is needed to assess temporo-mandibular joints and extra-oral musculature.

Intra-oral clinical examination is useful to study the teeth condition, thus allowing to perform preliminary assessment of the features and integrity of dento-periodontal structures. Some occlusal parameters can also be identified:

- Angle class: Sagittal occlusal relationships between maxillary and mandibular arches, based on the relationships between mandibular and maxillary first molars and between mandibular and maxillary canines. Optimal occlusal relationships are molar Class I and canine Class I;
- Overjet, Overbite, midline relationships (with open and closed mouth), crossbite or scissor bite.

It is also important to carefully assess tongue function and frenulum, and to study insertions and features of labial frenula as well as appearance and features of periodontal tissues.

Clinical examinations can be supported by extra- and intra-oral pictures.

Using casts is useful to further understand intra- and inter-arch features and relationships: arche~~s'~~ size and symmetry, occlusal parameters, curve of Spee, curve of Wilson, tooth size and position~~s~~, and any arch-tooth and tooth-size discrepancy (Andrews 1972).

X-rays can be prescribed to collect complete clinical records but only if necessary/indispensable for diagnostic and prognostic purposes, and to draw up the treatment plan.

Orthopantograms of dental arches are used to assess teeth and their positions as well as any dental abnormality in terms of number, position, place, shape, decay, endodontic and periodontal conditions, cysts, etc.). Although orthopantograms do not provide the anatomic details that intra-oral, periapical X-rays do show, they offer a general view of the dental arches and the alveolar ~~and~~ bone structures. If there is any doubt regarding the diagnosis, intra-oral-periapical or occlusal X-rays, or a 3D analysis might be required.

Lateral cephalograms and their cephalometric analyses are used to assess, on the sagittal and vertical planes, the relationship between the cranial base and the jaws, the relationship between the maxilla and the mandible, arch-tooth and tooth-size relationships, growth pattern, and soft tissues. This examination must also provide preliminary diagnostic information on the state of bone development using the vertebral maturation index.

Postero-anterior cephalograms can be prescribed when there are vertical alterations, transverse problems, dentoalveolar and maxillofacial asymmetries, and functional mandibular deviations.
Hand and wrist X-rays can be used to determine skeletal age more reliably.
In order to plan treatment, targeted objectives to be pursued with accurate priorities must be identified on the basis of information gathered during diagnosis and prognosis of the correction. To this end, bearing in mind the following factors is essential: age of patient, medical history, (including family medical history influencing prognosis), type of malocclusion (dental, dentoalveolar, skeletal, functional, aesthetic), development stage and growth potential, and any further condition closely related to the clinical picture that might require a multidisciplinary approach (e.g., periodontal or general orthodontic problems, etc.) (Riolo 1988, Riolo 2009).
Given the numerous factors and variables contributing to the onset of the different malocclusions, identifying a standardised treatment as well as the most appropriate clinical appliance to use is not always feasible for various reasons:
- scientific evidence does not always support a single treatment approach as the preferred choice to solve different problems;
- so far there are very few randomised clinical studies available and different appliances are being suggested;
- no specific and unambiguous clinical "recommendations" have been defined in the literature for most orthodontic and gnathologic problems;
- opinions on when to start treatment or length of treatment are not always unanimous; some malocclusions must be treated early (e.g., Class III cases or asymmetries); others, with exceptions, can be dealt with later on, provided they are not in themselves sources of further orthodontic and gnathologic or even strictly dental problems (e.g., an early correction of Class II with a wide overjet can prevent dental traumas);
- technological innovations and the evolution of scientific thinking have significantly contributed to the development of different appliances whose features and purpose have been optimised. However, "recommending" one particular appliance for specific malocclusions rather than others as "the absolute appliance of choice" is not always feasible even though it might have the same effects.
Irrespective of the objective clinical problem requiring orthodontic and gnathologic correction, patient's compliance is essential for prognostic and therapeutic purposes. Without proper compliance, the orthodontic and gnathologic procedure will be nullified because treatment objectives will not be achieved. Furthermore, there could be unwanted side-effects on the integrity of dental and periodontal tissues (Gkantidis 2010).

When recording medical history, information on patients' dental and occlusal condition as well as orthodontic problems of their family members should be taken into account to establish whether there are similar clinical conditions (e.g., Class III, dental anomalies, etc.).

Focus should be given to any early childhood trauma that could have caused skeletal changes or could have had an impact on deciduous or permanent dentition.

Functional alterations need to be detected and corrected at a very early stage because they can change the balance between intra- and extra-oral muscles and have consequences on the dentomaxillofacial complex (Chen 2002).

Integrity of dental arches must be ensured through early treatment of decays on deciduous teeth to prevent premature tooth loss from causing mesial tipping, mesialisations and rotation of adjacent teeth as well as extrusion of opposite teeth with possible further repercussions on inter-arch relationships (Ruhl 1994, Tollaro 1996).

In planning orthodontic treatment, the following factors must be taken into account: a) patients' diagnostic pictures and, if growing, their skeletal age by assessing their growth potential; and b) seriousness and priority of problems that have been identified (e.g., syndromes and developmental anomalies, skeletal defects caused by asymmetries, vertical, sagittal and transverse discrepancies, dentoalveolar anomalies). The overall consideration, though, should include patient's motivation and chief complaint (Brook 1989, Hassan 2010).

Given the complexity of some malocclusions, different problems often associated to other issues can be identified and, although some of them are priority issues, always "recommending" a specific treatment sequence is not advisable. Each patient ought to be provided with an accurate diagnosis to be used to draw up the most appropriate and highly individualised treatment plan (Hayes 2009).

Establishing the orthodontic treatment time accurately is not always feasible:

► in growing patients, treatment planning can include various stages, with intermediate records, during which patients' growth and development and transition from deciduous to permanent dentition need to be monitored;

► in adult patients, a multidisciplinary approach that includes different procedures in order to attain treatment objectives is often required (e.g., periodontal treatment, prosthetic dentistry, implant placement etc.) (Turpin 2007, Thiruvenkatachari 2015, Vaden 2009).

As far as the "long-term stability" of outcome (in terms of "stability of treatment") is concerned, opinions in literature are controversial. Pursuing good functional balance ought to ensure that the results achieved are stable over time (Hiemstra 2009, Kuhlberg 1997, Marshall 2008).

The treatment plan must be outlined to patients and their families (in case they are under age) clearly and exhaustively, ensuring that objectives, requirements/expectations, required compliance and

cost/benefit relationship between commitment and benefits are fully understood. Moreover, and bearing in mind that further assessment and treatment plan might be needed, the patient should be informed about the time by which treatment goals are expected to be reached depending, of course, on biological variability. A fundamental role is played by patients' and families' compliance during the various treatment stages. Without compliance, the orthodontic and gnathologic treatment will not only be unsuccessful but there might also be undesired effects on the integrity of dento-periodontal tissues (Jharwal 2014, Laskin 1988, Little 1990).

Clinical appliances must meet legal requirements; they must also be chosen/manufactured on the basis of treatment goals bearing in mind biological features, skeletal maturity, their mechanics and social impact. Appliances must also comply with the principle of maximum simplicity, efficacy and effectiveness, and minimum biological, emotional and, if possible, financial costs. Patients must be able to understand how appliances function as well as how and when they need to be used.

Recommended diagnostic steps to assess malocclusions and plan treatment effectively are outlined in Table 1 below (Peck 2009, Proffit 2013)

Table 1

D=Diagnosis **T=Treatment**	**TYPE OF PROCEDURE** **and TIMING**	**S / C / VC** (S= Simple) (C= Complex) (VC= Very Complex)
D	**First appointment and collection of basic records:** ❖ medical and dental history ❖ assessment of dental and gingival health: treatment priorities ❖ clinical examination and functional analysis ○ assessing facial proportions and profile analysis ○ assessing facial symmetry ○ assessment of the dental formula ○ assessing static occlusion ○ assessing mandibular mobility ○ assessing the functions of the stomatognathic system ○ examining masticatory and cervical muscles ○ examining temporo-mandibular joints ❖ any necessary X-rays * ❖ any necessary diagnostic tests	S / C

D	**Second appointment and collection of basic records:** ❖ re-assessment and more detailed clinical examination and functional analysis ❖ assessing the stage of physical development (e.g., weight, height and signs of puberty) ❖ taking impression of dental arches ❖ intra- and extra-oral pictures ❖ any necessary diagnostic tests ❖ any request for advice to other clinicians (another dentist, orthodontist and gnathologist, physician, maxillofacial surgeon) or other professional (speech therapist, physiotherapist)	C

D	*** X-rays** ❖ Orthopantogram (if required) ❖ Lateral cephalogram (if required) ❖ Postero-anterior cephalogram [if required in case of (suspected) dentoalveolar and/or maxillofacial asymmetries, dental and/or skeletal cross-bites, functional mandibular deviations, vertical problems] ❖ Wrist or hand X-rays (if needed to assess skeletal age) ❖ intra-oral and/or occlusal periapical X-rays (if needed) ❖ 3D analysis such as CONE BEAM CT (if needed in case of serious asymmetries, impacted teeth with abnormal positions and risk of lesions to adjacent teeth) ❖ [TMJ MR if required in case of TMJ dysfunctions] *** X-rays are only required after a careful clinical examination and when necessary/indispensable for diagnostic purposes, and to draw up the treatment plan.**	C
D	**Treatment planning** **Overall assessment of static and dynamic intra- and extra-oral clinical parameters** ❖ Assessing casts ❖ Arch shape and symmetry ❖ Space analysis ❖ Extent of sagittal discrepancy ❖ Extent of transverse discrepancy ❖ Set-up models [if needed to visualise dental and dento-skeletal movements]	

	Assessing intra- and extra-oral pictures **X-rays analysis** ❖ Assessing bone and tooth structures ❖ Identifying any teeth and skeletal problem **Head film tracing (if required)** ❖ Analysing sagittal, vertical and transverse maxillary and mandibular skeletal relationships ❖ Analysing dento-maxillofacial and tooth-size relationships ❖ Analysing soft tissues ❖ Type of facial growth ❖ Orthodontic or orthodontic-surgical VTO (Visualisation of Treatment Objectives) (if needed in pre-surgical cases)	VC
D	**Outlining treatment plan** **Explaining clinical appliances: purpose, use and maintenance** **Informed consent**	C
T	The clinical decision will be made on the basis of problems identified during diagnosis with precise individualised priorities relating to the seriousness of clinical problems [syndromes and developmental anomalies; sagittal, vertical and transverse discrepancies, dento-alveolar anomalies]. Treatment decisions will be made following careful consideration of patients' skeletal age, whether patients are growing, development stage and growth potential. The treatment plan must be outlined to patients and/or their families (in case they are under age) to ensure that its purpose and objectives are fully understood; requirements/expectations, compliance and relationship between commitment and benefits need to be assessed. Treatment objectives must be clear, the patient should be informed when treatment goals are expected to be achieved; the need for any further assessment or a new Treatment Plan needs to be mentioned. In "surgical" cases, treatment planning must be shared with the surgeon who will perform surgery. Exhaustively explain to the patient orthodontic and pre- and post-surgical treatment objectives as well as the overall surgical-orthodontic treatment.	VC

T	**Treatment** ❖ Any appliance to be used must meet legal requirements. ❖ Patients will have to understand how they function as well as how and when they are used. ❖ Appliances must be chosen on the basis of treatment objectives, bearing in mind biological features, skeletal maturity, mechanics and social impact. ❖ Appliances must also comply with the principle of maximum simplicity, efficacy and effectiveness, and minimum biological, emotional and, if possible, financial costs.	VC
T	In surgical cases, there is a pre-surgical orthodontics phase; at the end of this phase, patients are sent to surgeons to undergo the necessary treatment. At the end of surgery, there is a post-surgical orthodontic phase aimed at finalising the occlusion, rehabilitating the stomatognathic function and completing treatment.	VC
T	**End of treatment** ❖ Impression-taking and of end-of-treatment casts (if needed) ❖ Intra- and extra oral pictures (if needed) ❖ Applying a retainer (if needed) ❖ Control Orthopantogram and Cephalograms (if needed) ❖ [Control MRI and CT, if needed] ❖ [Any necessary control tests] ❖ Outlining achieved goals, possible relapse, any further necessary treatment and functional settling.	C

Bibliography

Ackerman JL, Kean MR, Proffit WR. The interaction of function and stability in the dentition. Aust Orthod J. 2009;25:169-72.

Agenter MK, Harris EF, Blair RN. Influence of tooth crown size on malocclusion. Am J Orthod. Dentofacial Orthop. 2009;136(6):795-804.

Andrews LF, The six keys to normal occlusion. Am J Orthod. 1972 Sep;62(3):296-309.

Bjork A. Sutural growth of the upper face studied by the implant method, Acta Odont Scand 1996;24:109-127.

Brook PH, Shaw WC. The development of an Index of Orthodontic treatment priority. Eur J Orthod 1989 Aug; 11 (3):309-20

Casko JS, Vaden JL, Kokich et al. Objective grading system for dental casts and panoramic radiographs. Am J Orthod DentofacialOrthop 1999;114:589-99.

Chen JY, Leslie AW, Niederman R.. Analysis of efficacy of functional appliances on mandibular growth. Am. J. Orthod DentofacialOrthop 2002;122:470-476.

Gkantidis N, Christou P, Topouzelis N. The orthodontic periodontal interrelationship in integrated treatment challenges:a systematic review. J Oral Rehabil. 2010;37:377–390.

Harvold EP. The role of function in the etiology and treatment of malocclusion. Am J Orthod. 1968;54:883-98.

Hassan AH, Amin Hel. Association of orthodontic treatment needs and oral health-related quality of life in young adults. Am JOrthod Dentofacial Orthop 2010;137:42-7.

Hayes Williamsport J. L. Letters to the editor: Problems with RCT design. Am J Orthod Dentofacial Orthop 2009;136:143-4.

Hiemstra R, Bos A, Hoogstraten J. Patients' and parents' expectations of orthodontic treatment. J Orthod. 2009;36:219-28.

Jharwal V, Trehan M, Rathore N, Rathee P, Agarwal D, Mathr N. Informed consent for brace. Int J Clin Pediatr Dent 2014 May; 7(2): 105-8

Kuhlberg AJ, Glynn. Treatment planning consideration for adult orthodontic patients, Dent Clin North Am 1997;41:17-27.

Laskin DM. Establishing standards of care. J Oral Maxillofac Surg 1988;46:1.

Little RM. Stability and relapse of dental arch alignment. Br J Orthod. 1990 Aug;17(3):235-41.

Marshall JD et al. Ask us Long-term stability of maxillary expansion Am J Orth Dent Orthop 2008, 133, 780-781

Peck S, The contributions of Edward H. Angle to dental public health. Community Dent Health. 2009 Sep;26(3):130-1.

Proffit WR, Fields HW, Sarver DM. Ortodonzia Moderna (IV edizione). Elsevier Masson, 2013

Riolo ML, Moyers RE, TenHave TR. Imprecision and bias in orthodontic treatment. Am J Orthod Dentofacial Orthop 1988;93: 138-42.

Riolo ML, Vaden JL. Standard of care: Why it is necessary. Am J Orthod Dentofacial Orthop 2009; 136: 494:496.

Ruhl CM, Bellian KT, Van Meter BH, Hoard MA, Pham CD, Edlich RF. Diagnosis, complications, and treatment of dento-skeletalmalocclusion. Am J Emerg Med.1994;12:98-104.

Thiruvenkatachari B, Harrison J, Worthington H, O'Brien K. Early orthodontic treatment for Class II malocclusion reduces the chance of incisal trauma: Results of a Cochrane systematic review. Am J Orthod Dentofacial Orthop. 2015 Jul;148(1):47-59.

Tollaro I, Franchi L, Baccetti T. Floating norms for the assessment of craniofacial pattern in the deciduous dentition, Eur J Orthod18:359-365, 1996.

Turpin DL. The case for treatment guidelines. Am J Orthod Dentofacial Orthop 2007;131:159.

Vaden JL, Riolo ML. How can the speciality establish a standard of care? Am J Orthod Dentofacial Orthop 2009;136: 497:500.

TRANSVERSE DIMENSION PROBLEMS

These problems are particularly important because of their possible impact on the development of skeletal asymmetries and the close relationship between the transverse, sagittal and vertical dimensions. Transverse dimension problems due to maxillary constriction are very frequent; they are characterised by an abnormal relationship on the transverse plane that becomes evident when the teeth of both arches are in occlusion (single or bilateral crossbite: the maxillary premolars' and molars' vestibular cusps

occlude in the central fossae of opposite mandibular teeth, with the upper canine lingually positioned to the lower canine) (Baccetti 2001, Deshayes 2006).

A transverse maxillary constriction can be caused by many factors with family history for transverse deficit playing a major role. Functional environmental factors, such as oral breathing, sucking thumbs or pacifiers, and atypical swallowing, are the most frequent causes of transverse deficits because they change the balance between the forces applied by the internal muscles (tongue) and those applied by external muscles (lips and cheeks).

Maxillary transverse excesses are very rare pathological conditions that can result in a unilateral or bilateral scissor bite (Subtelny 1973).

Transverse discrepancy is not self-correcting but is passed on from deciduous to mixed dentitions with an increased prevalence of lateral crossbite.

Clinically maxillary constriction can be: a) skeletal, with a reduction of the width of the upper jaw associated with a transverse deficit of the midface; b) dentoalveolar, due to palatal inclination of maxillary teeth and alveolar processes; and c) mixed, when teeth with altered palatal inclination lack support because the upper jaw has a weak bone structure (Lima 2005, McNamara 2002, McNamara 2015).

The most frequent type of posterior crossbite is the unilateral one that can be true or functional: the true unilateral crossbite is due to a real asymmetry of the upper arch and or whereas the functional unilateral crossbite is usually due to a bilateral constriction of the maxillary arch ~~and~~ in association with /consequent to mandibular lateral deviation towards the side of the crossbite. Alignment of the mid-lines at widest opening, validated by the study of the maxillary symmetry, can confirm a suspected functional lateral deviation. The asymmetric position of the condyles can lead to a gradual compensation through a unilateral remodelling of the joint, causing condyle path and craniofacial asymmetry.

When the transverse deficiency is compensated at dentoalveolar level, there can be a maxillary constriction even without crossbite (e.g., compensated forms of Class III cases) (Westwood 2003).

Even without crossbite, in Class II cases, a constricted maxilla can cause mandibular retrusion. There can also be a “relative” maxillary transverse deficiency due to the maxilla adapting to a retruded mandible (Pinto 2001).

Within maxillary transverse excesses, there can be both a primary congenital form, i.e., Brodie’s syndrome, in patients affected by Cooley’s anaemia, and acquired forms due to primary malposition of teeth or iatrogenic procedures (Lagravere 2004).

During the diagnostic assessment, special attention needs to be paid to extra- and intra-oral features and their functional implications, in particular posture, by performing in-depth static and dynamic clinical

tests (e.g., opening and closing the mouth to detect any lateral deviation). Neuromuscular adaptation, following a laterally shifted mandible typical of functional crossbite, creates facial disharmony with asymmetric mandibular growth (McNamara 2002).

Casts allow an objective analysis of inter- and intra-arch relationships, particularly transverse ones. Transverse deficiencies (TD) are the difference between maxillary and mandibular inter-molar width. With a negative TD, the width of the upper jaw is narrower than that of the mandible. However, when a TD is positive, the upper jaw is wider than the lower one.

Postero-anterior cephalograms, although difficult to interpret given the complex representation of anatomical structures, can help confirm an altered mandibular posture, a maxillo-mandibular transverse deficiency, even in terms of dentoalveolar implications, and concurrent asymmetry and vertical dimension alteration (Lagravere 2005).

Treatment must be based on an early diagnosis of transverse problems and their timely correction is a real priority.

Bearing in mind the low rate of spontaneous correction of crossbites in deciduous and early mixed dentitions, because of neuromuscular adaptation following the acquired lateral shift of the mandible and maxillofacial growth alterations, early treatment of these conditions is recommended. Choosing the most appropriate approach when treating these conditions is closely related to the bone and/or dentoalveolar features.

With palatal transverse deficiencies, expansion is the main treatment as it aims at transversally matching the size of the maxilla to that of the mandible.

Possible expansion approaches can be:

- orthodontics, thus influencing the teeth or the dentoalveolar complex;
- orthopaedics, when a diastasis of the midpalatal suture to increase transverse width is necessary in growing patients;
- orthodontics/orthopaedics, when dentoalveolar and skeletal treatment is necessary to correct a transverse deficiency;
- surgery/orthodontics when, at the end of growth, surgical-orthodontic treatment turns out to be necessary to correct a constriction.

In some cases, the use of functional appliances, such as a Frankel functional regulator, particularly in early mixed dentition, could expand functional spaces thus promoting the transverse growth of the arches.

In some Class II cases, due to mandibular retrusion, expansion can act as an endogenous functional appliance because it can promote correct sagittal repositioning of the mandible in relation to the maxilla.

Orthopaedic expansion is used to increase both the skeletal maxillary width and the intra-nasal capacity to laterally shift the two halves of the nasal-maxillary complex moving them up and outwards (Kantomaa 1986).

Due to the close relationship between the transverse, sagittal and vertical dimensions, correction of transverse dimension problems can be often considered a priority in relation to problems with other planes that are sometimes present at the same time (Bartzela 2007, Thilander 1984).

Treating a transverse discrepancy can sometimes contribute to solving a sagittal one (Franchi 2005).

With a mandibular lateral deviation, early and timely treatment can prevent or intercept postural asymmetries that would otherwise result in skeletal asymmetries (Doruk 2003, Dugoni 2006, Erdinc 1999).

Selective grinding to remove any occlusal interference causing the mandibular lateral deviation can prevent the onset of posterior crossbites in deciduous dentition. When grinding on its own is not sufficient, an appliance for rapid palatal expansion (e.g., a rapid expander) or slow palatal expansion (e.g., Quad helix) can be used to prevent the posterior crossbite in mixed dentition to become stable (Kennedy 2005, Kurol 1992, Tollaro 1996, Vizzotto 2008).

In mixed dentition, a slow or rapid maxillary expander can be used to restore the correct maxillo-mandibular relationship. In order to preserve the dental and -periodontal integrity of permanent teeth, using an orthopaedic expander on deciduous teeth is recommended whenever possible (Kecik 2007, O'Grady 2006, Tollaro 1996).

In growing patients, widening nasal cavities following orthopaedic maxillary expansion reduces the resistance of upper airways associated with oral breathing, snoring and obstructive sleep apnoea.

A comparison between different approaches, as evidenced by various studies, does not seem to show significant differences in terms of treatment planning (Nerder 1999).

In permanent dentition and at the end of growth, treatment of transverse dimension problems can be exclusively orthodontic, a compromise (as is often the case), or surgical-orthodontic (Petrèn 2003).

Bibliography

Baccetti T, Franchi L, Cameron CG, McNamara JA Jr. Treatment timing for rapid maxillary expansion. Angle Orthod 2001;71:343-50.

Baccetti T, Franchi L, Schulz SO, McNamara JA Jr. Treatment timing for an orthopaedic approach to patients with increased vertical dimension. Am J Orthod Dentofacial Orthop 2008;133:58-64.

Bartzela T, Jonas I. Long-term Stability of Unilateral Posterior Crossbite Correction. Angle Orthod 2007;77:237–43.

Deshayes MJ. Cranial asymmetries and their dento-facial and occlusal effects. Orthod Fr 2006;77:87- 99.

Doruk C, Bicakci AA, Basciftci FA, Agar U, Babacan H. A comparison of the effects of rapid maxillary expansion and fan-type rapid maxillary expansion on dentofacial structures. Angle Orthod 2003:74;184-94.

Dugoni S, Maryse A, Baumrind S. Differential diagnosis and treatment planning for early mixed dentition malocclusions. Am J Orthod Dentofacial Orthop 2006;129;S80-1.

Erdinc AE, Ugur T. Erbay E. A comparison of different treatment techniques for posterior crossbite in the mixed dentition. Am J Orthod Dentofacial Orthop 1999;116:287-300.

Franchi L, Baccetti T. Transverse maxillary deficiency in Class II and Class III malocclusions: a cephalometric and morphometric study on postero-anterior films. Orthod Caniofac Res 2005;8:21-5.

Kantomaa T. Correction of unilateral crossbite in the deciduous dentition. Eur J Orthod 1986;8:80-3.

Kecik D, Kocadereli I, Saatci I. Evaluation of the treatment changes of functional posterior crossbite in the mixed dentition. Am J Orthod Dentofacial Orthop 2007;131:202-15.

Kennedy DB, Osepchook M. Unilateral Posterior Crossbite with mandibular shift: a review. J Can Dent Ass. 2005;71:569-73.

Kurol J, Bergland L. Longitudinal study and cost-benefit analysis of the effect of early treatment of posterior cross-bites in the primary dentition. Eur J Orthod 1992;14:173-79.

Lagravere MO, Major PW, Flores Mir C. Long term dental arch changes after rapid maxillary expansion treatment: a systematic review. Angle Orthod 2004;75:155-61.

Lagravere MO, Major PW, Flores-Mir C. Long-term skeletal changes with rapid maxillary expansion: a systematic review. Angle Orthod 2005;75:833-39.

Lima AL, Lima Filho RM, Bolognese AM. Long-term clinical outcome of rapid maxillary expansion as the only treatment performed in Class I malocclusion. Angle Orthod 2005;75:416-20.

Lione R, Ballanti F, Franchi L, Baccetti T, Cozza P. Treatment and post-treatment skeletal effects investigated by low-dose computed tomography in growing subjects. Am J Orthod Dentofacial Orthop 2008;134:389-92.

McNamara JA Jr, Lione R, Franchi L, Angelieri F, Cevidanes LHS, Darendeliler MA, Cozza P. The role of rapid maxillary expansion in the promotion of oral and general health. Prog Orthod 2015;16:33.

McNamara JA Jr. Early intervention in the transverse dimension: is it worth the effort? Am J Orthod Dentofacial Orthop 2002;121:572-4.

Nerder PH, Bakke M, Solow S. The functional shift of the mandible in unilateral posterior crossbite and the adaptation of the temporomandibular joints a pilot study. Eur J Orthod 1999;21:155–66

O'Grady PW, McNamara JA Jr, Baccetti T, Franchi L. A long-term evaluation of the mandibular Schwarz appliance and the acrylic splint expander in early mixed dentition patients. Am J Orthod Dentofacial Orthop 2006;130:202-13.

Petrén S, Bondemark L, Söderfeldt BA. Systematic review concerning early orthodontic treatment of unilateral posterior crossbite. Angle Orthod 2003;73:588-96.

Pinto A, Buschang P, Throckmorton G. Morphological and positional asymmetries of young children with functional unilateral posterior crossbite. Am J Orthod Dentofacial Orthop 2001;120:513-20.

Subtelny JD, Subtelny JD. Oral habits - studies in form, function and therapy. Angle Orthod 1973;43:349-83.

Thilander B, Wahlund S, Lennartsson B. The effect of early interceptive treatment in children with posterior crossbite. Eur J Orthod 1984;6:25-34.

Tollaro I, Baccetti T, Franchi L, Tanasescu CD. Role of posterior transverse interarch discrepancy in Class II, division I malocclusion during the mixed dentition phase. Am J Orthod Dentofacial Orthop. 1996;110:417-22.

Vizzotto MB, de Araújo FB, da Silveira HE, Boza AA, Closs LQ. The quad-helix appliance in the primary dentition-orthodontic and orthopedic measurements. J Clin Pediatr Dent 2008;32:165-70.

Westwood PV, McNamara JA Jr, Baccetti T, Franchi L, Sarver DM. Long-term effects of Class III treatment with rapid maxillary expansion and facemask therapy followed by fixed appliances. Am J Orthod Dentofacial Ortho. 2003;123:306-20.

SAGITTAL DIMENSION PROBLEMS

These problems can have the greatest impact on the population in terms of prevalence and peculiarity of some clinical pictures. They are often associated with transverse and vertical dimension problems.

Family history for sagittal problems, congenital and environmental factors, causing dentoalveolar discrepancies and changes in the normal growth pattern of the jaws play an important role in the etiopathogenesis of sagittal dimension problems.

Family history for sagittal discrepancies plays a fundamental role, particularly in Class III cases and in some Class II malocclusions. Since they modify muscular balance, functional alterations (e.g., bad habits and breathing patterns) can cause and/or contribute to causing Class II malocclusions. Altered lingual posture and/or a short lingual fraenum can contribute to the development of Class III malocclusions.

Clinically malocclusions on the sagittal plane can be subdivided into Class I, Class II and Class III malocclusions.

From an occlusal point of view, they have the following features:

- Class I: correct sagittal occlusion with limited alterations often found in the anterior segment and/or on the transverse and vertical planes;
- Class II: occlusions characterised by altered sagittal relationships of the arches, with mandibular teeth distally occluding in relation to maxillary teeth. The following types of occlusion can be observed:

► Class II/1: narrow and long upper arch with protruded front teeth;

► Class II/2: retrusion and crowding of maxillary front teeth, usually maxillary central incisors, with forward inclination of maxillary lateral incisors, often associated with a slight maxillary constriction and, usually, a retruded mandible.

- Class III: occlusions characterised by altered sagittal relationships of the arches with mandibular teeth mesially occluding in relation to maxillary teeth; the mandible can be mildly or markedly protruded (Baccetti 1998).

Clinical and cephalometric assessments based on lateral head films are useful for diagnostic, prognostic and therapeutic purposes.

In Class I cases, clinical problems are usually of a dental nature (crowding, mesialisation, teeth rotation, upper anterior protrusion, etc.) and could affect the vertical and transverse planes.

In Class II cases, the maxillo-mandibular sagittal discrepancy is due to a maxillary protrusion, i.e., a mandibular retrusion (80% of cases) or both conditions.

In Class III cases, the maxillo-mandibular sagittal discrepancy is caused by a protrusion of the lower jaw in relation to the maxilla, namely retrusion/hypoplasia of the upper jaw in relation to the lower jaw or both conditions.

In sagittal malocclusions, concurrent problems/alterations on the vertical and/or transverse planes can be crucial for diagnostic, prognostic and therapeutic purposes (Baccetti 2004).

In growing patients, establishing the stage of skeletal development through a preliminary assessment of vertebral maturation index on a lateral head film can be useful; a wrist and hand X-ray should be prescribed if the orthodontist believes that further tests are required.

Treatment strategies vary according to the overall clinical picture (Proietti 2000).

- Class I cases: due to dental problems as such; their correction must take into account patient's profile and facial type as well as dental, skeletal, vertical and transverse parameters. When space is a problem, for instance, the solution can be extraction or non-extraction treatment but only after assessing clinical and radiographic parameters.

- Class II cases with:

- maxillary hyperplasia/protrusion: in growing patients, treatment should aim at influencing/controlling maxillary growth with orthopaedic appliances (e.g., orthopaedic treatment);

- mandibular hypoplasia/retrusion: in growing patients, functional procedures aimed at stimulating/promoting mandibular growth and/or promoting correct mesial positioning (e.g., functional treatment) can be recommended;

- maxillary hyperplasia protrusion associated with mandibular hypoplasia/retrusion: in growing patients, treatment can aim at influencing/controlling the growth of the upper jaw by also using functional appliances that stimulate/promote mandibular growth (e.g., combined treatment);

In cases of mandibular retrusion, correction at the peak of the mandibular growth could be an effective treatment strategy. This is the time when the lower jaw has the greatest growth potential; treatment can therefore be optimised in terms of effectiveness, timing and patient's compliance although some Authors maintain that treatment during other stages of growth is just as effective (Pancherz 1997, Ruf 1999).

In some Class II cases, characterised by a combination of crowding and/or increased overjet, early treatment might be required (trauma-*p*rophylaxis if there is a large overjet).

In "mixed" cases (maxillary hyperplasia/protrusion associated with mandibular hypoplasia/retrusion), orthopaedic and functional appliances can be used at the same time but need to be designed on the basis of vertical and transverse implications (McNamara 1996).

Any combination of transverse dimension problems is often a priority within the overall clinical picture as in Class II cases transverse expansion can improve and promote the correction of sagittal

relationships (maxillary expansion: endogenous functional appliance) (Cozza 2006, Dolce 2007, Ghafari 1998).

- Class III cases: given the different growth patterns of the mandible in relation to the maxilla and the functional factors and family history for problems related to these clinical condition, early treatment of the maxillary arch is crucial in order to restore correct sagittal relationships. Delaying correction until the peak of mandibular growth when the lower jaw shows the greatest growth spurt is not advisable (Battagel 1993).

Class II and Class III sagittal problems, if dealt at the end of growth, can be solved by dental compensations. However, in severe skeletal discrepancy and when dental compensation can be affected by gnathologic problems and/or for aesthetic reasons, a combined surgical/orthopaedic treatment could be the best indication (Tulloch 1997, Tulloch 1998).

In sagittal malocclusion cases, a clinical examination and a cephalometric analysis of the lateral head film and, if necessary, an auxological assessment of the wrist and hand X-rays are vital for a full understanding of the malocclusion both from a dental and a skeletal point of view.

In Class II cases, treatment predictability is always related to the facial type (vertical dimension) and the transverse dimension (any asymmetries) and can affect prognosis. Orthopaedic-functional treatment of Class II malocclusions due to mandibular retrusion is particularly effective if it includes the peak of mandibular growth although some Authors maintain that correcting during other stages of growth is just as effective (Firouz 1992, Keeling 1998, Johnston 2005).

In Class III cases, orthopaedic correction is more complex, particularly in cases of true mandibular excess or prognathism. Orthopaedic treatment seems to be more successful in correcting maxillary retrusion. Applying a reverse pull headgear (face mask) can have positive effects if performed pre-pubertally (7-8 years of age). After the age of 10, orthopaedic treatment predictability with postero-anterior pull is dramatically reduced. Prognosis for these malocclusions is, however, guarded (Kapust 1998, Sugawara 1997, Westwood 2003).

Implications on the vertical plane affect prognosis and treatment planning (Harrison 2007).

Usually, correcting concurrent problems on the transverse plane is a priority when faced with problems in other planes too (Von Bremen 2002, Wheeler 2002).

Bibliography

Baccetti T et al. Skeletal effects of early treatment of Class III malocclusion with maxillary expansion and face-mask therapy. Am JOrthod Dentofacial Orthop 1998;113:333-343.

Baccetti T. Interview on Functional Appliances. Progress in Orthodontics 2004;5:179-183

Battagel J. The aetiological factors in Class III malocclusion, Eur J Orthod 1993;15:347-370.

Cozza P, Baccetti T, Franchi L, De Toffol L, McNamara JA Jr. Mandibular changes produced by functional appliances in Class IImalocclusion: A systematic review. Am J Orthod Dentofacial Orthop. 2006;129:599e1-599e12.

Dolce C, McGorray SP, Brazeau L, King GJ, Wheeler TT. Timing of Class II treatment: skeletal changes comparing 1-phase and 2-phase treatment. Am J Orthod Dentofacial Orthop. 2007;132:481-9.

Firouz M, Zernik J, Nanda R. Dental and orthopedic effects of high-pull headgear in treatment of Class II, division 1 malocclusion, AmJ Orthod Dentofacial Orthop.1992;102:197-205.

Ghafari J et al. Headgear versus function regulator in early treatment of Class II , division 1 malocclusion: a randomized clinicaltrial, Am J Orthod Dentofacial Orthop 1998;102:197-200.

Harrison JE, O'Brien KD, Worthington HV. Orthodontic treatment for prominent upper front teeth in children Cochrane Database SystRev. 2007 Jul 18;(3):CD003452.

Johnston LE. If wishes were horses: Functional appliances and growth modification. Progress in Orthodontics 2005;6(1):36-47

Kapust AJ, Sinclair PM, Turlay PK. Cephalometric effects of face mask/expansion therapy in Class III children: a comparison of threegroups. Am J Orthod Dentofacial Orthop 1998;113:204-212.

Keeling SD et al. Anteroposterior skeletal and dental changes after early Class II treatment with bionators and headgear, Am JOrthod Dentofacial Orthop 1998;113:40-50.

McNamara JA Jr, Peterson JE Jr, Alexander RG. Three-dimensional diagnosis and management of Class II malocclusion in the mixeddentition. Semin Orthod. 1996;2:114-37.

Ngan PW et al. Treatment response and long-term dentofacial adaptions to maxillary expansion and protraction, Semin Orthod1997;3:255-264.

Pancherz H, Zieber K, Hoyer B. Cephalometric characteristics of Class II division 1 and Class II division 2 malocclusions: acomparative study in children, Angle Orthod 1997; 67:111-120.

Proietti D, Barbato E., Malagola C.. Il timing di trattamento delle malocclusioni. Mondo Ortodontico 2000:XXV(3):205-217.

Ruf S, Pancherz H. Class II division 2 malocclusion: genetics or environment? A case report of monozygotic twins, Angle Orthod1999; 69:321-324.

Sugawara J, Mitani H. Facial growth of skeletal Class III malocclusion and the effects, limitations, and long-term dentocialadaptations to chin cap therapy, Semin Orthod 1997; 3:244-254.

Tulloch JF et al. The effect of early intervention on skeletal pattern in Class II malocclusion: a randomized clinical trial, Am J OrthodDentofacial Orthop 1997; 111:391-400.

Tulloch JFC, Phillips C, Proffit WR. Benefit of early Class II treatment: progress report of a two-phase randomized clinical trial, Am JOrthod Dentofacial Orthop 1998;113:62-72.

Von Bremen J, Pancherz H. Efficiency of early and late Class II Division 1 treatment. Am J. Orthod Dentofac Orthop. 2002;121: 31-37.

Westwood PV, McNamara JA Jr, Baccetti T, Franchi L, Sarver DM. Long-term effects of Class III treatment with rapid maxillaryexpansion and facemask therapy followed by fixed appliances. Am J Orthod Dentofacial Orthop. 2003;123:306-20.

Wheeler TT, McGorray SP, Dolce C, Taylor MG, King GJ. Effectiveness of early treatment of Class II malocclusion. Am J OrthodDentofacial Orthop. 2002;121:9-17.

VERTICAL DIMENSION PROBLEMS

Vertical problems can cause alterations to facial aesthetics as well as functional problems; they need early treatment in order to re-establish oral, functional and physiological conditions and promote the physiological growth of the jaws. Furthermore, an increase in the vertical dimension (open bite) can alter the chewing function whereas its reduction (deep bite) can cause periodontal problems to maxillary and mandibular incisors in particular. Vertical problems can present themselves on their own or be associated with sagittal or transverse problems.

Hereditary and anatomical factors play a fundamental role in the etiopathogenesis of vertical problems. Functional aspects are a major cause for the onset and development of these clinical conditions and, unless they are corrected, they can become a contributing factor for relapse.

As regards the clinical picture, there are different types of vertical problems: skeletal, dentoalveolar and functional; in most cases, however, malocclusions are caused by a combination of these conditions. The vertical dimension is assessed by studying the proportion of relationships between the upper, mid- and lower face.

Clinical conditions characterised by vertical alterations are open and deep bites.

Open bites can present negative overbites and are often associated with functional alterations (e.g., bad habits or oral breathing). They can be skeletal or dentoalveolar:

► skeletal open bites are generally caused by excessive vertical maxillary growth; they are characterised by a long face, lip incompetence at rest (>4mm), evident gummy smile and, in Class I skeletal cases, but, in particular, in Class II cases, poor chin prominence due to posterior mandibular rotation. Dental arches can be narrow, the palate vault is high, front teeth are labially positioned and there is a negative overbite. The maxillary and mandibular planes can be canted with a high angle. The condyle shows a distal inclination and the gonial angle is obtuse;

► dentoalveolar open bites are due to extrusion of molars and/or intrusion of front teeth.

If there are functional problems, tongue interposition or mechanical obstructions due to finger or pacifier sucking can cause an anterior open bite, starting sometimes from the first premolars and/or canines with consequent infra-eruption of maxillary and/or mandibular incisors.

In “purely” dental and functional cases, the anomaly does not affect the jaws; the lower vertical dimension can, in fact, be normal or even reduced, particularly in short face patients. In those cases where there is an open bite in the anterior segment only, a more correct definition is anterior open bite (Janson 2008).

Deep bites are generally accompanied by a vertical deficiency and are characterised by an increased overbite. Deep bites can be skeletal, dental, or mixed.

From an aesthetic point of view, brachycephalic patients present large and square faces, reduced distance between the upper lip and the chin, a deeper mento-labial sulcus and a relatively prominent chin.

Intraorally, the arches are wide and square shaped; in some cases, there are also diastemas and an increased overbite. In the most serious cases, the incisal edges of the mandibular incisors touch the palate in occlusion.

In dento-skeletal deep bite cases, an over-eruption of incisors with an under-eruption of posterior and lateral teeth and consequent deepening of the Curve of Spee are sometimes present. There can also be a low angle with a tendency to parallelism of mandibular and maxillary planes, a very closed gonial angle due to a forward rotation of the mandible, excessive height of the mandibular ramus, and a condylar growth pattern going forward and upward.

In "purely" dentoalveolar cases, the anomaly is confined to teeth, in particular an over-eruption of front teeth; the skeletal vertical dimension, however, is not altered.

Further local dental factors, potentially related to deep bite, are multiple ageneses that can further reduce the vertical dimension, particularly in brachycephalic patients.

Diagnosis is based on an intra-oral clinical examination to assess: a) dental arches; b) occlusal relationships in the three planes of space; and c) features and position of soft tissues, particularly the tongue, using a static and dynamic analysis, both at rest and when swallowing and speaking.

Furthermore, by studying casts, an accurate analysis of the occlusion is possible; extra- and intra-oral pictures can be useful to assess the proportions between upper, mid and lower face as well as any asymmetry (Lentini 2007).

A cephalometric assessment based on lateral head film and, whenever the orthodontist deems it necessary, in postero-anterior projection, can contribute to formulating a differential diagnosis on the skeletal, dento-alveolar or mixed origin of the anomaly.

More specifically, a lateral cephalometric analysis is useful to assess the angle between the maxilla and the mandible as well as the growth pattern. The facial skeletal type and the nature of the anomaly can therefore be classified. Teeth position in relation to the jaws and soft tissues can be assessed as well.

If deemed necessary and on the basis of collected data, advice from other clinicians (e.g., maxillofacial surgeons, ENT specialists, phoniatricians) can be requested in order to obtain a complete diagnosis.

A correct diagnosis, the patient's age as well as the various vertical and transverse implications are all fundamental for treatment planning.

Early clinical signs suggest the adoption of treatments that try and change the growth pattern and promote the control of functional attitudes that tend to exacerbate the anomaly.

Different cases of malocclusions can be corrected with orthodontic treatment only when they are mainly dental or borderline.

In growing patients, the vertical skeletal discrepancy can be corrected or, at least, controlled with a targeted myofunctional treatment in conjunction with an orthopaedic/orthodontic treatment.

In fully-grown patients, skeletal problems caused by an altered growth of the jaws can be corrected with an orthodontic-surgical approach (Ren 2007).

Alterations on the vertical plane can either be isolated or associated with problems on the sagittal and transverse planes.

An increase in the vertical dimension (open bite) can alter the chewing function whereas a marked reduction of the vertical dimension (deep bite) can cause periodontal problems to maxillary and mandibular incisors in particular (Millet 2006).

Early clinical signs suggest the adoption of treatments that try to counter the growth pattern and promote the control of postural and functional alterations that tend to exacerbate the anomaly with possible aesthetic repercussions. Early treatment can re-establish correct oral and functional conditions and restore physiological growth of the jaws (Ngan 1997).

In treating vertical alterations, diagnosis and early correction by eliminating any bad habit, identification and correction of breathing problems by re-educating lingual muscles and function are fundamental.

In order to re-establish and stabilise a correct function and, therefore, prevent relapse and ensure stability of orthodontic treatment results, assessment by a speech therapist and an ENT specialist can be included in the treatment plan (Feres 2016).

Bibliography

Feres M, Abreu L, Insabralde N, De Almeida M, FloresMirC. Effectiveness of open bite connection when managing deleterious oral habits in growing children and adolescents: a systematic review and meta-analysis. Eur J Orthod 2016 Feb 3

Janson G, Crepaldi MV, de Freitas KM, de Freitas MR, Janson W. Evaluation of anterior open-bite treatment with occlusal adjustment. Am J Orthod Dentofacial Orthop. 2008;134:10-1.

Lentini-Oliveira D, Carvalho FR, Qingsong Y et al. Orthodontic and orthopaedic treatment for anterior open bite in children.Cochrane Database Syst Rev. 2007 Apr 18;(2):CD005515.

Millett DT, Cunningham SJ, O'Brien KD et al. Orthodontic treatment for deep bite and retroclined upper front teeth in children.Cochrane Database Syst Rev. 2006 Oct 18;(4):CD005972.

Ngan P, Fields HW. Open bite: a review of etiology and management. Pediatr Dent. 1997;19:91-8.

Ren Y. Treating anterior open bite. Evid Based Dent. 2007;8:83.

SPACE MANAGEMENT

Space problems are not uncommon. In general, they may result from a variety of factors, such as: arch length-tooth size discrepancy when the space for teeth is insufficient (crowding) or excessive (diastemas); early loss of deciduous teeth with consequent migration of the adjacent permanent teeth; loss of leeway space for the unerupted or partially erupted permanent teeth; agenesis of one or more teeth; abnormalities in the transition from deciduous to permanent dentition with ectopic eruption or impaction of permanent teeth; presence of supernumerary teeth; microdontia.

Diagnosis is based on the traditional criteria and tools: collection of case history and careful clinical examination with particular attention to extra-oral shape and characteristics, orofacial muscles and soft tissues and specific features of teeth and periodontal tissues.

Clinical data can be combined with information provided by casts of dental arches to evaluate arch length and tooth size discrepancies, and intra- and inter-arch relationships, especially transverse width.

An OPG of dental arches can help the clinician in assessing the dental formula, tooth position relationships and possible abnormalities in number, position, location and sometimes shape of teeth, as well as the presence of lesions (carious, endodontic, periodontal, cystic, etc.). Although an orthopantomogram provides less information on anatomic details than intraoral X-rays, it does provide a good general view of dental arches and alveolar and bone structures. Whenever diagnosis is uncertain, periapical or occlusal intraoral X-rays can be helpful, and the clinician can also collect 3D images as an alternative or an adjunct. Especially in cases of tooth impaction 3D imaging provides correct information on the impacted tooth position in the three planes of space and its relationship with adjacent teeth.

Lateral head films illustrate skeletal features and the position of teeth on the antero-posterior plane as well as the type of inclination of each tooth relative to the upper or lower jaw. Such factors can often play a key role in the choice of the best treatment to gain space.

The type of space management problem involved will drive treatment planning.

When there is an arch length-tooth size discrepancy, the transverse and anterior limits of dentition must be identified, even though, so far, there are no objective parameters that can guarantee the success of treatment and its long-term stability.

In case of early loss of deciduous teeth with consequent migration of adjacent permanent teeth and loss of space for the corresponding unerupted or partially erupted teeth, it is a priority to maintain continuity of the dental arch by restoring, first of all, the shape and size of primary teeth if affected by caries. Following an early loss of a deciduous tooth, using a space maintainer for the corresponding permanent tooth is decisive; if permanent teeth migration has already occurred, it may be appropriate to resort to

space recovery and re-alignment/repositioning of migrated teeth (Brothwell 1997, Lin 2007, Park 2009).

In cases of agenesis of one or more teeth, with consequent space management problems, an in-depth evaluation is required.

After the third molars, the most frequently congenitally missing teeth are mandibular second premolars, maxillary lateral incisors and maxillary second premolars. A delay in the transition to one or more permanent teeth with respect to the expected eruption period may be suggestive of agenesis and an OPG will help achieve diagnostic certainty. The treatment plan must be established based on the patient's age, facial type, profile, overall occlusal condition and cephalometric parameters. The most appropriate treatment solution will have to be selected taking into account aesthetic, skeletal, functional and dental parameters (eg possible crowding or generalised spacing and dento-periodontal conditions of erupted teeth).

There are basically two possible treatment options: closing the space(s) of the congenitally missing tooth/teeth or traditional tooth replacement with a conventional or adhesive prosthesis or a dental implant. Space closure does not require prosthetic restoration but it should preferably be orthodontically performed at an early stage, and requires long-term retention and possibly corrective coronoplasty. Prosthetic and/or implant replacement must, however, be postponed until the end of growth.

With some rare exceptions (good occlusion with space for missing teeth/almost complete space closure), both solutions can have advantages and disadvantages depending on a number of factors including, of course, the patient's acceptance of a long orthodontic treatment (Sabri 2008, Tunison 2008)

Arch length-tooth size discrepancy can result from anomalies in dental transition and eruption with severely ectopic or impacted permanent teeth.

Ectopic teeth result from general arch length-tooth size discrepancy with dental crowding.

The picture is different in case of impacted teeth. With the exception of involvement of third molars the primary objective, if possible, should always be the recovery of the impacted tooth, especially in the case of front teeth and maxillary canines considering their important aesthetic or functional role.

In case of impacted teeth the clinician can request 3D imaging providing a full three-dimensional representation of the tooth morphology, position and relationship with adjacent teeth. Such 3D images can play a key role when establishing prognosis and treatment.

With the exception of very simple cases, disimpaction procedures must be performed using appliances that allow a careful control of the movements of impacted teeth (Laing, 2009).

Timely treatment of deciduous teeth is mandatory to preserve continuity of dental arches. The preservation of tooth substance will prevent mesial inclination and displacement as well as rotations of adjacent teeth, resulting in space loss in the arch and extrusion of opposite teeth, with a number of possible repercussions on inter-arch relationships.

More complex clinical cases (eg agenesis, infra-occlusion of deciduous teeth in association with agenesis or dystopia of permanent teeth, tooth impaction) require the assessment of the various clinical and radiographic parameters, patient age and needs and overall analysis of the case in the three dimensions, with the use of 3D imaging whenever the clinician deems it necessary. (Park 2009).

In particular, 3D X-ray investigations may prove valuable in cases of tooth impaction where combined surgical-orthodontic treatment is indicated. A three-dimensional representation of dental arches provides information on the tooth morphology, position and relationship with neighbouring structures which may be highly valuable for diagnostic, prognostic and therapeutic decision-making.

A combined surgical-orthodontic approach must take into account the position of both the crown and the root of the impacted tooth in order to obtain a correct crown-root inclination of the repositioned tooth in the arch.

Bibliography

Brothwell DJ. Guidelines on the use of space maintainers following premature loss of primary teeth. J Can Dent Assoc. 1997; 63:753,757-60, 764-6.

Laing E, Ashley P, Naini FB, Gill DS. Space maintenance. Int J Paediatr Dent. 2009;19:155-62.

Lin YT, Lin WH, Lin YT. Immediate and six-month space changes after premature loss of a primary maxillary first molar. J Am DentAssoc. 2007;138:362-8.

Park K, Jung DW, Kim JY. Three-dimensional space changes after premature loss of a maxillary primary first molar. Int J PaediatrDent. 2009;19:383-9. Epub 2009 Apr 16.

Sabri R. Management of over-retained mandibular deciduous second molars with and without permanent successors. World J Orthod.2008; 9:209-20.

Tunison W, Flores-Mir C, ElBadrawy H, Nassar U, El-Bialy T. Dental arch space changes following premature loss of primary firstmolars: a systematic review. Pediatr Dent. 2008;30:297-302.

ASYMMETRIES

Facial asymmetries are alterations of the dento-maxillofacial complex that can be classified on the basis of a careful dental, skeletal and functional evaluation. They may occur early as a result of alterations of the dentoalveolar and skeletal components and need to be treated equally early to prevent the onset and/or stabilization of skeletal alterations.

Some infrequent forms may occur later; in such clinical conditions early intervention has no effect and sometimes can even be contraindicated. Therefore it is preferable to implement an orthodontic-surgical approach at the end of growth.

Asymmetries are one of the most difficult problems to tackle because of the complexity of the diagnostic procedure, the prognostic evaluation and the treatment timing decision. The latter requires careful consideration of the etio-pathogenetic factors contributing to the establishment of the clinical condition (Akhil 2015).

From an etio-pathogenetic and clinical point of view it is appropriate to classify asymmetries as positional (or functional), structural and caused by growth alteration.

Positional or functional asymmetries can arise from a dentoalveolar contraction of the upper jaw caused by functional abnormalities (e.g. oral habits, abnormal breathing pattern), by occlusal interferences, usually involving deciduous canines, or by a real jaw hypoplasia resulting in lateral deviation of the lower jaw and unilateral cross-bite. In some cases, characterized by a deep bite and a normal occlusion, the tendency to rotate the mandible (inwards rotation), both positionally and with its dentoalveolar complex, may result in a Class II subdivision malocclusion (Class I on one side and Class II on the contra-lateral one) (Kecik 2007).

Usually, structural asymmetries result from untreated positional asymmetries and consequent early asymmetric growth of the mandible, with unilateral mandibular hypoplasia corresponding to the side of the cross-bite and a vicarious lengthening of the other side. The TMJ on the cross-bite side does not grow forward while the other side tends to shift forward and downward. Similar considerations can be made in the case of inward rotation, where there is not a cross-bite but a deep bite; the problem affects the dentoalveolar complex first and then the bone structure.

Positional or functional asymmetries and structural asymmetries can occur at a very early age in deciduous dentition and are generally due to a slight constriction of the maxilla with mandibular lateral deviation, unilateral cross-bite and displacement of the inferior midline towards the cross-bite side, which self-correct during mouth opening (see transverse dysgnathias). Concomitant canting of the maxillary occlusal plane with compensatory extrusion of maxillary teeth may be present. Over time the asymmetry becomes more evident, with chin deviation, asymmetry of gonial angles (with a wider angle contra-laterally to the deviation) and finally, on the side of the deviation, a downward canting of the upper jaw. Also asymmetries with "inward rotation" develop early. They are characterized by a deep bite and asymmetric occlusal relationships, Class I on one side and Class II on the opposite side (Haraguchi 2008).

Unilateral growth asymmetries can be distinguished in two different forms caused by either growth deficiency or excessive growth.

Asymmetries caused by excessive growth, characterized by hemimandibular elongation, hemi-mandibular hyperplasia or unilateral condylar hyperplasia, can develop at a very early age and early treatment can fail; more often they occur during adolescence in subjects with a tendency to Class III malocclusion.

In the forms caused by hemi-mandibular elongation, the mandible may appear structurally longer on one side, both in the ramus and the body of the mandible, which may sometimes appear thinner. The gonial angle on the same side is wider and the chin is deviated contra-laterally. There is a cross-bite on the other side and deviation of the lower midline in the same direction. It is often associated with micrognathia of the upper jaw, which has always a downward canting on the abnormal side.

Frontally, gonial angles can appear at the same height; during opening midlines are not centred and an increase in midline shift can be observed instead.

In hemi-mandibular hyperplasia, the ramus and the body of the mandible on the side affected by the asymmetry can be elongated and thicker with a narrower gonial angle; mandibular teeth are generally inclined on the affected side and this can result in a lateral open bite. Sometimes the midline is not shifted or inclined toward the affected side; viewed frontally the level of the two gonial angles differ and the same applies to the lower margin of the jaw while the chin is not deviated. At mouth opening the mandible deviates towards the affected side.

Condylar hyperplasia has a rather sudden onset and it develops quickly, generally towards the end of growth. It is an excessive growth in length and volume of one mandibular condyle with a consequent variable degree of asymmetry. It can cause a mandibular deviation on the opposite side with lower midline shift, opening of the bite on the affected side and, generally, absence of vertical compensation of maxillary teeth due to the rapid evolution of such abnormality.

Mixed forms are difficult to place in one of the previous categories. Unlike structural positional abnormalities, when TMJ disorders occur they tend to be contralateral to chin deviation and on the same side of the alteration (Obwegeser 1986).

The forms caused by insufficient growth may be divided into hemi-mandibular hypoplasia (hemi-facial microsomia, an embryopathy affecting chondrogenesis) or unilateral condylar hypoplasia (often of congenital or post-traumatic origin). The latter appears rarely in a pure form and is often associated with unilateral hyperplasia and elongation, with shorter segments, a condyle tendency to hypoplasia and a short neck; there is also a midline and chin deviation. Condylar hypoplasia can be congenital, although it can sometimes have a traumatic origin. The chin deviation on the same side becomes more marked during mouth opening (Obwegeser 2007).

From the diagnostic point of view, in the context of positional or functional asymmetries and of structural asymmetries, closed-mouth extra-oral clinical examination can detect signs of asymmetry

with a deviation of the chin, which is corrected by mouth opening. Intra-oral clinical examination can confirm this finding, showing a unilateral cross- or deep bite, and midline deviation on the side of the cross-bite. There may be asymmetric dental relationships with a tendency to Class II malocclusion on the side of the cross-bite and Class I malocclusion on the other side. Midline centring during mouth opening is proportional to the functional contribution given to the asymmetry and progressively reduces as asymmetry becomes structural. In addition, a careful functional examination of muscular structures and temporomandibular joints is crucial to stave off the potential risk of temporomandibular disorders (Azevedo 2006).

The OPG provides useful preliminary data on morphological and structural characteristics but it is not highly reliable for the assessment of dimensions. A PA head film can be useful for diagnostic and prognostic purposes, and the clinician can choose to supplement it with other 2D studies, such as head films of the mandible in the submentovertex (basal) projection, oblique mandibular X-rays and stratigraphy of temporomandibular joints or any other 3D imaging investigations (3D CT scan). Finally, bone scintigraphy can be indicated to ascertain any residual growth and choose the best timing for surgery.

For asymmetries caused by abnormal growth, extra-oral clinical examination can detect peculiar morphological characteristics of the mandibular and gonial angles, including a mandibular deviation at maximum opening. At the intra-oral examination, a peculiar inclination of teeth and an open bite can be found. These features and signs are much less evident in early childhood (Yazdani 2010).

Positional or functional asymmetries and structural asymmetries should be treated early during the growth period in order to prevent or limit the effects of asymmetry on skeletal structures. In some cases treatment can restore correct maxillo-mandibular relationships (Harrison 2001).

The most indicated procedures for growing patients are:

- slow maxillary expansion with dento-alveolar effect, in case of moderate constriction;
- rapid maxillary expansion with diastasis of the median palatal suture if the transverse anomaly is due to a skeletal alteration;
- deep bite correction in cases of inward rotation;
- Functional appliances can also be used to promote mandibular centering and symmetrical growth or during retention (McNamara 2002).

In adolescent patients particular attention must be paid to jaw centring to prevent joint disorders.

In adulthood, orthodontic-surgical treatment is mandatory since the positional deviation component is minimum.

In cases of inward rotation expansion must be accompanied by deep bite correction as soon as possible so as to regain symmetry of the mandible and of the related dento-alveolar component.

The clinician must rule out any orthopaedic treatment aiming at mandibular centring when asymmetries are caused by growth abnormalities; when there is excessive growth, or alterations that cannot be controlled, and especially when there are dysfunctional symptoms which would be worsened by a restoration of the symmetry, moreover whenever an attempt to correct a mandibular asymmetry fails and a refractoriness to correction is noticed diagnosis must be reconsidered at once.

Therefore, in fully grown patients joint orthodontic and surgical treatment is needed with the aim of correcting occlusion and skeletal asymmetry and achieve a consequent improvement of facial profile.

As early as in deciduous dentition particular attention must be paid to possible unilateral cross-bites induced by lateral deviation of the lower jaw and constrictions of the upper jaw, canting of the maxillary occlusal plane and compensatory extrusion of maxillary teeth, as over the years they may result in structural asymmetries (Kennedy 2005).

Special attention should also be paid to the less evident but not less significant forms of inward rotation which develop early and are characterized by deep bite and asymmetric occlusal relationships.

In cases of excessive growth the alteration is difficult to control. Whenever it is accompanied by dysfunctional symptoms, which would be worsened by any treatment aimed at restoring a symmetrical occlusion, orthopaedic-orthodontic treatments to centre the mandible must be ruled out since a joint orthodontic-surgical approach would be preferable.

Bibliography

Akhil G, Senthil Kumar KP, Raja S, Janardhanan K. Three-dimensional assessment of facial asymmetry: a systematic review. J Pharm Bioallied 2015 Aug 7 s433-7

Azevedo AR, Janson G, Henriques JF, Freitas MR. Evaluation of asymmetries between subjects with Class II subdivision and apparent facial asymmetry and those with normal occlusion. Am J Orthod Dentofacial Orthop. 2006;129:376-83.

Haraguchi S, Iguchi Y, Takada K. Asymmetry of the face in orthodontic patients. Angle Orthod. 2008;78:421-6.

Harrison JE, Ashby D. Orthodontic treatment for posterior crossbites. Cochrane Database Syst Rev. 2001;1.

Kecik D., Kocadereli I, Saatci I. Evaluation of the treatment changes of functional posterior crossbite in the mixed dentition. Am JOrthod Dentofacial Orthop. 2007;131:202-15.

Kennedy DB, Osepchook M. Unilateral Posterior Crossbite with Mandibular Shift: A Review. J Can Dent Assoc 2005;71:569–73.

Mc Namara J.A. Jr. Early intervention in the transverse dimension: is it worth the effort?, Am. J. Orthod Dentofacial Orthop 2002;121: 572-4.

Obwegeser JA. Maxillary and midface deformities: characteristics and treatment strategies. Clin Plast Surg. 2007;34:519-33. Review.

Obwegeser HL, Makek MS. Hemimandibular hyperplasia--hemimandibular elongation. J Maxillofac Surg. 1986;14:183-208.

Yazdani J, Talesh KT, Motamedi MH, Ghavimi MA. Changes in the gonial Angle Following Bilateral Sagittal Split Osteotomy and Vertical Ramus Osteotomy for Mandibular Excess. Eplasty. 2010; 10: e 20. Published online 2010 February 23.

MULTIDISCIPLINARY APPROACH

As the demand for orthodontic treatment for aesthetic or functional purposes is growing among the adult population, a multidisciplinary approach is sometimes needed. Orthodontic treatment can sometimes help periodontal and prosthetic interventions to correct occlusal problems.

Once diagnosis is established, precise treatment goals must be set, together with the proper timing of the various procedures and treatment methods that need to be appropriate for each of the various possible clinical conditions involved.

Dento-maxillofacial disorders - Pre-surgical orthodontics (surgical-orthodontic and borderline cases).

The difference between "orthodontic patients" and "surgical patients" is not always so clear-cut. Between the two extremes there are those cases defined as "borderline" that can be treated either with an orthodontic treatment of dental compensation (camouflage) or with surgical repositioning of the jaws in the three dimensions (Kinzinger 2009, Tucker 1995).

The objectives of orthodontic-presurgical treatment are often the opposite of those of conventional orthodontic treatment. Therefore, it is indicated to choose from the outset whether to adopt a conventional approach or to foresee successive surgery.

After careful diagnosis, the treatment plan must conclusively establish its specific objectives.

With regard to diagnostic evaluation, clinical examination is decisive when there are indications for orthodontic-surgical treatment. A joint evaluation by an orthodontist and a maxillofacial surgeon is needed to optimise outcome and both clinicians must carefully take into account each patient's requirements and expectations.

The information provided by static and dynamic, frontal and lateral extra-oral clinical examination must then be correlated with cephalometric data; the overall assessment is conclusive for diagnostic, prognostic and therapeutic purposes.

Extra-oral clinical examination performed according to the concept of "full face analysis" can highlight the relationships between facial structures in static and dynamic positions (smile, speech) (Arnett 1993, Arnett 1993 part II, Arnett 1999).

It provides data on all significant aesthetic elements inherent to profile characteristics, vertical relationships between the upper, mid- and lower face, chin and chin-to-neck distance.

Cephalometric analysis of hard tissues in the dento-maxillofacial complex performed on both lateral and postero-anterior projections and cephalometric analysis and evaluation of soft tissues play a key role in the diagnosis and treatment of dento-skeletal malocclusions.
In borderline cases in which orthodontic-surgical treatment is planned, the patient's aesthetic requirements often prevail over dental and skeletal assessments which are not always sufficient to clearly discriminate between a surgical case and an orthodontic case; in fact, in spite of their diagnostic relevance, cephalometric parameters are not sufficient to make this clear-cut distinction unless major abnormalities are found (Arnett 1999, Bell 1986).
Establishing a treatment strategy for these alterations of the dentomaxillofacial complex requires the evaluation of numerous variables such as the characteristics and the severity of the malocclusion as well as patient's age and the treatment’s aesthetic and psychosocial implications (Bailey 2008, Bell, 1986).

Age of the patient – Orthodontic treatment is most successful in cases with Class II malocclusions since it can stimulate condylar growth and correct sagittal skeletal discrepancy using orthopaedic-functional procedures which are most effective during mandibular growth peak. According to some authors, however, correction of skeletal problems could also be possible at an older age (Proffit, 2010, Ruf 1998, Tucker 1995).
In Class III malocclusions orthopaedic correction seems to be more complex especially in the presence of inherited syndromes. The prognosis of these malocclusions is guarded and may be aggravated by a concurrent basic malocclusion (sagittal dimension), unfavourable facial type (vertical dimension) or skeletal asymmetry (transverse dimension). In the presence of evident alterations in the three dimensions, combined orthodontic-surgical treatment may be advisable.

Aesthetics and psychosocial issues - Facial aesthetics is connected with the patient's motivations and expectations. Self-esteem, understood as the value of one's own image in interpersonal relationships, as well as personality and marginalization or difficulty of integration in the family, school and social groups must drive treatment planning (Bell 1985).
Patient expectations must be carefully evaluated while planning treatment to minimise the risk of failure. In this regard, particular care must be placed in using video images in the planning of orthodontic-surgical treatment, which, by simulating therapeutic results, would enhance the perception of aesthetic change with the risk of creating unrealistic expectations in the patient and imposing on the clinician an implicit obligation to faithfully reproduce the results illustrated by video images.

The orthodontist and the specialist who will perform orthognathic surgery must evaluate the documentation collected for diagnostic purposes. The latter must explain the resulting movements of the jaws and, if possible, their entity, and the type of surgery planned for that patient. The VTO software is a useful tool to predict the results of surgery but should not be considered essential or binding. The information provided by the surgeon to the orthodontist is a necessary premise to draft the orthodontic-surgical VTO (Visualization of Treatment Objectives) (Bell 1981, Bell 1986).

An Orthodontic-surgical VTO plays a valuable role for orthodontists by offering a visual representation of the surgical and orthodontic objectives on the sagittal, transverse and vertical planes.

It can be performed with the technique the dentist is most familiar with, either manually or with the help of digital tools, starting from purely aesthetic or aesthetic-functional considerations; it can be shown to the patient but must not give rise to unrealistic expectations.

Orthodontic-presurgical treatment can be performed with any orthodontic technique. At the end of this phase, a few months before the operation, a labial multi-bracket appliance must be placed for intraoperative purposes; Full-thickness passive rectangular arch-wires and hooks will allow the surgeon to apply steel ligatures intra-operatively (Jacobs 1983, Raberin 2001).

Before moving on to surgery, surgical VTO (managed by the surgeon who will perform orthognathic surgery and shared with the orthodontist) will be used to plan the surgical movements of the jaws and predict the final aesthetic outcome. This VTO is similar to the orthodontic-presurgical one but does not include dental movements. It can be performed in the lateral and front projections, manually or with digital/computer-based tools (Proffit, 2010).

In more complex cases pre-surgical stone casts can be mounted on the articulator at average setting values and then sectioned and repositioned on the articulator base according to the movements predicted by the VTO. Upon request by the surgeon intermediate and/or final resin splints can be prepared to ensure intra- and post-operative stability.

Usually, about two weeks after surgery, when the orthodontist again manages the patient, the full-thickness rectangular arch wires can be removed and replaced with lighter arch wires (Jacobs 1983).

Guidance provided by vertical elastics contributes to improving intercuspation.

At the same time, functional rehabilitation exercises are prescribed.

Usually, approx. 50-60 days after surgery, procedures to improve dental alignment and occlusal relationships can be started and continued over a period of about 4-6 months.

Outcome will be stabilised using bonded retainers (e.g. metal wire or composite splints) or removable retainers (e.g. plates, vacuumed-formed retainers, etc.). Their period of use may vary. On average it is 12-18 months but in some cases they may be needed permanently.

Patients with TMJ disorders require an ad-hoc approach that may include the use of full-arch bite planes.

The successful treatment of "borderline" clinical cases is certainly one of main challenges for orthodontists, as special skills are needed.

The difference between cases requiring orthodontic treatment and those requiring surgery is not always very clear-cut. For this reason a correct diagnosis of malocclusion in the three dimensions is mandatory in order to establish if the dento-skeletal deformity can be treated orthodontically, with dental compensations (camouflage) or by a surgical-orthodontic approach to achieve three-dimensional jaw repositioning. The objectives of pre-surgical orthodontics are conceptually different from those of conventional orthodontic treatment.

Treatment planning must be shared with the patient, as the characteristics and severity of malocclusion are not the only variables influencing treatment choice, while patient's age as well as aesthetic and psychosocial implications are factors of primary importance.

Bibliography

Arnett WG, Bergman RT, Facial keys to orthodontic diagnosis and treatment planning. Part I AJO-DO 1993 Apr: 299-312

Arnett WG, Bergman RT, Facial keys to orthodontic diagnosis and treatment planning. Part II AJO-DO 1993 May:395-411

Arnett GW, Jelic JS, Jone Kim, Cummings DR,Beress A, Worley CM, Bill Chung, Bergman RT. Soft tissue cephalometric analysis: Diagnosis and treatment planning of dentofacial deformity Am J Orthod Dentofacial Orthop. 1999 Sep;116(3):239-53.

Bailey LJ, Phillips C, Proffit WR. Long-term outcome of surgical Class III correction as a function of age at surgery. Am J Orthod Dentofacial Orthop. 2008 Mar;133(3):365-70.

Bell WH, Jacobs JD, Quejada JD. Simultaneus repositioning of the maxilla, mandible and chin. Treatment planning and analysis of soft tissues. Am. J. Orthod Dentofacial Orthop. 1986;89:28-50.

Bell, Kiyak, et Al. Perceptions of facial profile and their influence on the decision to undergo orthognatic surgery. Am J Orthod. 1985 Oct; 4:323-32

Jacobs J., Sinclair P. Principles of orthodontic mechanics surgery cases AJO-DO 1983 Nov:399-407

Kinzinger G, Frye L, Diedrich P. Class II treatment in adults: comparing camouflage orthodontics, dentofacial orthopedics and orthognathic surgery - a cephalometric study to evaluate various therapeutic effects. J Orofac Orthop. 2009;70:63-91.

Profitt W.R. , et Al. Surgical versus orthodontic correction of Class II malocclusion in adolescents: effects and indications. Int J Adult Orthod. Ortognath. Surg. 1992; 7(4): 209-20

Proffit WR, Phillips C, Turvey TA. Long-term stability of adolescent versus adult surgery for treatment of mandibular deficiency. Int J Oral Maxillofac Surg. 2010 Apr;39(4):327-32.

Raberin M. Orthodontic implications in the correction of the transverse dimension in orthognathic surgery. Rev Stomatol Chir Maxillofac. 2001;102:325-33.

Ruf S, Pancherz H. Long.term TMJ effects of Herbst treatment: a clinical and MRI study. Am. J. Orthod Dentofacial Orthop.1998;114:475-83.
Tucker M.R. Orthognatic surgery versus orthodontic camouflage in the treatment of mandibular deficiency. J Orla Maxillofacc. Surg. 1995;53:572-78

ORTHODONTICS AND PERIODONTICS

In patient with periodontal problems, orthodontic treatment - from diagnosis to long-term stability - is advisable in conjunction with periodontal treatment aimed at solving specific periodontal problems of individual teeth. This is also the case when treating malocclusions, when there are localised periodontal problems or during an orthodontic treatment of choice.

This treatment approach is frequently required in patients who need orthodontic treatment and present seriously compromised teeth or when perio-ortho problems are present and, in particular, for orthodontic aligning and/or repositioning requested by the periodontist e.g., correction of axial inclination, opening and closing spaces, extrusion and intrusion, stabilisation of teeth with periodontal problems, etc.) (Amato 2012, Kajiyama 1993, Korayem 2008, Melsen 1998, Melsen 1989, Pontoriero 1987).

From a clinical point of view the loss of periodontal support can entail tooth migration, particularly if parafunctions are present, just like tooth loss and/or extraction can cause adjacent teeth to migrate in edentulous areas, thus creating diastemas, proclination, extrusions, rotations, inclinations, etc. As well as causing evident aesthetic damage, these clinical conditions can cause hygienic problems thus exacerbating the inflammatory processes of the periodontium. Furthermore, they can be an obstacle to the necessary restoration procedures aimed at restoring good aesthetics and function.

In-depth clinical examinations and any necessary analyses aim at assessing patients' initial conditions both in terms of general orthodontic problems and end-of-treatment periodontal conditions. When treatment aims at solving specific problems, orthodontists must choose the most appropriate analyses. However, prescribing intra-oral X-rays of the areas to be treated would be good practice. In complex restoration cases, analysis of casts as well as proper assessment through intra-oral X-rays and lateral head films might be appropriate (Proffit 2000).

At the orthodontist's discretion, further analyses can be prescribed on the basis of problems identified by appropriate diagnosis. Analysis of extra- and intra-oral pictures can be useful for diagnostic purposes and to check the final treatment outcome.

An overall orthodontic and periodontal assessment in order to schedule the various treatment phases and steps is of fundamental importance.

As far as general treatment strategies are concerned, orthodontic treatment can only start once periodontal tissues are no longer inflamed. Furthermore, careful monitoring of patients' oral hygiene throughout the entire orthodontic treatment is necessary (Boyd 1982, Boyd 1989).

The areas where plaque builds up must be carefully assessed, as plaque accumulation could exacerbate periodontal disease. Occlusal traumas due to dental movements or premature contacts should be avoided. To this end, smaller and easy to clean appliances that apply light and well-controlled forces are recommended (Forsberg 1991).

Patients are advised to go to their dental hygienists regularly depending on how well they manage to maintain a good level of oral hygiene. According to some Authors, patient's inability to maintain proper oral hygiene would be a valid reason to discontinue treatment (Machen 1990).

Once treatment objectives have been reached, especially in patients with severe loss of periodontal support associated with previous tooth migration), permanent retention could be advisable by applying fixed retainers on the treated teeth (Dahl 1991).

Orthodontic treatment in patients with healthy but reduced periodontal tissues can be started without exacerbating the initial periodontal conditions, if movements are made after careful diagnosis and by adopting an effective therapeutic protocol (Artun 1988).

When treatment is appropriately performed, there should not be significant attachment loss. In some cases, orthodontic treatment could even improve the periodontal conditions, particularly when performed in conjunction with specific periodontal treatments (Diedrich 2003).

Good results depend on the procedures being used and, in particular, on the use of light forces, good oral hygiene, inflammation control and elimination of any functional interferences (Boyd 1989).

Conversely, in periodontal patients and when there is an occlusal trauma, orthodontic movement can accelerate periodontal degenerative disease, even when patients are able to maintain good oral hygiene (Kessler 1986).

However, these are always complex treatments whose outcome is dependent on individual factors that can be a limitation for the orthodontist when choosing the biomechanical approach (force systems, anchorage), and assessing periodontal risk (morphology of the alveolar bone). It can also be a limitation for the course and prognosis of periodontal diseases and can lead to patients' inability to maintain good oral hygiene.

It is therefore necessary that patients are made aware of these risks before starting treatment and can ensure full compliance.

Combined orthodontic and periodontal treatments, although more frequent in adult patients, can however be necessary in growing patients, particularly when periodontal tissues are thin or when there

are dental traumas (e.g., incorrect brushing technique, anterior cross-bites, ectopic eruptions, etc.) (Baker 1976, Carmen 2000, Pini Prato 2000).

In these cases, the orthodontist will not only follow diagnostic and therapeutic procedures typical of a conventional treatment but will also have to adopt a focused strategy to prevent exacerbation and, if possible, to improve pre-existing periodontal conditions (Wennstrom 1996).

Before using fixed appliance, treating inflamed periodontal tissues and checking patients' oral hygiene is recommended. Careful monitoring of patients' oral hygiene throughout treatment is also advisable (Boyd 1992, Boyd 1989).

Patients' oral hygiene at home must be supplemented by regular professional oral hygiene in order to maintain good oral hygiene.

When there are periodontal problems, periodontal diseases could be exacerbated by plaque build-up and occlusal traumas, also due to dental movements or premature contacts (Ericsson 1978, Ericsson 1977, Kessler 1976).

When there is reduced but healthy periodontal tissue, orthodontic treatment can be undertaken without exacerbating initial periodontal conditions. Adopting an appropriate biomechanical approach, applying light forces, maintaining good oral hygiene, controlling inflammation and eliminating any occlusal interference are necessary (Artun 1988, Nelson 1997, Re 2000).

Orthodontic treatment is not recommended in patients with active periodontal disease and when there are occlusal traumas, even if oral hygiene is good, as they could cause, worsening of the periodontal degenerative disease.

Patients must be made fully aware of any risk related to orthodontic treatment and the importance of their adequate compliance (Machen 1990).

Bibliography

Amato F., Mirabella D.,Macca U.,Tarnow D.P. Implant site development by orthodontic forced extraction: a preliminary study.Int.J.Oral Maxillofac.Implants 2012;27:411-420

Artun, J.& Urbye, K.S. The effect of orthodontic treatment on periodontal bone support in patients with advanced loss of marginal periodontium. Am J Orthodontics and Dentofacial Orthopedics 1988;93:143-148.

Baker, D.L. & Seymor, G.J. The possible pathogenesis of gingival recession. J Clinical Periodontology 1976;3:208-219.

Boyd, R.L. & Baumrind, S. Periodontal considerations in the use of bonds or bands on molars in adolescents and adults. The Angle Orthodontist 1992;62:117-126

Boyd, R.L., Leggot, P.J., Qinn, R.S., Eakle, W.S. & Chambers, D. Periodontal implications of orthodontic treatment in adults with reduced or normal periodontal tissues versus those of adolescents. Am J Orthodontics and Dentofacial Orthopedics 1989;96:191-199.

Carmen M., Marcella P., Giuseppe G.,Roberto A.Periodontal evaluation in patients undergoing maxillary expansion. J. Craniofac Surg 2000;11:491-4

Dahl, E.H. & Zachrisson, B.U. Long-term experiences with direct-bonded lingual retainers. J Clinical Orthodontics 1991;25:619-630.

Diedrich P., Fritz U., Kinzinger G., Angelakis J. Movement of periodontally infected teeth after guided tissue regeneration-an experimenta lpilot study in animals, J.Orofac Orthop 2003;64:214-27

Ericsson, I., Thilander, B. & Lindhe, J. Periodontal condition after orthodontic tooth movements in the dog. The Angle Orthodontist 1978;48:210-218.

Ericsson, I.,Thilander, B., Lindhe, J. & Okamoto, H. The effect of orthodontic tilting movements on the periodontal tissues of infected and non-infected dentitions in dogs. J Clinical Periodontology 1977;4:78-293.

Forsberg, C.M., Brattstrom V, Malmberg E. & Nord, C.E. Ligature wires and elastomeric rings: Two methods of ligation, and their association with microbial colonization of Streptococcus mutans and lactobacilli. European J Orthodontics 1191;13:416-420.

Kajiyama, K., Murakami, T, & Yokota, S., Gingival reactions after experimentally induced extrusion of the upper incisors in monkeys. Am J Orthodontics and Dentofacial Orthopedics. 1993; 104:36-47.

Kessler, M. Interrelationships between orthodontics and periodontals, Am J Orthodontics 1976;70:154-172.

Korayem, M., Flores-Mir, C., Nassar, U. & Olfert, K. Implant site development by orthodontic extrusion. The Angle Orthodontist 2008; 78:752-760.

Machen, D.E. Periodontal evaluation and updates: don't abdicate your duty to diagnose and supervise. Am J Orthodontics and Dentofacial Orthopedics 1990;98:84-85.

Melsen, B., Agerbaek, N., Erikson, J. & Terp, S. New attachment trough periodontal treatment and orthodontic intrusion. Am J Orthodontics and Dentofacial Orthopedics 1988;94:104-116.

Melsen, B., Agerbaek, N. & Markennstam, G. Intrusion of incisors in adult patients with marginal bone loss. Am J Orthodontics and Dentofacial Orthopedics 1989;96:232-241.

Nelson, P.A. & Årtun, J. Alveolar bone loss of maxillary anterior teeth in adult orthodontic patients. Am J Orthodontics and Dentofacial Orthopedics 1997;111:328-334.

Pini Prato G., Baccetti T., Magnani C., Agudio G., Cortellini P., Mucogengival interceptive surgery of buccally erupted premolars in patients scheduled for orthodontic treatment. A 7-year longitudinal study. J. Periodontol 2000:71:172-81

Pontoriero R, Celenza F., Ricci G., Carnevale G. Rapid extrusion with fiber resection; a combined orthodontic-periodontal treatment modality. Int. J. Periodontal Restorative Dent.1987;7:31-43.

Proffit W. Special consideration in comprehensive treatmemt for adults. In: Proffit W.,Field HW,editors.Contemporary Orthodontics 3rd St Louis;Mosby;2000 p.644-74

Re S., Corrente G., Abundo R., Cardaropoli D. Orthodontic treatment in periodontally compromised patients:12-year report.Int J.Periodontals Restorative Dent. 2000;20:31-9

Wennström, J.L. Mucogingival considerations in orthodontic treatment. Seminars in Orthodontics 1996; 2:46-54.

ORTHODONTICS AND BONE ANCHORAGE

Anchorage in orthodontics is one of the most debated topics in the scientific community because of the difficulties in achieving the perfect biomechanical control over each detail of tooth movement. Every force applied to a tooth in order to move it (pull or traction) develop a reaction on the teeth engaged in the appliance (loss of anchorage) that, in many cases, creates unwanted, if not damaging, movements.

The development of endosseous dental implant techniques has led to the introduction of the notion of absolute anchorage in orthodontics. In turn, this has become fundamental in developing new treatment techniques to correct malocclusions (Carano 2005).

The introduction of so-called Temporary Anchorage Devices (TADs) has provided orthodontists with a very important tool to overcome the limitations of traditional anchorage, thus considerably improving the quality of orthodontic treatments, now simpler and more predictable (Cousley 2015).

Mini-screws are the most used TADs. They are very small endosseous implants that are left in situ for a few months (hence the expression 'temporary skeletal anchorage') and are removed when they are no longer needed for treatment purposes. Used as anchorage, these devices enable effective and efficient control over tooth movement by fully neutralising reaction forces. This way unplanned movements, caused by a reaction on those segments that the orthodontist does not want to modify, can be avoided. Thanks to their more reliable anchorage, mini-screws can also speed up orthodontic treatment, therefore making it more effective and more comfortable for the patient (Creekmore 1983).

In adult patients, mini-screws offer more effective support to the orthodontic preparation to Prosthodontics in terms of: i) temporary movements of individual teeth; ii) opening of spaces for missing teeth; and iii) general intrusion and/or alignment, that can usually be obtained in just a few months, often with less cumbersome orthodontic appliances and, therefore, with hardly any discomfort for patients.

A preliminary anatomical assessment of the receiving bone site is required before inserting mini-screws. The bone site must have adequate thickness and its length and diameter must be equal to those of the screws themselves. Careful consideration of the appliance biomechanics is required too.

Sites that are suitable for inserting mini-screws include (D'Alessandri 2014):

- in the maxilla, the area below the nasal spine, palatal roof, alveolar envelope (inter-radicular septa), infrazygomatic crest, and retromolar area;
- in the mandible, alveolar envelope, retromolar area, mandibular ramus and symphysis.

Other suitable sites to insert mini-screws are the edentulous areas in both arches.

According to the operative protocol, loading should immediately follow the insertion of mini-screws, particularly if bone quality is not optimum. Applying a light force, in fact, stabilises mini-screws that would otherwise have to be subjected to continuous micro-movements, one possible reason for failure of this technique (Deguchi 2003).

Thanks to mini-screws, controlled sagittal and vertical movements can be obtained in all teeth, both individually and collectively, such as intrusion, extrusion, mesialisation and distalisation. Mini-screws are, in fact, reliable points of anchorage for the biomechanical management of any type of orthodontic appliance (Feldman 2006).

Mini-screws are particularly beneficial in treating the most complex clinical cases such as:

• asymmetries
• periodontal patients
• pre-prosthetic orthodontic cases
• deep bite
• uprighting inclined molars
• correcting over-eruptions
• edentulism
• mesialisation and distalisation of molars and premolars
• orthopaedic distraction of the mid-palatal suture.

Main problems when using mini-screws can be as follows (Goodracre 1997, Justens 2008, Hong 2016):

- Mini-screw fracture;
- Inflammatory reaction around the mini-screws;
- Early loosening of the mini-screws;
- Damage to the periodontium if mini-screws come accidentally into contact with the roots;
- Damage to the anatomical structures near the area where the mini-screws have been inserted (vascular and nervous structures, maxillary sinus).

Osseointegrated implants, extensively used in prosthetic dentistry because they replace extracted teeth, congenitally missing teeth and/or traumatic avulsions of teeth, can be used as anchorage during orthodontic treatment. Unlike mini-screws that, because of their temporary nature do not provide osseointegration, prosthetic implants are osseointegrated and offer absolute orthodontic anchorage (Huang 2005, Kadioglu 2008, Kuroda 2007).

Other osseointegrated devices or devices using TADs, such as anchorage plates that are positioned far from roots, can be used as orthodontic anchorage systems.

Osseointegrated prosthetic implants offer an excellent absolute orthodontic anchorage that is useful in controlling tooth movement during treatment (Liou 2008, Maino 2012).

As temporary anchorage devices, mini-screws are especially useful in controlling all tooth movements (Maino 2016, Maino 2007).

Before inserting mini-screws as anchorage, careful analysis of the anatomy of the insertion site, screw size and biomechanics of the device is advisable because mini-screws are fundamental for detailed treatment planning (Papageorgiou 2012, Rose 2006).

Patients and parents of younger patients must be appropriately informed on the benefits offered by these devices in orthodontic treatments; at the same time, any problem they could be facing should be outlined as well.

Bibliography

Carano A, Velo S, Leone P, Siciliani G, Clinical applications of mini screw anchorage system Journal of Clinical Orthodontics 2005; 1: 9-24

CousleyRJ, Sandler PJ Advances in orthodontic anchorage with the use of mini-implant tecniques British Dental Journal 2015; 218, E4

Creekmore TD, Eklund MK. The possibility of skeletal anchorage Journal of Clinical Orthodontics 1983; 17:266

Dalessandri D, Salgarello S, Dalessandri M, Lazzaroni E, Piancino MG, Paganelli C, Maiorana C, Santoro F, Determinants for success rates of temporary anchorage devices in orthodontics: a meta-analysis European J of Orthodontics 2014; 36: 303–313

Deguchi T, Takamo–Yamamoto T, Kanomi R,Hartsfield JK jr, Roberts WE, Garetto LP. The use of small titanium screws fororthodontic anchorage. J Dent Res 2003 82:377.

Feldmann I, Bondemark L. Orthodontic anchorage: a systematic review.Angle Orthod. 2006; 76:493–501.

Goodracre, Brown DT, Roberts WE, Jeiroudi T. Prosthodontic considerations when using implants for orthodontic anchorage. Journal of Prosth. Dent. 1997; 77(2) .

Justens E, De Bruyn H. Clinical outcome of mini-screws used as orthodontic anchorage. Clin Implant Relat Res.2008;10:174-80.

Hong SB, Kusnotob B, Kima EJ, BeGoleb EA, Hwang HS, Lim HJ, Prognostic factors associated with the success rates of posterior orthodontic miniscrew implants: A subgroup meta-analysis Korean Journal of Orthodontics 2016; 46: 111-126

Huang LH, Shotwell JL, Wang HL. Dental implant for orthodontic anchorage Am J Orthod Dentofacial Orthop 2005;127:713-22

Kadioglu Büyükyilmaz T, Zachrisson BU, Maino BG Contact damage to root surfaces of premolars touching mini-screws during orthodontic treatment Am J Orthod Dentofacial Orthop 2008;134:353-60

Kuroda S, Sugawara Y, Deguchi T, Kyung H-M, Takano-Yamamoto T, Clinical use of miniscrew implants as orthodontic anchorage: Success rates and postoperative discomfort American J of Orthodontics and Dentofacial Orthopedics , Volume 131 , Issue 1 , 9 - 15 2007

Liou, E.J.W., Pai B.C.J., Lin J.C.Y. Do mini-screws remain stationary under orthodontic forces? Am J Orthod Dentofacial Orthop 2008; 134:353-60

Maino GB, Pagin P, Di Blasio A, Success of mini-screws used as anchorage for orthodontic treatment: analysis of different factors Progress in Orthodontics 2012; 13: 202–209

Maino GB, Paoletto E, Lombardo L, Siciliani G, A Three-Dimensional Digital Insertion Guide for palatal miniscrew placement Journal of Clinical Orthodontics 2016; 1: 12-22

Maino BG, Weiland F, Attanasi A, Zachrisson BU, Buyukyilmaz T, Root damage and repair after contact with Mini-screws Journal of Clinical Orthodontics 2007 12: 762-766

Papageorgiou SN, Zogakis IP, Papadopoulosc MA, Failure rates and associated risk factors of orthodontic miniscrew implants: A meta-analysis Am J Orthod Dentofacial Orthop 2012;142:577-95

Rose TP, Jivraj S, Chee W, The role of orthodontics in implant dentistry British Dental Journal 2006, 201, 753 - 764

SPECIAL NEEDS DENTISTRY

Special Needs Dentistry deals specifically with the preventative oral health, treatment and rehabilitation of individuals who, albeit only temporarily, may find themselves in particular conditions: people with intellectual or sensory disabilities, people suffering from diseases limiting their mobility or ability to cooperate, and/or those with chronic disabling pathologies, trauma outcomes, genetic diseases, rare diseases, people with frail health, and people with diseases that make dental treatment critical. In dentistry, a "Special Needs Patient" is an individual whose therapeutic procedures require approaches and timescales that differ from routine practice. The purpose of Special Needs Dentistry is to allow this type of patient to be treated, consistent with the clinical picture and their degree of cooperation, in a similar manner to the rest of the population, both in terms of effectiveness and quality. The dental visit of a special needs patient requires an approach and method befitting to the degree of cooperation and autonomy of the patient. Too often a patient is defined as uncooperative, or at risk should they require a specific space, professional qualifications, or team capable of dealing with their condition. Dental treatment and oral health care for persons with disabilities must be provided following the same principles that are exercised for the rest of the population; naturally, it must be taken into account that the complexity of the treatment may be influenced by the severity of the actual disability.

These guidelines consider:

1. Cooperative and autonomous special needs patients;
2. Special needs patients with low levels of cooperation and autonomy;
3. Non-autonomous special needs patients capable of cooperating or with a lack of cooperation;
4. Uncooperative special needs patients.

A patient with a certain frailty and/or disability may, over time, alter their degree of cooperation or autonomy, therefore they should be periodically assessed during check-ups.

The anamnestic data collected during the initial visit should include the essential information to assess the general state of health of the patient, but should also include a series of information to ascertain the degree of the individual's cooperation and autonomy.

During the first visit, it is necessary to assess the degree of the individual's cooperation and autonomy. The patient's clinical documentation, which certifies the state of the patient's oral health and a consequent treatment plan, are useful to facilitate communication between the dentist, the patient, the latter's family, and any other figures involved in the implementation of the patient's prevention and treatment plan. The fundamental premise of any health treatment is consent, freely expressed by the patient and based on information relative to all aspects of the treatment for which consent is sought. The information must also accurately cover any problems that may arise during and after each treatment, as well as highlighting any therapeutic alternatives to the intended treatment. The practitioner must be familiar with the legislation related to cases of limitation of mental capacity

illustrated in the measures of interdiction, incapacitation and in the role of the guardian. These are fundamental requisites in order to correctly identify the person entitled to consent to the treatment.

It is essential, therefore, that the practitioner establishes a preferential channel of communication directly with whosoever is responsible for the individual to receive treatment, if the latter is incapable of making decisions autonomously, in order to streamline all the formal and significant aspects related to the execution of the dental treatment. It may happen that the practitioner has the consent of the family and/or the guardian requesting treatment, but the individual concerned refuses consent, often for reasons of anxiety and/or phobia. In this regard, and contrary to what one may imagine, it must be taken into due consideration that "a patient's consent to health treatment is a fundamental human right, the individual concerned is the sole person capable of giving consent. In the event of potential conflict with the legal guardian, the will of the person concerned is paramount". It is therefore evident, in virtue of the above, that, in the case of an individual over the age of 14, not subject to an interdiction measure and affected by mild or moderate intellectual disability, which does not, however, constitute mental incompetence, the practitioner may not proceed with the treatment, even if deemed necessary and urgent.

In such situations, current legislation does not provide for the Compulsory Medical Treatment (CMT) procedure as this is reserved for psychiatric treatment only; the only way forward is to persuade the patient to undergo dental treatment by giving his or her own consent.

When informed consent cannot be given by the patient, it must be given by their legal guardian. In some cases, however, this is not sufficient: it is also necessary to have the patient's consent.

1. Cooperative and autonomous special needs patients: this definition includes all fragile health conditions. This type of patient does not differ in treatment from any other patient except for the precautions to be taken according to the associated pathologies that constitute the element of increased risk during treatment. The scope and complexity of the pathologies present in medical fragility do not allow for the specific description of each treatment procedure suitable for each single pathology, this should be dealt with by a broader and more appropriate range of operative protocols.

2. Special needs patients with low levels of cooperation and autonomy: in this category we find pathologies that may require specific "psychological management" skills. Treatment includes skills that require specific training of the entire dental team. In some cases it is useful to familiarize the patient with the surroundings prior to the actual treatment, bearing in mind also that the process of growing accustomed to the "new situation" can be very long and require several visits.

3. Non-autonomous special needs patients capable of cooperating or with a lack of cooperation: these are patients who, due to fragile health or mental and/or physical disabilities, have lost the ability, or have never been able to perform correct oral hygiene routines. In some cases, a domiciliary visit may

be the most suitable initial approach, also to provide the practitioner with information on possible situations that may hinder or make the treatment process difficult.

Very often, the standards of oral hygiene and plaque control in these individuals are low due to lack of autonomy and/or ability and/or cooperation. Proper tooth brushing is essential to remove plaque and food deposits, and maintain healthy gums and periodontium.

The technique is less important than the effectiveness achieved in removing plaque, and the support of parents or caregivers in brushing techniques may be necessary for their entire life. The dentist and/or dental hygienist, following the dentist's instructions, are the figures who provide the correct oral hygiene information to be carried out at home, often "customizing" it for the patients. They must listen and understand the difficulties parents or caregivers have in carrying out such oral hygiene. When preparing a treatment plan, it is necessary to take into account the degree of oral hygiene and periodontal health. Poor oral hygiene negatively affects the success of the treatment and the duration of the expected results.

4. Uncooperative special needs patients: Diagnosis in the uncooperative special needs patient presents particular difficulties due to the impossibility of collecting anamnestic data directly. Occasionally the physical examination must be completed under deep sedation or narcosis, both provide the same conditions required to perform the exam. It would appear clear, therefore, that in the vast majority of cases, these patients require a clinical environment with an appropriately equipped surgery and specialized personnel. Uncooperative special needs patients in pain are often unable to express their discomfort in words, they may instead manifest a change in their behaviour through various conditions: loss of appetite, reluctance to perform routine activities, disturbed sleep, irritability, forms of self-harm, etc... It is important, therefore, that the people closest to the special needs individual can detect these changes and quickly alert those responsible for the prevention and treatment of oral diseases.

Collaboration and communication between the patient, family and/or guardian and health practitioners become crucial elements in the preparation of an effective and customized treatment plan. In consideration of the above, particularly with regard to the difficulties that may arise in undertaking a therapeutic course with these patients, great attention must be paid to the prevention of odontostomatological diseases. In special needs patients in need of odontostomatological care, the frequency of professional intervention fundamentally depends on the needs of the individual. Furthermore, the fact that the need to resort to deep sedation or general anaesthesia may influence the frequency of interventions must also be taken into account. When treating people with special needs who require deep sedation or narcosis, it is advisable that preventative treatment such as oral hygiene and sealing of pits and fissures is performed in the same session. In some cases, frequent visits to the care facility can help familiarize the patient with the surroundings and eliminate the need for general

anaesthesia. At any rate, a common path should be shared with the family or with the facility caring for the patient, and a multi- and interdisciplinary approach should be implemented. It is good practice that on termination of the treatment plan, patients follow a care pathway characterized by preventive sessions, also attempting professional hygiene in the clinic, to be performed with manual instruments and/or ultrasound, by a hygienist or a dentist. These sessions should be repeated depending on the general dental situation and the degree of home hygiene achieved. Based on the practitioner's assessment of the special needs patient, it may be appropriate to schedule several checkups during the year. Furthermore, specific food hygiene programmes should be integrated into the prevention and treatment process.

The personal relationship created between the dentist - dental hygienist - patient is very effective for the promotion and education of oral health care. This may be considered appropriate for individuals with mild or moderate intellectual disabilities, and the role of the dental hygienist is useful in the implementation of this preventive strategy. Caregivers responsible for the oral health of special needs individuals must receive adequate support and specific training.

Correct health policies should ensure, for preventative purposes, reasonable access times to the facility, where it is possible to safely perform deep sedation, general anaesthesia and post-op recovery. It is equally important to guarantee facilitated healthcare paths for special needs patients in consideration of the fact that they are not able to independently access the health facilities. The techniques implemented with patients undergoing odontostomatological surgery will be the same as those used with the general population. When patients are under general anaesthesia, it is recommended to perform as many treatments as possible. It is a good rule for surgical interventions to be performed at the end of the session, so as to prevent any bleeding from hindering completion. The use of absorbable thread is recommended for sutures. During dental treatment sessions of various kinds performed under narcosis or deep sedation, surgical treatments must be performed at the end of the session. Where possible, it is recommended to carry out other specialised treatments during the same therapy session. In the case of conservative dental care, techniques that complete therapy in a single session are preferable. In the case of endodontic treatment, the special needs patient requires protocols that allow the completion of the therapy in a single session, including tooth reconstruction. Treatments of a conservative and endodontic nature under narcosis must be completed in the same therapy session. The use of surgical methods must be carefully evaluated on a case-by-case basis. In fact, inadequate plaque control can easily counteract the therapy practiced. In order to maintain optimal oral health, these patients must be part of a periodic check up programme, for plaque removal and/or polishing, with variable and individual frequency depending on the case; in some cases, it is also necessary to programme tartar removal every 2/3 months, both because of the inability to maintain proper oral hygiene at home, and because of the lack

of patient cooperation during the hygiene session. In such cases, the repetition of short-term hygiene sessions makes it possible to perform effective treatments thanks to the reduced accumulation of tartar.
Periodontal interventions should be evaluated on a case-by-case basis, taking due account of the fact that, at the end of the therapy, the patient may not be able to follow a correct and adequate level of oral hygiene at home. Orthodontic treatment in patients with intellectual disabilities is related to the anatomic-functional situation of the oro-facial district, associated with the degree of patient cooperation. In light of the above, it is clear that orthodontic treatment can be carried out with fixed devices where it is possible to maintain adequate oral hygiene either independently, or with assistance. The use of mobile devices has proven difficult. The few successful mobile devices used are those aimed at improving swallowing, phonation and facial mimic musculature: functions of fundamental importance. Check-ups are variable according to the type of orthodontic device, the complexity of the case and patient cooperation: in line with normal orthodontic clinical guidelines.
The motivation of parents/guardians/caregivers plays a fundamental role in orthodontic treatment. Orthodontic treatment in patients with intellectual disabilities is related to the anatomic-functional situation of the oro-facial district, associated with the degree of patient cooperation. The possibility of being able to perform orthodontic treatment must also be assessed on the basis of the ability to maintain good oral hygiene. Prosthetic treatment requires a careful assessment of the effective cooperation of the patient, and the ability to manage prosthetic devices, especially mobile ones. In general terms, the use of fixed prosthetic devices is preferable. In the preparation of the prosthetic rehabilitation plan, the real ability to maintain adequate oral hygiene conditions, and the fact that therapeutic sessions must be as few as possible should be taken into particular consideration. Implant-supported prostheses are an alternative to the use of mobile devices. However, in uncooperative patients, aside from the difficulties of the intervention itself, the diagnostic phase is also problematic, requiring tests such as OPG, CAT, 3D cone beam imaging scans, tomography, which entail obvious complications.
Similarly, taking dental impressions, undoubtedly more complex for normal implant methods, represents an obstacle to achieving a good therapeutic result. Where possible, in uncooperative patients, prosthetic rehabilitation with fixed devices is preferable. Surgical treatment of uncooperative patients requires a careful assessment by the practitioner of the time required, a factor which is often not previously estimated, especially when a thorough initial examination was not possible. Therefore, the treatment plan is often at the practitioner's discretion; this can also lead to a different evaluation of the choices made, with possible legal medical implications. For this reason, in order to avoid possible litigation, a clinical log is of vital importance, as the practitioner can precisely explain the reasons why one course of action was preferred over another, without ever taking anything for granted. Treatment under narcosis becomes critical in the uncooperative patient when it aims to resolve clinical situations

that in themselves, are not serious enough to justify the risks involved, but which, if not resolved, result in a progressive pattern with negative and disabling implications for the affected individual. This case, by way of example, is represented by a totally uncooperative patient with a large build-up of tartar. It is clear that the individual can only be treated under narcosis; and, in any case, equally evident that the use of the operating room, with the risks and costs involved, appears totally disproportionate to the problem presented. However, this problem, if not addressed with this approach, cannot be resolved. On the other hand, failure to solve the problem will result in an evolution that in the medium term can imply tooth loss and further compromise the patient's health. These situations must be carefully assessed in collaboration with careful and accurate anaesthetic consultation in order to choose the most suitable narcotic technique.

ORAL MEDICINE

Oral cavity may be affected by single or multiple lesions which sometimes represent local manifestations of systemic disease. In order to face effectively and efficiently these diseases, a methodological routine in diagnostics should be followed. This methodological routine helps to identify as soon as possible the characteristics of the lesional process.

Each first oral visit must be accompanied by an accurate collection of medical history and by an objective examination of the oral cavity (Baum and Scully 2015).

The following prerequisites are needed to perform a complete medical exam: a proper knowledge of anatomy and clinic of the oral and perioral region, in order to recognize normal structures and their variants; a good technique has to be known to properly perform a physical exam that ensures a systematic exploration of the oral and oropharyngeal mucosa, of the lips, of the perioral and neck skin; it is also important to recognize the basic clinical aspects of oral diseases identifying those that need second level specialist advice (Steele et al. 2015).

Special advice is recommended in case of confirmed, or suspected, malignancy of the oral cavity, and in case of every other diagnostic doubt; on the other hand an advice should be also requested for every injury that doesn't heal within 15-21 days after the removal of the potential cause.

Dentists experienced in Oral Medicine and General Practitioners should be consulted for all patients suspected of systemic diseases (e.g. diabetes) and for patients on chronic therapy for one or more systemic disease.

- In case of single or multiple lesions and in case of oral manifestations of systemic diseases, the dentist should perform a therapy only if able to reach a definitive diagnosis.
- In any case, the dentist without experience in Oral medicine should refer patients to Dental clinics for diagnosis and treatment.

Oral mucosa examination with vital dyes

Toluidine blue is the most used vital dye for helping choosing the site for biopsy to diagnose Potentially Malignant Disorders (Chainani-Wu et al. 2015) .

Toluidine blue 'in vivo' preferably fixes cells in active replication phase (Gandolfo et al. 2006), including atypical epithelial neoplastic cells (Gupta et al. 2007) and those dysplastic (Pallagatti et al. 2013).

Indications	Contraindications
Search for multifocality in already diagnosed Oral squamous cell carcinoma	Known hypersensitivity to any of its ingredients
Use as indicator to obtain single or multiple biopsy specimens	

The most used technique provides a 1% toluidine blue aqueous solution, used by touch or rinses, following "Mashberg technique":

1. Rinse with water for 20 seconds
2. Set the oral cavity by touch or rinses with 1% acetic acid for 1 minute
3. Dry the affected area with a gauze
4. Touch the affected areas with a cotton wool soaked in toluidine blue for 60 seconds (or a rinse for extensive areas)
5. Rinse with 1% acetic acid for 1 minute
6. Detection and documentation of the dyed areas

Toluidine blue technique cannot be considered a substitute for biopsy and histopathology for the diagnosis of malignant and potentially malignant disorders.

Oral mucosa examination with fluorescent techniques

Immunofluorescence devices can be considered as an adjunctive technique for detection and monitoring of potentially malignant disorders (Awan et al. 2015).

These are multi-use manual devices, which can be used for the oral mucosal examination to highlight any changes in tissue auto-fluorescence (Balasubramaniam et al. 2015).

This technology is based on the evidence that exposure of tissues to blue light (400-460 nanometer) stimulates the re-emission of a green-red fluorescence due to fluorophosphors in the tissue, highlighting any structural and/or metabolic changes in the affected area.

In particular, normal cells appear to be bright when stimulated by this light, while loss of fluorescence seems to be related to alterations of the intrinsic distributions of tissue fluorophosphors associated with carcinogenesis.

Normal tissues appear fluorescent green whereas modified tissues appear dark and irregular.

These tools cannot be considered as a substitute for oral biopsy, which remains today the most reliable technique for diagnosis of suspicious lesions; moreover cannot be considered more useful than a

careful examination of mucous membranes by an Oral Medicine doctor or by an Oral pathologist (Messadi et al. 2014; Luo et al. 2016).

Indications	Contraindications
To highlight no clinically observable lesions	Lack of skills to integrate fluorescence results with analysis of clinical features and other instrumental data
As further indicator to biopsy single or multiple areas of the lesion (mapping)	
Follow-up in cancer patients and in patients with potentially malignant disorders	

It is recommended to execute the examination and the photographic documentation in a dark room in order to improve the visibility of tissue autofluorescence (Paderni et al. 2011).
Nowadays there is no definitive scientific evidence about diagnostic reliability of fluorescence spectroscopy.

Oral mucosa examination with chemoluminescence

Chemoluminescence can be considered as an aid for the identification of suspicious lesions together with the clinical examination; however today there is no scientific evidence about its diagnostic reliability. (Awan et al. 2015).
This technique provides a chemoluminescent source which allows to improve the detection of oral lesions, especially those associated with hyperkeratosis, after rinsing the oral cavity with 1% acetic solution (Aceto-White Lesions).
The possibility of false positive and false negative must be taken into account (Rashid and Warnakulasuriya 2015).
Also in this case, oral biopsy and histomorphological examination remain the “golden standard” for diagnosis of suspect lesions.
A recent clinical examination suggests that this technique, used simultaneously with toluidine blue, can reduce the number of false negative (Petruzzi et al. 2014, Kammerer et al. 2015).

Indications	Contraindications
Help to show mucosal lesions and related margins	Known hypersensitivity to any of its ingredients. Lack of skills to integrate the results of chemoluminescence with analysis of clinical characteristics and other instrumental data.

The technique provides the use of chemoluminescent source to carry out a clinical examination of the oral cavity, previously prepared with a 1% acetic acid solution rinse.
The acetic acid dissolves the cytoplasm of cells in aceto-white lesions, varying refractive properties of lesions.
Positive chemoluminescence lesions must be investigated; local risk factors have to be removed, wherever it is possible.
In case of no considerable improvements, after 15 days, it is advisable to perform the biopsy and histomorphological exam.

Collection for culture examination and eventual antibiogram

It is a diagnostic method aimed at identifying bacterial species in the oral cavity by mean of colture and their relative susceptibility to antibiotics.
It is recommended for patients with mucous membranes lesions of the oral cavity, with or without suppuration, and/or suggestive for primary bacterial infections. It has not contraindications.
Oral microbiological test is carried out by means of a swab or a rinse.
In order not to compromise the reliability of the test, the sampling should be postponed for 7 days in case of systemic antibiotic therapy or local antiseptic therapy.

Collection for mycotic culture and eventual antibiogram

It is a diagnostic technique aimed at identification of mycotic species of the oral cavity (generally Candida spp) by cultural exam and their susceptibility to antimycotic agents ((Millsop e Fazel 2016).
It is indicated for patients with (Williams and Lewis 2011):
-referred burning symptomatology of the oral cavity
-presence of mucosal lesions suggestive of primary/secondary mycotic lesions
-congenital/acquired immunodeficiency
-endocrine systemic pathologies (e.g. diabetes mellitus) predisposing to fungal infections

-chronic treatment with antibiotic and cortisone
-removable dental prostheses
-primary or secondary hyposalivation

There is no contraindication.

Oral microbiological collection can be carried out, in relation to the clinical form of suspected mycotic infection, via oral swab (dry, rubbed on the oral lesion), rinse (with 9 ml of sterile physiological solution) or oral tape (double sided adhesive tape placed in contact with the labial surfaces). In order not to compromise the reliability of the test, the collection should be postponed for 7 days in case of systemic/local antimycotic therapy and/or local antiseptic therapy.

First level diagnostic tests

First level diagnostic tests cannot replace biopsy but they can be used to decide whether or not carry out a biopsy. Indeed, their role is to allow to acquire further diagnostic information for epithelial lesions whose characteristics suggest not to neglect the lesions, when intercepted by the dentist. The possibility of combining these techniques with the evaluation of markers that reveal the presence of oral malignancies is still premature in everyday clinical practice (Gonzalez Segura et al. 2015).

A) Cytological examination

Non-invasive and easy to perform methods that do not allow a definitive histomorphological diagnosis, because they do not provide definitive information about normal or pathological tissue architecture.

Traditional exfoliative cytology

It is a minimally invasive diagnostic method aimed at the cytopathological analysis of the cells taken from the mucosal surface.
This technique allows to obtain information about the presence of cells with altered morphology or cellular atypia (dysplastic or neoplastic) at the epithelium level (for example balloon-like cells in herpetic pathology) (Perez-Sayansm et al. 2010).
This technique can be carried out either on clinically undamaged mucosa or on mucosal lesions and it has no contraindications (Maraki et al. 2006).

The collection can be carried out by brushing (toothbrush rotated about 10 times on the area) or scraping (metal spatula rubbed several times on the affected area), either on apparently health mucosa (screening test) or on a lesion (Mulki et al. 2015).

Collected material is then released and fixed with 70% alcohol or with a spray fixative on a glass slide, otherwise cells are dissolved in fixative with the liquid phase/thin layer cytology (10% formalin or methanol/ethanol) for subsequent microscopic analysis.

The presence of specific infectious agents can be assessed by using specific cellular dyeing (hyphae of candida spp., bacteria colonies). (Loss et al. 2011).

It is easy to find a high number of false negative and inadequate samples, by using exfoliative cytology. This can be avoided by using the liquid phase/thin layer technique (Ye et al. 2015).

Cytological exam with "brush technique" (Brush biopsy)

This is a recent, computer guided, transepithelial, cytological procedure, where the presence of cells from the deep layers of the epithelium would be granted (Patton et al. 2008).

This technique cannot be considered as an alternative to traditional biopsy due to the fact that it does not provide information about tissue architecture (Andratschke et al. 2015, da Silva et al. 2015).

The kit provided contains a brush with a circular tuft nylon bristles, a glass slide with a barcode, a fixative, a hard mail container and informative material.

The brush has to be rotated on the lesion for 10 times, without resorting to local anesthesia and having the foresight to reach the basal layer of epithelium. Than the brush is repeatedly swiped on the glass slide, which is then fixed and sent to the laboratory indicated, for computerized processing. The report is then validated by a pathologist.

The report can be positive, negative or inadequate. Brush biopsy must be repeated in case of inadequacy. A high frequency of false negative has been reported (Ye et al. 2015).

This technique is not invasive and easy to use. It doesn't need local anesthesia and sutures but it is considered a method without any definitive evidence of its complete diagnostic reliability.

A recent meta-analysis did not demonstrate a greater diagnostic reliability than other techniques that a digital scan provides (e.g. DNA cytometry)

B) Histologycal exams

Microbiopsy

It is a superficial tissue sampling technique, carried out by the mean of dermatological curette which allows to take small flaps of epithelium dissolving in liquid phase. We can therefore obtain small fragments of epithelium and get information about the presence of dysplastic tissues or cancer according to tissue architecture, not only atypia on individual cells (Pentenero et al. 2014). It is a mini invasive, easy to use and reliable technique, even if in any case this is a first level exam and does not replace the biopsy (Navone et al. 2008).

Microbiopsy is still being studied and needs to be validate in order to better determinate its field of applications.

Biopsy

It is a technique that involves the removal of tissue from a living organism in order to submit the obtained sample to a subsequent examination, which is usually histomorphological, but the sample may also be submitted for immunohystochemical, direct immunofluorescence or molecular biology procedures.

Any oral lesion should be followed clinically, even when asymptomatic, after a thorough medical history and a first differential diagnosis; it should be biopsied if a definitive diagnosis cannot be reached, if within 2-3 weeks it does not heal spontaneously or after the removal of irritants.

Biopsy remains today the most important technique for an accurate diagnosis of lesions of the oral cavity.

Indications	Contraindications
1.Leucoplakia	Patients with impairment of general health;
2.Eritroplakia and mixed forms leuco-erythroplastic	Patient with hypersensitivity or allergy to any of the local anesthetics;
3.Iperkeratosis in the absence of causal factors	Patient with pulsating lesions;
4.Mobile or fixed swelling	Lesions near to complex anatomical sites or ductal sites.

5.Ulcer or inflammatory lesion without apparent cause	
6.Bleeding lesions	
7.Radiolucent or radiopaque intraosseus lesions	

Other techniques are recently available, although the biopsy with the scalpel is the most commonly used.

Once biopsy is needed or appropriate, the dentist will decide if to perform it personally or to send the patient to a reference center (e.g. www.sipmo.it), through referral letter with the description of the lesion; photos are useful too.

However, the dentist should not perform biopsy without an adequate clinical preparation and without an experienced pathologist: for instance the choice of the site in incisional biopsies is decisive and requires experience in order to avoid false negative. False negatives are also due to technical mistakes during the sample processing or reading by the pathologist: therefore a
critical reading and a constant dialogue with the pathologist are necessary.

Incisional biopsy

Incisional biopsy consists in removing a relatively small portion of tissue from a larger mucosal lesion.

It is important that the removed fragment is as more representative as possible of the entire lesion; it is fundamental where the biopsy is performed; the use of aids as vital dyes may be indicated. Multiple incisional biopsies are indicated in case of large lesions or with different clinical features.

Biopsy should be done in the peripheral area of the lesion in order to include healthy tissue; it is important that the depth of the incision exceeds the basement membrane and the fragment is not too small or damaged.

After identifying the site to be biopsied, a local anesthesia is performed without infiltrating the tissue area to be removed, to avoid artifacts.

The incision will include 3mm of healthy area and a lozenge or an oval is made, obtaining a fragment of tissue that exceeds the basement membrane; the fragment is removed and sutures performed when appropriate.

Biopsy can also be performed with a punch (diameter 4-6-8 mm): the punch is rotated several times deepening until it slightly exceeds the basement membrane; the circular fragment obtained is removed using a traditional scalpel or sharp scissors. In general, the fragment should never be traumatized with tweezers to avoid artifacts.

For the latter reason electrosurgery should never be used to perform diagnostic biopsies; it can only be used in "coagulation mode" only after having performed the biopsy itself.

The sample obtained must be placed immediately in fixing solution. The fixing solution must be 10-15 times the volume of the sample. A 10% buffered formalin solution should be used for traditional histomorphological examinations, while a liquid nitrogen solution should be used for immunofluorescence. For incisional biopsies, percentages of appropriateness of the different histomorphological results are reported in the literature compared to the equivalent excisional biopsies / eradications, mainly due to the limits concerning the choice of the site. Hence the need of a careful evaluation of the biopsy site and the choice of the location of the sample (Pentenero et al. 2003, Holmstrup et al. 2007, Chen et al. 2016).

Excisional biopsy

It consists in the complete removal of a neoformation or a lesion, including at least 2-3mm of clinically undamaged healthy tissue (Gupta et al. 2014, Carreras-Torras e Gay-Escoda 2015).

This method, when used in a dental set and under local anesthesia, is indicated for lesions no larger than about 2 cm and not suspected of malignancy.

Otherwise it is advisable to refer the patient to a center of Oral medicine (e.g. www.sipmo.it) or maxillofacial oral surgery.

After local anesthesia (preferably with vasoconstrictor), avoiding to infiltrate the tissue area that will be removed, the mucosa is incised with a scalpel blade to obtain a lozenge or an oval of tissue that includes the entire lesion having the foresight to overcome the basement membrane. Once the lesion has been removed, sutures are performed (if necessary sutures are also made to separate different floors of tissues).

This biopsy can also be performed with a punch if the lesion itself has a diameter smaller than the punch; the circular fragment obtained is then removed by using a traditional scalpel or sharp scissors. The fragment should never be traumatized with tweezers to avoid artefacts; for the same reason should be avoided electrosurgery.

The sample obtained should be placed in 10% buffered formaline.

Bone biopsy

Bone biopsy is an indispensable aid in diagnosis and in surgical-therapeutical planning of bone lesions either radiolucent or radiopaque, although is less frequent than mucosal biopsies.

After an accurate diagnosis and an initial differential diagnosis carried out with the aid of radiographic documentation, the bone biopsy can be incisional, excisional or performed by fine-needle aspiration (FNAB).

It is always desirable that the biopsy sample is significant and includes neighboring healthy tissue. It should be avoided to biopsy necrotic areas.

Indications:

Incisional biopsy	*Excisional biopsy*	*Aspirated needle*
Extensive lesions	Lesions not greater than 2 cm in diameter, easily detachable from the surrounding tissue	Deep lesions radiolucent with fluid content -needle 23-25G (FNAB) for cells -needle 18G(TRU-CUT) for tissue
Lesions with suspicion of malignancy		

This biopsy should be carried out by a specialist or in a reference center.

Depending on whether the intraosseous lesion eroded or not the cortical, after local anesthesia, the mucosa is incised and the bone tissue is removed with manual instruments.

If the cortical is undamaged, it will be necessary to perform an osteotomy with manual or irrigated rotary tools. The biopsy specimen should be placed in formalin and decalcified.

In case of FNAB, the aspiration could be preceded by a perforation of the cortical with larger needles; once the lesion has been reached, several aspirations should be carried out in different areas (August et al. 1999, Kaffenberger et al. 2010).

The TRU-CUT technique needs a 18G needle with spindle guide, to carry out the removal of a larger amount of bone tissue from radiopaque lesions. A normal syringe or a syringe holder can be used.

Bone biopsy is contraindicated in case of extensive inflammatory foci which may alter the histopatological response.

Incisional or excisional biopsy using a Quantum molecular resonance scalpel or soft tissue laser

The above considerations for biopsies, even if executed with different methods, are still valid. (Vescovi et al. 2008, Vescovi et al. 2010, Giovannacci et al. 2015).

In incisional biopsies the use of CO2 lasers is not recommended, due to the possible altered histomorphological reading of the sample because of high temperature increase suffered by the tissues.

Advantages	*Disadvantages*
Good cutting capacity	Minimal tissue changes resulting in generally negligible histopathological artefacts
Coagulative capacity	Risk of bleeding in the absence of suture
Wound healing by second intention without significant cicatricial outcomes	Risk of inflammatory infectious processes in case of extended removal
Easy to use in anatomical areas difficult to suture or to reach with traditional scalpel	
Use in the presence of coagulopathies, allergies to anesthetics	

Biostimulation by laser

The presence of chromophore photoreactors in inflamed tissues allows us to use low intensity lasers to perform a biostimulating action on these tissues; but only once the diagnosis of potentially malignant disorder or carcinoma has been excluded.

The photochemical effects of biostimulation (biomodulation, photobiomodulation) are obtained with energy distribution within a given range (0,001-10 J/cm2) below the threshold capable of obtaining thermic effects, that are instead exploited for the cutting of tissues.

The energy transferred to the chromophores from the laser emissions is able, then, to activate a series of secondary reactions that involve (mainly but not exclusively) the increase of redox activity and of electronic transfer in the respiratory chain at the mitochondrial level, with consequent and considerable increase in ATP production in the cells. Ultimately, there is a greater availability of amino acids and protein synthesis that determines an increase and an acceleration of tissue repair processes, also favoring an analgesic effect (Fahimipour et al. 2011).

This can be a technique of therapeutic aid, to date, without definitive scientific evidence (Cafaro et al. 2010, Chellini et al. 2010, Mizutani et al. 2016).

Intralesional application of medicaments

It is a therapeutic procedure which consists in intralesional injection of drugs for therapeutic or analgesic purpose. Two categories of drugs most commonly used are corticosteroids (Xia et al. 2006, Tilakaratne et al. 2016) and fibrosclerosant agents for medium-small size vascular malformations (Johann et al. 2005, Selim et al. 2007, Buckmiller et al. 2010). For these latter lesions laser therapy is currently very effective beyond surgery.

Its use is advisable only when strictly necessary and only at hospital centers after informed consent; as the intralesional injection can be very painful for the patient, it is always necessary to perform a local anesthesia.

Sialometry

It is a non-invasive salivary collection of saliva that allows to evaluate its qualitative and quantitative characteristics, at basal conditions or after stimulation (Lofgren et al. 2012).

Indications	*Contraindications*
Evaluation of amount of saliva produced to confirm the diagnosis of hyposalivation	None
Evaluation of biomedical parameters (electrolytes, salivary proteins, mediators of inflammation, drugs and hormones) in a diagnostic phase and in the follow up of several diseases (e.g. periodontitis, Sjögren's syndrome)	
Use of drugs	

Either basal saliva (spitting method) or saliva produced under mechanic or acid stimulation (Falcao et al. 2013) can be collected.

Basal saliva is the saliva which is present in the mouth during the time span of 10-15 minutes; then saliva is collected in a special container when it accumulates or when the reflex of swallowing becomes more intense. The patient must refrain from smoking, drinking or eating for 1-2 hours before the procedure.

Normal values are 0,3-0,4ml/min while smaller or equal values to 0,1 ml/min must be considered strongly reduced (Kaplan et al. 2008).

Stimulated saliva is obtained with acid stimulation (lemon drops) or with mechanic stimulation (sugar free chewing gum or paraffin -1gr-). The saliva produced in the first 2 minutes is collected.

Normal values are 1-2 ml/min while smaller or equal values to 0,5 ml/min have to be considered strongly reduced.

Sialoendoscopy

It is a minimally invasive procedure that allows the complete exploration of the ductal system including the main, secondary and tertiary ducts (Nahlieli et al. 2006, Maresh et al. 2011, Cordesmeyer et al. 2016).

This technique is performed in hospitals with an endoscopic column and dedicated equipment.

Indications	*Contraindications*
Removal of calculi in the proximal portion of Steno's and Wharton's ducts	Non-collaborating patients
Screening of the ductal system for residual calculi	Acute sialoadenitis
Dilatation or ductal stenosis	Advanced chronic infections
Elimination of mucosal caps	Calculi >1 cm
Repeated episodes of glandular swelling without apparent cause	Calculi of the distal third of the duct
Intra-ductal neoplasms	Intraparenchymal calculi

Advantages	*Limits*
Reduces needs of further radiologic exams	Too far deep and large calculi
Clinical approach as outpatients	Very fibrous ductal wall
Local anesthesia	Stenosis of the external papilla of Steno and / or Wharton duct
Possibility to diagnose and identify relatively small calculi (calcified or radiolucent calculi), ductal polyps, mucus plugs, stenoses or debris	Acute sialoadenitis
	Difficult advancing of the sialoendoscope

Halitosis

Halitosis can occur at every age, present itself transiently or be persistent; it is provoked by several oral and/or systemic affections (Hughes and McNab 2008); it also determines socio-psychological implications (Campisi et al. 2011).

Correct diagnostic procedures must provide (van den Broek et al. 2008):

- Medical history (lifestyles/voluntary habits, oral, extra-oral and systemic diseases, current or previous);
- Intra-oral objective examination (including a careful periodontal and oro-pharyngeal examination) (De Geest et al. 2016);
- Organoleptic or instrumental evaluation for the qualitative and/or quantitative evaluation of volatile sulphide compounds (VSC).

In most cases, tongue cleaning, periodontal therapies, correct oral hygiene, caries treatment or treatment of oral diseases causing halitosis (candidosis, bad fitting prosthesis, impacted teeth, oral mucosal diseases) and use of antiseptic mouthwashes are the basic therapies for halitosis treatment (Silveira et al. 2016).

Bibliography

Andratschke, M., S. Schmitz, et al. (2015). "Cytological and Immunocytological Monitoring of Oropharyngeal Dysplasia and Squamous Cell Carcinomas." Anticancer Res 35(12): 6517-20.

August, M., W. C. Faquin, et al. (1999). "Fine-needle aspiration biopsy of intraosseous jaw lesions." J Oral Maxillofac Surg 57(11): 1282-6; discussion 1287.

Awan, K., Y. Yang, et al. (2012). "Utility of toluidine blue as a diagnostic adjunct in the detection of potentially malignant disorders of the oral cavity--a clinical and histological assessment." Oral Dis 18(8): 728-33.

Awan, K. H., P. R. Morgan, et al. (2015). "Assessing the accuracy of autofluorescence, chemiluminescence and toluidine blue as diagnostic tools for oral potentially malignant disorders--a clinicopathological evaluation." Clin Oral Investig 19(9): 2267-72.

Balasubramaniam, A. M., R. Sriraman, et al. (2015). "Autofluorescence based diagnostic techniques for oral cancer." J Pharm Bioallied Sci 7(Suppl 2): S374-7.

Baum, B. J. and C. Scully (2015). "Training specialists in oral medicine." Oral Dis 21(6): 681-4.

Buckmiller, L. M., G. T. Richter, et al. (2010). "Diagnosis and management of hemangiomas and vascular malformations of the head and neck." Oral Dis 16(5): 405-18.

Cafaro, A., G. Albanese, et al. (2010). "Effect of low-level laser irradiation on unresponsive oral lichen planus: early preliminary results in 13 patients." Photomed Laser Surg 28 Suppl 2: S99-103.

Campisi, G., A. Musciotto, et al. (2011). "Halitosis: could it be more than mere bad breath?" Intern Emerg Med 6(4): 315-9.

Carreras-Torras, C. and C. Gay-Escoda (2015). "Techniques for early diagnosis of oral squamous cell carcinoma: Systematic review." Med Oral Patol Oral Cir Bucal 20(3): e305-15.

Chainani-Wu, N., E. Madden, et al. (2015). "Toluidine blue aids in detection of dysplasia and carcinoma in suspicious oral lesions." Oral Dis 21(7): 879-85.

Chellini, F., C. Sassoli, et al. (2010). "Low pulse energy Nd:YAG laser irradiation exerts a biostimulative effect on different cells of the oral microenvironment: "an in vitro study"." Lasers Surg Med 42(6): 527-39.

Chen, S., M. Forman, et al. (2016). "The Diagnostic Accuracy of Incisional Biopsy in the Oral Cavity." J Oral Maxillofac Surg 74(5): 959-64.

Cordesmeyer, R., J. Winterhoff, et al. (2016). "Sialoendoscopy as a diagnostic and therapeutic option for obstructive diseases of the large salivary glands-a retrospective analysis." Clin Oral Investig 20(5): 1065-70.

da Silva, A. D., C. F. Lima, et al. (2015). "Immunocytochemistry associated with oral exfoliative cytology: methodological analysis." Anal Quant Cytopathol Histpathol 37(2): 134-8.

De Geest, S., I. Laleman, et al. (2016). "Periodontal diseases as a source of halitosis: a review of the evidence and treatment approaches for dentists and dental hygienists." Periodontol 2000 71(1): 213-27.

Fahimipour, F., M. Nouruzian, et al. (2011). "Effect of low-level laser therapy on experimental wounds of hard palate mucosa in mice." Indian J Exp Biol 49(5): 357-61.

Falcao, D. P., L. M. da Mota, et al. (2013). "Sialometry: aspects of clinical interest." Rev Bras Reumatol 53(6): 525-31.

Francisco, A. L., W. R. Correr, et al. (2014). "Analysis of surgical margins in oral cancer using in situ fluorescence spectroscopy." Oral Oncol 50(6): 593-9.

Gandolfo, S., M. Pentenero, et al. (2006). "Toluidine blue uptake in potentially malignant oral lesions in vivo: clinical and histological assessment." Oral Oncol 42(1): 89-95.

Giovannacci, I., M. Meleti, et al. (2015). "Erratum to: Advantages of new technologies in oral mucosal surgery: an intraoperative comparison among Nd:YAG laser, quantic molecular resonance scalpel, and cold blade." Lasers Med Sci 30(7): 1911.

Gonzalez Segura, I., D. Secchi, et al. (2015). "Exfoliative cytology as a tool for monitoring pre-malignant and malignant lesions based on combined stains and morphometry techniques." J Oral Pathol Med 44(3): 178-84.

Gupta, A., M. Singh, et al. (2007). "Utility of toluidine blue staining and brush biopsy in precancerous and cancerous oral lesions." Acta Cytol 51(5): 788-94.

Gupta, S., J. S. Shah, et al. (2014). "Clinical correlative study on early detection of oral cancer and precancerous lesions by modified oral brush biopsy and cytology followed by histopathology." J Cancer Res Ther 10(2): 232-8.

Holmstrup, P., P. Vedtofte, et al. (2007). "Oral premalignant lesions: is a biopsy reliable?" J Oral Pathol Med 36(5): 262-6.

Hughes, F. J. and R. McNab (2008). "Oral malodour--a review." Arch Oral Biol 53 Suppl 1: S1-7.

Johann, A. C., M. C. Aguiar, et al. (2005). "Sclerotherapy of benign oral vascular lesion with ethanolamine oleate: an open clinical trial with 30 lesions." Oral Surg Oral Med Oral Pathol Oral Radiol Endod 100(5): 579-84.

Kaffenberger, B. H., P. E. Wakely, Jr., et al. (2010). "Local recurrence rate of fine-needle aspiration biopsy in primary high-grade sarcomas." J Surg Oncol 101(7): 618-21.

Kammerer, P. W., R. K. Rahimi-Nedjat, et al. (2015). "A chemiluminescent light system in combination with toluidine blue to assess suspicious oral lesions-clinical evaluation and review of the literature." Clin Oral Investig 19(2): 459-66.

Kaplan, I., L. Zuk-Paz, et al. (2008). "Association between salivary flow rates, oral symptoms, and oral mucosal status." Oral Surg Oral Med Oral Pathol Oral Radiol Endod 106(2): 235-41.

Kaur, M., U. Handa, et al. (2016). "Evaluation of brush cytology and DNA image cytometry for the detection of cancer of the oral cavity." Diagn Cytopathol 44(3): 201-5.

Lofgren, C. D., C. Wickstrom, et al. (2012). "A systematic review of methods to diagnose oral dryness and salivary gland function." BMC Oral Health 12: 29.

Loss, R., R. Sandrin, et al. (2011). "Cytological analysis of the epithelial cells in patients with oral candidiasis." Mycoses 54(4): e130-5.

Luo, X., H. Xu, et al. (2016). "Accuracy of autofluorescence in diagnosing oral squamous cell carcinoma and oral potentially malignant disorders: a comparative study with aero-digestive lesions." Sci Rep 6: 29943.

Maraki, D., S. Yalcinkaya, et al. (2006). "Cytologic and DNA-cytometric examination of oral lesions in lichen planus." J Oral Pathol Med 35(4): 227-32.

Maresh, A., D. I. Kutler, et al. (2011). "Sialoendoscopy in the diagnosis and management of obstructive sialadenitis." Laryngoscope 121(3): 495-500.

Messadi, D. V., F. S. Younai, et al. (2014). "The clinical effectiveness of reflectance optical spectroscopy for the in vivo diagnosis of oral lesions." Int J Oral Sci 6(3): 162-7.

Millsop, J. W. and N. Fazel (2016). "Oral candidiasis." Clin Dermatol 34(4): 487-94.

Mizutani, K., A. Aoki, et al. (2016). "Lasers in minimally invasive periodontal and peri-implant therapy." Periodontol 2000 71(1): 185-212.

Mulki, S., P. Shetty, et al. (2015). "Oral rinse-based cytology and conventional exfoliative cytology: a comparative study." J Cancer Res Ther 11(1): 129-35.

Nahlieli, O., L. H. Nakar, et al. (2006). "Sialoendoscopy: A new approach to salivary gland obstructive pathology." J Am Dent Assoc 137(10): 1394-400.

Navone, R., M. Pentenero, et al. (2008). "Oral potentially malignant lesions: first-level micro-histological diagnosis from tissue fragments sampled in liquid-based diagnostic cytology." J Oral Pathol Med 37(6): 358- 63.

Paderni, C., D. Compilato, et al. (2011). "Direct visualization of oral-cavity tissue fluorescence as novel aid for early oral cancer diagnosis and potentially malignant disorders monitoring." Int J Immunopathol Pharmacol 24(2 Suppl): 121-8.

Pallagatti, S., S. Sheikh, et al. (2013). "Toluidine blue staining as an adjunctive tool for early diagnosis of dysplastic changes in the oral mucosa." J Clin Exp Dent 5(4): e187-91.

Patton, L. L., J. B. Epstein, et al. (2008). "Adjunctive techniques for oral cancer examination and lesion diagnosis: a systematic review of the literature." J Am Dent Assoc 139(7): 896-905; quiz 993-4.

Pentenero, M., M. Carrozzo, et al. (2003). "Oral mucosal dysplastic lesions and early squamous cell carcinomas: underdiagnosis from incisional biopsy." Oral Dis 9(2): 68-72.

Pentenero, M., R. Marino, et al. (2014). "Microbiopsy a novel sampling technique to early detect dysplastic/malignant alterations in oral mucosal lesions: practicability by general dentists." J Oral Pathol Med 43(6): 435-40.

Perez-Sayansm, M., J. M. Somoza-Martin, et al. (2010). "Exfoliative cytology for diagnosing oral cancer." Biotech Histochem 85(3): 177-87.

Petruzzi, M., A. Lucchese, et al. (2014). "Evaluation of autofluorescence and toluidine blue in the differentiation of oral dysplastic and neoplastic lesions from non dysplastic and neoplastic lesions: a cross- sectional study." J Biomed Opt 19(7): 76003.

Rashid, A. and S. Warnakulasuriya (2015). "The use of light-based (optical) detection systems as adjuncts in the detection of oral cancer and oral potentially malignant disorders: a systematic review." J Oral Pathol Med 44(5): 307-28.

Selim, H., A. Selim, et al. (2007). "Use of sclerosing agent in the management of oral and perioral hemangiomas: review and case reports." Med Sci Monit 13(9): CS114-119.

Silveira, J. O., F. O. Costa, et al. (2016). "Effect of non-surgical periodontal treatment by full-mouth disinfection or scaling and root planing per quadrant in halitosis-a randomized controlled clinical trial." Clin Oral Investig.

Steele, J. C., H. J. Clark, et al. (2015). "World Workshop on Oral Medicine VI: an international validation study of clinical competencies for advanced training in oral medicine." Oral Surg Oral Med Oral Pathol Oral Radiol 120(2): 143-51 e7.

Tilakaratne, W. M., R. P. Ekanayaka, et al. (2016). "Intralesional corticosteroids as a treatment for restricted mouth opening in oral submucous fibrosis." Oral Surg Oral Med Oral Pathol Oral Radiol 122(2): 224-31.

van den Broek, A. M., L. Feenstra, et al. (2008). "A review of the current literature on management of halitosis." Oral Dis 14(1): 30-9.

Vescovi, P., L. Corcione, et al. (2010). "Nd:YAG laser versus traditional scalpel. A preliminary histological analysis of specimens from the human oral mucosa." Lasers Med Sci 25(5): 685-91.

Vescovi, P., M. Manfredi, et al. (2008). "Quantic molecular resonance scalpel and its potential applications in oral surgery." Br J Oral Maxillofac Surg 46(5): 355-7.

Williams, D. and M. Lewis (2011). "Pathogenesis and treatment of oral candidosis." J Oral Microbiol 3.

Xia, J., C. Li, et al. (2006). "Short-term clinical evaluation of intralesional triamcinolone acetonide injection for ulcerative oral lichen planus." J Oral Pathol Med 35(6): 327-31.

Ye, X., J. Zhang, et al. (2015). "Meta-analysis of two computer-assisted screening methods for diagnosing oral precancer and cancer." Oral Oncol 51(11): 966-75.

POST-ONCOLOGICAL REHABILITATIVE PROSTHETIC DENTISTRY

Neoplasms of the oro-craniofacial region, with 6% prevalence, are in sixth place among malignant neoplasms. The incidence is greater in males over 50 years old, belonging to less well-off socioeconomic classes (Parkin DM et al., 2005). In recent years an increase in oropharyngeal cancer cases has been observed in young adults in Europe (Warnakulasuriya S, 2009).

Survival at 5 years is 82% for patients with localised disease. In cases where this is extended regionally, it is reduced to 51%, while in cases with distant metastases, survival falls to 27.6% (Thiele et al., 2015, Scott et al., 2005).

Treatment for neoplasms in this area, based on the location of onset, grade and stage can be with surgery, chemotherapy or radiotherapy, or a synchronous or metachronous combination of such interventions (Branchi et al., 2003).

After treatment of the neoplasia, patients treated with these methods show a complex picture of sequelae and comorbidity which affects their quality of life.

In particular, as regards post-surgical sequelae, the morphological and functional alteration of the operated area may be manifest, depending on the site of the onset of the neoplasia and its severity.

Resections of neoplasms of the oro-craniofacial region can produce defects which border the oral cavity, extended to the nasal cavities, the nasopharynx and the oropharynx, extraoral defects, integuments and skin adnexa, up to extensive abnormalities in the jaw and temporomandibular joint, of the nasal pyramid, of the orbitomalar area, to the point of orbital exenteration and of craniofacial resections (table 1) (Garrett, 2008).

Table 1: Residual defects based on the site of tumour onset

1. isolated defects of the face
2. isolated defects of the nasal cavities
3. isolated defects of the nasopharynx
4. Isolated defects of the oropharynx
5. Isolated defects of the oral cavity (including the tongue) and alveolar processes
6. complex defects (different regions involved in the disease and subsequently in resection

The extent of the post-surgical defect is secondary to need for eradication of the disease.

There are two types of the most frequently occurring defects produced by exeresis surgery: intraoral and extraoral or facial.

The most frequent intraoral defects are due to the loss of a portion of the palate. Under these conditions, a communication between the mouth and the nasopharynx or the nasal cavity is created.
The patient cannot speak comprehensibly due to the nasal resonance that the sound acquires and has great difficulty eating, since part of the food and liquids entering the mouth, with loss of palate tissue, escapes through the nose. A severe functional difficulty therefore arises (Matsuy et al., 1995, Said et al., 2016).
When the oncological disease affects the sense organs, in extreme cases, removal of the nose, the eye, the ear or whole portions of the face may be necessary.
This results in a defect of the face that alters the patient's relationship with his or her self-image and objective perception of judgement from individuals who interact with him or her socially in the family, social and professional sphere. The patient is often healed from oncological disease but can suffer deeply and be ashamed of this condition to the point of considering the therapeutic solution to be worse than the disease (Conway et al., 2008, Sidibe et al., 1994, Smolka et al., 2005).

The defects resulting from the surgical treatment of neoplasia of the or-craniofacial region can be corrected surgically with individual prosthetic devices.
The design of such devices is the job of the dentist in possession of adequate training in rehabilitation methods.

Rehabilitative prosthetic treatments should be considered as part of the treatment of neoplasia as they are aimed at the rehabilitation of the postoperative patient, not so much for their influence on biological healing from the pathology, as for the impact they have on the patient's quality of life (Chang et al., 2005).
In fact, they affect the patient's recovery of functions such as swallowing, phonation, social life that largely influence the response to the disease and the restoration of a satisfactory quality of life (Thiele et al., 2015).

After the surgical excision of the neoplasm, rehabilitation is always necessary.

Rehabilitation is possible through the surgical reconstruction of the defect or through the use of maxillofacial prostheses.
The surgical reconstruction possibilities are linked to some relevant factors such as the type of neoplasia (histotype, degree and stage), the patient's status and any comorbidities, the type/extension of the defect, the oncological prognosis and the necessity for pre- or post-surgical chemo-/radiotherapy interventions. Therefore, surgical reconstruction is not always possible for defects from neoplasm resection (Said et al., 2016, Sullivan et al., 2002, Sugar et al., 1994).

Rehabilitation with maxillofacial prostheses, allowing the reconstruction of defects of the hard palate, soft palate, jaw and face, offers the possibility of rapid reconstruction and simplifies the post-surgical rehabilitation process, giving the patient back an acceptable quality of life in a short space of time (Table 2) (Chang et al., 2005, Branchi et al., 1989, Rieger et al., 2009).

Table 2: Purposes of maxillofacial prostheses

1. restore the separation between different compartments of the splanchnocranium (oral cavity , nasal cavity orbital cavities)
2. restore functions such as chewing, swallowing, phonation
3. compensate/reduce facial aesthetic deficits
4. improve the patient's quality of life, re-establishing his or her social attitudes and facilitating the integration of the post-surgical defect.

Rehabilitation of HARD PALATE Defects

The upper jaw can be the site of neoplasia starting from the tissues of the oral cavity, but it can also be involved in neoplastic processes originating from the naso-paranasal cavities and from the skin. Most neoplasms involving the maxilla are squamous cell carcinomas, followed by neoplasms originating from the minor salivary glands.
The surgical resection of the tumour entails continuity defects in the area of the hard palate (table 3). The limits of this resection reflect the need for radical oncology, with variable limits based on histotype, grade and stage of the disease.

The reconstructive possibilities depend on the oncological prognosis, the systemic compensation of the patient and the rehabilitative needs (Spiro et al., 1997).

Table 3: Outcomes of tumour resection

1. alveolectomy
2. palatectomy (partial-total)
3. maxillectomy (partial-total-extended-with orbital exenteration)

Regarding the post-resection defects of neoplasms involving the upper jaw there are different classifications that take into account different criteria (table 4). Likewise, there are various anatomical-clinical conditions that may remain following surgical resection (table 5) (Spiro et al., 1997).

Table 4

Criteria	**Description**
Dental status	Present and absent teeth (in different quadrants)
Oro-antral/nasal communication	Absent or present
Involvement of adjacent structures	Soft palate, lips, cheeks, nose, orbits, zygomatic, pterygoid or none
Craniocaudal extension	Basicranium, orbital level, nasal level, palatal level, alveolar level
Anteroposterior extension	Anteroposterior
Mediolateral extension	Isolated defect, unilateral or bilateral

Table 5: Anatomo-clinical conditions that may result from surgical resection

1. oroantral or oronasal communications
2. reduced masticatory function (from removal of dental elements)
3. rhinolalia
4. dysphagia
5. skeletal asymmetries

Defects around the oral cavity can be readily resolved with the application of an obturator prosthesis, which significantly reduces post-surgical sequelae.

Maxillary obturators also reduce the morphological appearance of the face by supporting the soft tissues (lips, cheeks) and replacing the missing teeth (Tirelli et al., 2010, Razouk et al., 1994, Davidsson et al., 1998, Branchi et al., 1988).

The timing of the rehabilitation of these defects allows the patient to respond more promptly to the pathology.

The objectives of prosthetic rehabilitation of the defects of the maxilla and palate are (Tirelli et al., 2010):

- to restore the separation between the oral cavity and the nasal cavity;
- to recreate the space suitable for lingual motility;
- to restore the lost dentition;
- to restore the profile of the face.

The achievement of these objectives depends on the close collaboration between surgeon, prosthetist and patient.

The surgeon forms a hypothesis of the extent of the surgical demolition trying, where possible, to preserve some anatomical conditions (table 6) that can be of help for satisfactory prosthetic work, all taking into account the needs imposed by surgical exeresis (Beumer et al., 1995, Benoist et al., 1984).

Table 6: Anatomical conditions favouring prosthetic rehabilitation

1. preservation of the anterior portion of the maxilla
2. preservation of the dental elements and of the alveolar process not involved in the pathology and with a favourable prognosis
3. obtaining a keratinised surface of the defect (skin grafts: greater mechanical resistance, reduction of scar adhesions)
4. preservation of the palatal mucosa
5. access to the lateral and cranial region of the defect (increased prosthetic retention)

When optimal retention and stability of the prosthetic obturator can be achieved, swallowing and phonation are re-established in almost all patients (Bourne GK et al., 2015).
Surgical reconstruction of the defect can compromise prosthetic rehabilitation and thereby affect mastication, swallowing and phonation (Seikaly et al., 2003, Urken et al., 1991).

In many cases, the prosthetic rehabilitation of palate defects is preferable to surgical reconstruction methods, as it is fast and straightforward.

It is the size of the defect that informs the rehabilitative choices: small defects of the palate and alveolar processes often lead to surgical indication even if, sometimes, the healing process tends to resolve them. Significant defects of the hard palate lend themselves well to prosthetic rehabilitation (Zlotow, 1995).
"Borderline" situations can be managed with interim prosthetic devices (obturators), while awaiting to solve the prognosis and evaluate patient compliance.
In some cases, to be evaluated from time to time based on quality and quantity of the bone and any planned radiation treatment, the use of osseointegrated implants can help improve the stability of the obturator, even in edentulous patients (Jacobsson et al., 1992).

For the purpose of a more effective rehabilitation defects of the hard palate, the following are necessary:

- **the multidisciplinary assessment of the patient before surgery, so as to "plan" the extension of the resection and evaluate the prosthetic implications;**
- **the preliminary recording of impressions of the upper and lower arch;**
- **the taking of endoral and orthopantomographic radiographs;**
- **the assembly of the articulating models and the construction of a temporary obturator plate (post-surgical);**
- **if treatment times allow it, the provision of dental care deemed strictly necessary;**
- **the explanation to the patient regarding the prosthetic treatment of the defect that will result from the resection of the neoplasm;**
- **the use of remaining dental elements as a retention tool;**
- **the surgeon's attention in creating a surgical defect with retentive characteristics (in the absence of dental elements), in preserving the tuberosity of the jaws, mobility of the lip and competence of the perioral muscles and in removing movable structures protruding into the cavity, such as turbinates;**
- **the preparation of an immediate post-surgical obturator;**
- **the progressive re-adjustment of the immediate post-surgical obturator as a tissue conditioner;**
- **the preparation of a second transitional prosthetic obturator;**
- **the insertion of the definitive prosthesis with the wound healed (3-6 months).**

The rehabilitative treatment with surgical obturator involves the following phases (Huryn et al., 1989, Gullbransen et al. 1995) :

1. Immediate post-surgical obturator phase

Purpose to restore the oral functions in the immediate post-operative period

Indications most patients

Type acrylic resin prosthesis with steel wire hooks and slots for sutures

Functions

- matrix for post surgical dressing
- protection of the skin island
- reduction of overinfection of the oral cavity wound
- allows the patient to speak more effectively in the immediate post-surgical period

- allows the patient to swallow, reducing the need in the post-operative of the naso-gastric tube
- reduction of the psychological impact of a surgical defect

The immediate post-surgical obturator should be checked and adjusted by reviewing the patient every 7 days, in order to detect the morphological changes of the wound during the healing phase.

If the obturator cannot be fitted at the time of surgery, adjustment of the obturator should be carried out in the post-surgical phase.

Family members should be involved in the management of the post-surgical obturator.

2. "Interim" obturator phase

The purpose of this phase is to produce a functional and comfortable prosthesis that accompanies the patient during the wound healing phases. It is possible to compensate for the loss of teeth with the addition of chewing elements to the prosthesis (Rieger et al., 2009).

3. Final obturator phase (3-6 months after surgery)

Purpose to reconstruct the patient's oral functions (phonation, swallowing, oro-nasal separation) and facial aesthetics.

Times 3-4 months after surgery

N.B. Timing can be influenced by prognosis and possible needs for chemo- or radiotherapy

Functions Stable recovery of mastication, phonation and swallowing with perioral tissue support.

Rehabilitation of SOFT PALATE defects

The reconstruction of the soft palate and the velopharynx responds to needs related to phonation and ventilation.

As regards phonation, acquired defects of the soft palate can produce rhinolalia (by increased nasal resonance of the voice), hyponasal voice (by reduced nasal resonance of the voice), mixed nasal resonance, "pharyngeal" resonance.

These effects may be secondary to palatal insufficiency due to inadequate length of the soft palate and incomplete closure of the velopharynx, despite normal motility of palatine structures or palatal incompetence (structures of normal size, but unable to produce an effective closure of the velopharynx)

(Plank et al., 1981, Rieger et al., 2002).
The surgical reconstruction of the soft palate sometimes reduces velopharyngeal motility decreasing, therefore, the possibilities of prosthetic intervention. In selected cases, however, it can produce optimal functional results (Smolka et al., 2005).

Prosthetic difficulties in the management of soft palate defects depend on the mobility of this structure, which cannot simply be "obturated".

Isolated defects of the soft palate are infrequent, presenting more often combined with defects of the hard palate, tonsillar pillars, base of the tongue, oro- and rhinopharynx.
According to some authors, the soft palate is the site of isolated defects only in a low percentage (18% of resections including the soft palate).

Evaluations on the function of the velopharynx as well as the presumed extension of the resection, the surgical reconstructive options and the choice of the prosthetic options must be discussed among the treatment team before the intervention.

The immediate obturator, made before surgery and fitted intraoperatively, is indicated for dentate patients undergoing complete resections of the soft palate. This type of obturator serves as a basis for the post-surgical dressing.

For edentulous patients with partial defects, a delayed post-surgical obturator is more indicated.

The immediate post-surgical obturator should be modelled on the impression of the soft palate; the type and extent of the resection guide the construction of the obturator (Pera et al. 1989).
The residual portion of the soft palate must not be obstructed by a flap. The entry of the residual velopharyngeal musculature could be weakened.
If more than half of the palatine elevating muscles are resected (when the resection crosses the midline), the flap should not be connected to the remaining part of the soft palate. It is better to restore this defect with an obturator. It is usually preferable to construct an overextended obturator (Gullbransen et al., 1995).
The immediate obturator remains in place for 7-10 days post-operatively.
The posterior and lateral extension of the obturator should be modified according to the movements of the head (flexion and rotation) and on the basis of the swallowing (Gullbransen et al., 1995).

The patient should be instructed post-operatively to use the residual velopharyngeal muscles.
The obturator prosthesis should be checked and relined weekly, to adapt it to changes in healing wound.
The delayed post-surgical obturator is indicated in the limited defects of the posterolateral wall of the velopharynx, in which the post-operative oedema masks the extension of the defect in the early stages.
The "interim" obturator must be a transition to the final prosthesis.
Regarding the definitive obturator, the prognosis of the obturator prosthesis of the soft palate depends on the presence and functionality of the residual velopharyngeal muscles, which are fundamental in guiding swallowing and phonation (Rieger et al., 2009).
The obturator is connected to a conventional prosthesis, skeletal or in resin.
The retention of the total dentures to which the obturator is connected can be improved using osseointegrated implants (Roumanas et al., 2002).
The obturator must be rigid and must not completely obstruct the lateral and posterior pharyngeal spaces, which are useful for the execution of nasal ventilation and the pronunciation of the nasal consonants. It should be placed in the nasopharynx at the level of the normal closure of the velopharynx, without exceeding the level of muscular activity and not extend inferiorly to the lower margin of the velopharyngeal musculature present (Roisin et al., 1988).
The posterior extension of the obturator should follow as a continuation of the palatal plane and the oral surface of it should be concave (Branchi et al., 1989).

Rehabilitation of MANDIBULAR and LINGUAL defects

The oral cavity can be the site of malignant neoplasms of different origins that require different surgical interventions for exeresis (table 7) and can lead to significant functional consequences (table 8).
The possible involvement of structures such as the jaw, the oral floor and the tongue inform the evaluation of the post-surgical functional implications and their possible prosthetic correction during the planning of the exeresis of the tumour (Branchi et al., 2004, Curtis et al., 1999, Larbaoui-Boumendjel S et al., 1987, Marunick et al., 1992).

The general state of the patient, the histotype, the grade and the stage of the neoplastic lesion influence the surgical approach, the reconstruction possibilities and the prognosis of the patient.

Table 7

1. alveolectomy
2. segmental mandibulectomy
3. hemimandibulectomy
4. total mandibulectomy
5. partial or total glossectomy
6. glosso-pelvectomy

Table 8

1. Reduced masticatory (for removal of teeth and overall capacity reduction) and phonatory function (lingual hypomobility)
2. Mandibular lateral deviation
3. Clenching
4. Lingual and / or dental dyslalia
5. Dysphagia
6. Alteration of mandible-maxillary relationship
7. TMJ disorders
8. Alteration in the integrity of dento-periodontal structures

In mandibular and tongue defects, pre-surgical prosthetic evaluation highlights the possibilities for rehabilitation.

The needs and the possibilities for prosthetic rehabilitation can be explained during discussion with the patient and the relatives.

Before the intervention, the photographic and radiographic documentation must be collected (periapical

radiographs and orthopantomography), impressions of both the arches must be taken and the plaster models must be mounted on the articulator.

A study of mandibular kinematics and lingual motility should also be performed pre-intervention (Curtis et al., 1975).

The possibilities of prosthetic rehabilitation are largely affected by the effectiveness of surgical reconstruction of the continuity of the jaw and lips and of the lingual volume and motility (Divaris et al., 1993).

In particular, the reconstitution of an adequate lingual volume has a positive effect on the recovery of the phonatory function and on swallowing.

The reconstruction of the mandibular bone volume allows most anatomical conditions to be recreated similar to pre-operative status. Therefore, it is possible to provide prosthetic rehabilitation according to the patient's needs.

The indication for radiotherapy treatment, after the surgical treatment, requires cautious evaluation of the indication for the use of endosseous implants (Fueki K et al., 2007).

The placement of implants in the osseous portion of the microsurgical flap is already possible at the time of mandibular reconstruction (Jackson et al., 2016).

It is, however, preferable to proceed with the insertion of the endosseous implants 6-12 months after microsurgical reconstruction, due to reasons related to the oncological prognosis and to the maturation of the soft tissues of the flap (Jackson et al., 2016).

The insertion of the implants in the reconstructed jaw should be applied through the management and possible augmentation of soft tissues for adequate volume and consistency. Where the grafted skin is too thick, the surgeon should be asked to reduce its thickness at the intervention site (Jackson et al., 2016).

When applying any masticatory load, mediated by a fixed or removable prosthesis, stability of the bone healing of the proximal and distal ends of the residual mandible must be verified. Removable prostheses should be avoided during the wound healing phases, unless there are real needs to support of the cheeks and the lip, always avoiding the decubitus on the soft tissues of the flap (Ruhin et al., 2006).

The "surgical modifications" in cancer therapy, however, respond to the laws of mandibular kinematics that in a cancer patient become unique in relation to the type of demolition and reconstruction. In fact, these morphological changes often affect masticatory capacity (loss of dental elements, disruption of vascular, tendon and muscular structures and altered proprioceptive masticatory sensitivity).

It is fundamental to restore some anatomical peculiarities (although not always possible) so that the oral functions are similar to the pre-surgical ones – peculiarities such as mandibular continuity, the relationship between the volume of the lingual muscle, particularly of the posterior third, and the

palatal surface and volume, and the labial containment function upon completion (Jackson et al., 2016).
The reduction of lingual motility reduces capacity to control the bolus and makes it difficult to maintain hygiene at home.
Mandibular integrity and continuity greatly influence masticatory competence, swallowing and phonation. The preservation of mandibular symmetry guarantees the maintenance of these functions (Marunick et al., 1992).
The resection of part of the jaw reduces symmetry and balancing of the jaw. Joint load, the range of mandibular movement and the angle and duration of occlusal contacts are altered (Branchi et al., 2004).
The residual mandible deviates to the side of resection. We also witness the postero-rotation and mandibular retrusion. The protrusion and incision movements become particularly difficult (HElkimo et al., 1977).
Despite the possible functional changes of the mandibular movements depending on different factors (psychological, related to the extension of the resection, radiotherapy and the type of reconstruction), mandibular continuity affects the masticatory function independently.
The restoration of mandibular continuity allows a stable occlusal plane to be reconstructed, allowing the number of occlusal contacts to be increased, which increases the masticatory efficiency. The posterior occlusal contacts improve the masticatory efficacy in patients undergoing mandibular resection (Branchi et al., 2004).

In cases of mandibular resection, mandibular continuity must be restored first, followed by masticatory function.

The masticatory function can be restored with removable prostheses, whose stability and tolerability can be be improved with the fitting of osseointegrated implants (Roumanas et al., 2002).
The effectiveness of osseointegrated implants in improving the masticatory function compared to the use of removable prostheses is still debated (Roumanas et al., 2002).
In the choice of treatment, the patient's oncological prognosis must always be considered.
The involvement of the tongue in the destruction of the neoplasia affects the masticatory efficacy, when volume, motility and sensitivity of the tongue itself are compromised.
Surgical resection also entails the onset of dysphagia that risks compromising the body's response to the disease as it weakens the patient.
Therefore, the surgical reconstitution of lingual volume and mandibular continuity benefit the patient in this sense.

Since the oral component of phonation is influenced by the morphology and function of the tongue, cheeks, lips, alveolar processes and teeth, restoring these structures in terms of form and function is the key to restoring normal phonation.

Auxiliary devices for phonation and swallowing can be used. In their preparation, volume and motility of the tongue, the presence of teeth, the limitation of mandibular movement and motility of lips and cheeks must be carefully evaluated (Roumanas et al., 2002, Branchi et al., 2004).

The construction of palatal devices is recommended, rather than prostheses with a mandibular support.

The resection of the neoplasm and mandibular discontinuity produce asymmetries and mandibular lateral drift, often associated with clenching.

The option of using devices to guide the mandibular kinematics should be considered, in order to reduce lateral deviation resulting from the disorganisation of the anatomy resulting from resection and reconstruction (Branchi et al., 2004).

Mandibular repositioning devices should be used as soon as possible after surgery.

The use of these devices in conjunction with physiotherapy and passive mobilisation exercises is recommended (Marunick et al., 1992).

The effectiveness of these measures is directly proportional to their timing, given that the earlier the beginning of the repositioning therapy, the fewer the consequences related to contractures, fibrosis and adhesions that manifest.

The presence of teeth improves the prognosis of this type of dysfunction.

Once the volume of the soft tissues is restored and with it, their function and the most functional maxillo-mandibular ratios are recovered, it is possible to proceed to the most indicated occlusal rehabilitation.

Rehabilitation of FACIAL defects

The face can be the site of manifestation of different types of malignant neoplasia (cutaneous, orbit, oral cavity, nasal/paranasal sinus neoplasms and composite forms) as well as the site of extrinsecation of surgical resection manoeuvres of neoplasia starting from adjacent regions (Markt et al., 2001, Thiele et al., 2015).

The surgical removal of such neoplasms results in defects that may involve different anatomical components that participate in the constitution of the face (Table 9).

Table 9: Facial defects that can be treated with maxillofacial epitheses

Defects of the auricle
Defects of the nose
Defects of the orbito-zygomatic region, with or without orbital exenteration
Defects of perioral tissues (lips)
Complex (mixed) defects

Several factors influence the possibilities for rehabilitation: the size of the defect, its location, the aetiology, the general prognosis and the patient's expectations and requests.

Plastic surgery is not always able to restore facial features following the destruction of a malignant neoplasm.

Multiple interventions hindered by significant comorbidities are often necessary and prognosis not always certain.

Technical difficulties in restoring the morphology of the face depend on the numerous musculoskeletal structures that participate in the constitution of the volumes of the face. Such volumes are not always restorable, even with the most complex surgical techniques available. Hence the need to use prosthetic restorations to restore facial defects that reduce the number of surgical procedures, especially in older patients. In this way comorbidity associated with multiple surgeries and subsequent to chemo- and radiotherapy is limited. The clinical follow-up is also facilitated in consideration of the fact that the margins of the resection are kept examinable (Markt et al., 2001, Thiele et al., 2015, Beumer et al., 1995, Ciocca et al., 2010 , Ciocca et al., 2007, Ciocca et al., 2010, Federspil et al., 2015).

The implementation of an effective facial epithesis, independent of the anatomical site involved, requires standardised procedures.

Preliminary steps to the construction of the facial epithesis must be (Federspil et al., 2015):

- discussion with the treatment team (surgeon, radiotherapist, oncologist) for the technical planning and timing of the prosthetic reconstruction;

- discussion with the patient, with the aim of illustrating the therapeutic alternatives and making the same informed about the risks and benefits of each contemplable solution;
- involvement of the patient's family members, in order to improve the suitability of the patient to adoptable rehabilitation solutions;
- collection of instrumental data prior to surgical resection (radiographic and photographic images);
- taking of impressions of the parts of the face probably affected by subsequent resection, if not altered in the morphology of the pathology.

In the phases following the surgical intervention (Thiele et al., 2015):

- monitoring of the resection margins, for the management of the rehabilitation timing, especially in the presence of post-treatment radiation sequelae;
- taking of impressions of the facial defects under favourable conditions for construction and retention/stability of epithesis;

  It is appropriate to obtain as many defects as possible without adherent and/or cicatricial outcomes, which can displace mobile tissues. The epithesis must be supported by a base of skin tissue, without, if possible, hair follicles;
- taking of the impressions of the contralateral face regions at the surgical resection site;
- insertion, where clinically and anatomically possible, of endosseous implants that facilitate retention and stability of the epithesis.

Operational timing:

- intraoperative assessment of the size of the defect (possible fitting of endosseous implants);
- protective patch and wound dressing for 4-6 weeks after surgery;
- temporary epithesis to be performed no earlier than 4-6 weeks after surgery;
- evaluation of any post-radiotherapy sequelae;
- close follow-up for 4-6 months before performing the definitive epithesis;
- periodic follow-up after the implementation of the definitive epithesis, with possible relining/modifications and shade corrections; bi-quarterly follow-up in case of presence of endosseous implants.

The endosseous implants are of great help in the rehabilitation of large defects since they allow the epitheses to stabilise better. Their increased retention allows the reduction of thicknesses, improving the mimicry of the skin of the face and reducing the skin ulcerations from decubitus (Jackson et al., 2016).

All this improves the patient's acceptance, facilitates its use and prolongs the average duration of the prosthesis.

Even in patients with uncertain oncological prognosis, who have extensive defects in facial anatomy, maxillofacial prosthesis can be an aid to improve quality of life, with possible positive repercussions on the general prognosis of the patient.

For the rehabilitation of all facial defects the use of advanced technologies such as CAD-CAM that provide standardised clinical protocols is possible (Table 10) (Ciocca et al., 2010, Ciocca et al., 2007, Ciocca et al., 2004).

Table 10: Protocol for the application of CAD-CAM technology

monitoring of the resection margins, for the management of the timing of rehabilitation, especially in the presence of post-therapy radiation sequelae;
Laser scanning of the patient's entire face
Production of a temporary adhesive epithesis or supported by glasses (nasal and oculofacial epitheses) through rapid prototyping of the muffle mould obtained from the design of the prosthesis on the first preliminary impression
CAD-CAM processing of surgical guide templates for the positioning of the craniofacial implants according to the final volumes to be restored
Execution of diagnostic CAT scan to verify selected implant sites
Surgical implant phase for the fitting of craniofacial implants or oral implants of length and diameter adapted to the available bone
Detection of fixtures with placement of transcutaneous abutments (4 months after implant insertion)
Virtual impression of the mutual positions of the implants and development of the retention bar for the epithesis.
Connection of the bar and definitive laser impression
Virtual design (CAD) of the external volume of the epithesis and of the mesostructure of retention for the connection to the bar
Development of the muffle for the moulding of the facial epithesis and the mesostructure of retention.

Bibliography

Beumer J III, Roumanas E, Nishimura R. Facial defects: alteration at surgery to enjance the prostetic prognosis. In: Zlotolow In, Esposito S, Beumer J III (eds). Proceedings of the first international congress on maxillofacial prosthetics. New York, Memorial Sloan Kettering Cancer Center 1995:104-107.

Benoist M, Dichamp J, Poulain G. Esthetic problems in prosthetic restoration of the face in relation to the surrounding structures. Actual Odontostomatol (Paris). 1984 Dec;38(148):619-30.

Bourne GK, Barber AJ, Wilson PH. Cast Titanium for Obturator Framework Construction in Maxillofacial Prosthodontics. Eur J Prosthodont Restor Dent. 2015 Dec;23(4):213-8.

Branchi R, Fancelli V, Giovannoni A, De Salvador A. Prosthetic management of neuromuscular rehabilitation in hemimandibulectomy patients. A case report. Minerva Stomatol. 2004 May;53(5):295-304.

Branchi R, Fancelli V, De Salvador A, Giovannoni A. Cancer of the head and neck: general principles of radiobiology, radiotherapy and chemotherapy. Radiation damage. Minerva Stomatol. 2003 Oct;52(10):411-9, 420-5.

Branchi R, Pagni L, Bernardini UD. Prosthetic rehabilitation of a young patient after surgical-radiation treatment. Stomatol Mediterr. 1989 Apr-Jun;9(2):137-40.

Branchi R, Bernardini UD. New technic for fabrication of obturators. Stomatol Mediterr. 1988 Jul-Sep;8(3):257-60.

Chang TL, Garrett N, Roumanas E, Beumer J III Treatment satisfaction with facial prosthesis. J Prosthet Dent 2005;94:275-280.

Ciocca L, Fantini M, De Crescenzio F, Persiani F, Scotti R. New protocol for construction of eyeglasses-supported provisional nasal prosthesis using CAD/CAM techniques. J Rehabil Res Dev. 2010;47(7):595-604.

Ciocca L, De Crescenzio F, Fantini M, Scotti R. Rehabilitation of the nose using CAD/CAM and rapid prototyping technology after ablative surgery of squamous cell carcinoma: a pilot clinical report. Int J Oral Maxillofac Implants. 2010 Jul-Aug;25(4):808-12.

Ciocca L, Fantini M, Marchetti C, Scotti R, Monaco C. Immediate facial rehabilitation in cancer patients using CAD- CAM and rapid prototyping technology: a pilot study. Support Care Cancer. 2010 Jun;18(6):723-8.

Ciocca L, Mingucci R, Gassino G, Scotti R. CAD/CAM ear model and virtual construction of the mold. J Prosthet Dent. 2007 Nov;98(5):339-43.

Ciocca L, Gassino G, Scotti R. Home care maintenance protocol for ear prostheses. Minerva Stomatol. 2004 Oct;53(10):611-7.

Conway DI, Petticrew M, Marlborough H, Berthiller J, Mia Hashibe M, Macpherson LMD. Socioeconomic inequalities and oral cancer risk: A systematic review and meta-analysis of case-control studies. International Journal of Cancer 2008;122(12):2811–9.

Curtis DA, Plesh O, Hannam AG, Sharma A, Curtis TA. Modelling of jaw biomechanics in the reconstructed mandibulectomy patients. J Prosthet Dent 1999;81:167-173.

Curtis TA, Taylor RC, Rositano SA. Physical problem in obtaining records of the maxillofacial patients. J Prosthet Dent 1975;34:539-554.

Davidsson SP, Sherris DA, MEland NB. An algorithm for maxillectomy defects reconstruction. Laryngoscope 1998;108:215-219.

Divaris M, Aubert S, Favre-Dauvergne E, Rosenstiel M, Dichamp J, Vaillant JM. Complex reconstruction of the lower lip. Apropos of various cases. Rev Stomatol Chir Maxillofac. 1993;94(5):305-11.

Federspil PA. The Role of Auricular Prostheses (Epitheses) in Ear Reconstruction.

Facial Plast Surg. 2015 Dec;31(6):626-32. doi: 10.1055/s-0035-1568137. Epub 2015 Dec 14.

Freedman ND, Abnet CC, Leitzmann MF, Hollenbeck AR, Schatzkin A. Prospective investigation of the cigarette smoking-head and neck cancer association by sex. Cancer 2007;110(7):1593–601.

Fueki K, Kimoto K, Ogawa T et al. Effect of implant-supported or retained dentures on masticatory performance. A systematic review. J Prosthet Dent 2007;98:470-477.

Garrett N. Outcomes of maxillectomies with conventional and implants restorations. Pesented at the international congress of maxillofacial rehabilitation, Bangkok, Thailand, 2008.

Gullbransen H. Immediate surgical obturators. In:Zlotolow I, Esposito S, Beumer J (eds). Proceedings of the first international congress on maxillofacial prosthesis. New York , MSKCC 1995:144-151.

Helkimo E, Carlsson Ge, Helkimo M Bite force and state of dentition. Acta odontol Scand 1977;35:297-303.

Huryn J, Piro J. The maxillary immediate surgical obturator prosthesis. J Prosthet Dent 1989;1:343-347.

Jackson RS, Price DL, Arce K, Moore EJ. Evaluation of Clinical Outcomes of Osseointegrated Dental Implantation of Fibula Free Flaps for Mandibular Reconstruction. *JAMA Facial Plast Surg. 2016 May 1;18(3):201-6. doi: 10.1001/jamafacial.2015.2271.*

Jacobsson M, Tjellstrom A, Fine L, Andersson HA. A retrospective study of osseointegrated skin penetrating titanium fixture used for retaining facial prostheses. Int J Oral Maxillofac Implants 1992;7:523-528.

Larbaoui-Boumendjel S, Dichamp J, Princ G, Guilbert F, Vaillant JM. Reconstruction following anterior sulco-mandibulectomy. The advantages and disadvantages of different procedures. Apropos of 85 cases. Rev Stomatol Chir Maxillofac. 1987;88(4):240-2.

Markt JC, Lemon JC. Extraoral maxillofacial prosthetic rehabilitationat the M.D. Anderson Cancer Center. A survey of patient attitudes and opinion. J Prosthet Dent 2001;85:608-613.

Marunick M, Mathes BE, Klein BB et al. Occlusal force after partial mandibular resection. J Prosthet Dent 1992;67:835-838.

Matsui Y, Ohno K, Shirota T, Imai S, Yamashita Y. Michi K. Speech function following maxillectomy reconstructed by rectus abdominis myocutaneous flap. J Craniomaxillofac Surg 1995; 23:160-164.

Parkin DM, Bray F, Ferlay J, Pisani P. Global cancer statistics, 2002. CA: A Cancer Journal for Clinicians 2005; 55(2):74–108.

Pera P, Schierano G, Previgliano V, Preti G. Impression method in patients with maxillo-facial loss with reduction of the degree of oral opening. Minerva Stomatol. 1989 Aug;38(8):883-6.

Plank D, weinberg B, Chalian V. Evaluation of speech following prosthetic obturation of surgical aquired maxillary defects. J Prosthet Dent 1981;45:626-638.

Razouk O, Sidibe CA, Dichamp J, Bertrand JC. An obturator prosthesis in a patient with perfect dentition. Functional, esthetic approach. Rev Stomatol Chir Maxillofac. 1994;95(2):195-6.

Rieger J, Wolfaardt J, Seikalj HJ, Jha N. Speech outcomes in patients rehabilitated with maxillary obturator prosthesis after maxillectomy: a prospective study. Int J Proshod 2002;15:139-144.

Rieger J, Bohle III G, Huryn J et al. Surgical reconstruction versus prostetic obturation of extensive soft palate defects. A comparison of speech outcomes. Int J Prosthod 2009;22:566-572.

Roisin LC, Dichamp J, Dubruille JH. Final prosthetic treatment of facial clefts: classification and role of fixed and removable technics. Actual Odontostomatol (Paris). 1988 Jun;(162):379-88.

Roumanas ED, Freymiller EG, Chang TL, Aghaloo T, Beumer J. Implant retained prostheses for facial defects: an up to 14 year follow-up report on survival rates of implants at ucla. Int J Prosthet 2002;15:325-332.

Ruhin B, Menard P, Ceccaldi J, Dichamp J, Bertrand JC. Double-barrel fibular free flap for mandibular reconstruction: beneficial alternative for dental implanted rehabilitation (5 cases). Rev Stomatol Chir Maxillofac. 2006.

Said MM, Otomaru T, Sumita Y, Leung KC, Khan Z, Taniguchi H. Systematic review of literature: functional outcomes of implant-prosthetic treatment in patients with surgical resection for oral cavity tumors. *J Investig Clin Dent. 2016 Jan 8. doi: 10.1111/jicd.12207. [Epub ahead of print] Review.*

Seikaly H, Rieger J, Wolfaardt J et al. Functional outcomes after primary oropharingeal cancer resection and recontruction with the adial forearm free flap. Laryngoscope 2003;113:897-904.

Scott SE, Grunfeld EA, Mc Gurk M The idiosyncratic relationship between diagnostic delay and stage of oral squamous cell carcinoma. Oral Oncology 2005, 41;396-403.

Smolka W, Iizuka T. Surgical reconstruction of maxilla and midface. Clinical outcomes and factor relating to postoperative complications. J Craniomaxillofac Surg 2005;33;1-7.

Sidibe CA, Dichamp J, Razouk O, Bertrand JC, Guilbert G. Statistical study of mandibular resections. Rev Stomatol Chir Maxillofac. 1994;95(2):113-4.

Spiro RH, Strong EW, Shah JP. Maxillectomy and its classification. Head and Neck 1997;19:309-314.

Sullivan M, Gaebler C, Beukelman D et al. Impact of palatal prosthodontic intervention on communication performance of patients' maxillectomy defects. A multilevel outcome study. Head Neck 2002;24:530-538.

Sugar A, Beumer J. Reconstuctive prosthetic methods for facial defects Oral Maxillofac Surg Clini North Am 1994;6:755-764.

Thiele OC, Brom J, Dunsche A et al. The current state of facial prosthetics – A multicenter analysis. J Craniomaxillofac Surg. 2015 Sep;43(7):1038-41. doi: 10.1016/j.jcms.2015.04.024. Epub 2015 May 15.

Tirelli G, Rizzo R, Biasotto M, Di Lenarda R, Argenti B, Gatto A, Bullo F. Obturator prostheses following palatal resection: clinical cases. Acta Otorhinolaryngol Ital. 2010 Feb;30(1):33-9.

Urken MI, Buchbinder D, Weinberg H et al. Functional evaluation following microvascular oromandibular reconstruction of the oral cancer patients. A comparative study of reconstructed and non-reconstructed patients.Laryngoscope 1991;101:935-950.

Warnakulasuriya S. Global epidemiology of oral and oropharyngeal cancer. Oral Oncology 2009;45(4-5):309–16. Zarb GA The maxillary resection and its prosthetic replacement. J Prosthet Dent 1967;18:268-281.

Zlotolow I. Reconstruction of the acquired soft palate deformity with surgical resection and reconstruction. In: Proceedings of the first international congress on maxillofacial prosthetics. New York, Memorial Sloan Kettering Cancer Center 1995:49-55.

DIGITAL TECHNOLOGY IN PROSTHETIC DENTISTRY

The rapid progress in information technology, innovative materials of last generation (zirconia, lithium disilicate, reinforced polymers, etc.) and new technologies for realization of restorations (Computer-Aided Design, CAD and Computer-Aided Manufacturing, CAM, laser sintering , 3D printers, etc.) opened new horizons and in the past not conceivable in the field of prosthetic dentistry (Schoenbaum 2012).

The new laboratory procedures are increasingly replacing the traditional workflow (conventional impression, plaster model and "lost wax" castings) with products processed by numerical control systems, to achieve high accuracy and reproducibility along with significant resources savings (Dawood et al 2010, Fasbinder 2010).

The large-scale introduction of CAD / CAM technology has allowed, by means of computer aided design and computer-assisted production, the creation of restorations in materials highly aesthetic and mechanically performing, both stratified and monolithic (Koch, Gallucci & Lee 2016; Joda et al., 2014), moving technical processes in a virtual environment; recently has been introduced the possibility of completely eliminating the plaster / resin models by the use of intra-oral scanners.

Today the clinician has at his disposal a series of operations that allow mixed, analogue-digital or fully digital paths (Miyazaki & Hotta 2011), even though mixed workflow prevails in everyday dentistry, combining the aspects of the two techniques considered most convenient (Weston 2016, Kapos & Evans 2014, Patel 2010).

The scientific literature is highly polarized on the digital workflow (DDWF) in prosthodontics, although clinical in-vitro and clinical "case-series" studies only analyze the comparison between single operative steps, as in the case of the intra-oral scannerss compared with the traditional impression (Joda & Bragger 2015, Schepke et al., 2015, Yuzbasioglu et al., 2014, Gherlone et al., 2015, Joda et al., 2016).

There is a lack of evidence based data on the comparison between the entirely digital path and the classical prosthetic path, in terms of long-term clinical success. Furthermore, given the extreme rapidity of scientific progress in this field, we are faced with systems, materials and technologies that are renewed at very narrow intervals of time, which deeply conditions the difficulty of evaluating the medium-long term efficiency.

The short-term data available through the few RCT studies, together with the clinical experience gained in the last ten years in clinical practice (Batisse et al., 2014, Batson et al., 2014, Reich & Schierz 2013, Grohmann et al. 2015, Naenni et al 2015, Selz et al., 2015) confirm, in any case, that digital systematics represent a very important aid in prosthetics, whose future developments will probably lead to their ever greater implementation in daily operative procedures.

Bibliography

Batisse C, Bessadet M, Decerle N, Veyrune JL, Nicolas E. Ceramo-metal crown or CAD/CAM rehabilitation: Patient and practitioner appraisal. Eur J Prosthodont Restor Dent. 2014;22(4):159-65.

Batson ER, Cooper LF, Duqum I, Mendonca G. Clinical outcomes of three different crown systems with CAD/CAM technology. J Prosthet Dent. 2014;112(4):770-7.

Dawood A, Purkayastha S, Patel S, MacKillop F, Tanner S. Microtechnologies in implant and restorative dentistry: a stroll through a digital dental landscape. Proc Inst Mech Eng H. 2010;224(6):789-796.

Fasbinder DJ. Digital dentistry: innovation for restorative treatment. Comp Cont Educ Dent. 2010;31 Spec No 4:2-11; quiz 2.

Gherlone EF, Ferrini F, Crespi R, Gastaldi G, Capparé P. Digital impressions for fabrication of definitive "all-on-four" restorations. Implant Dent. 2015 Feb;24(1):125-9.

Joda T, Bragger U. Patient-centered outcomes comparing digital and conventional implant impression procedures: a randomized crossover trial. Clin Oral Implants Res. 2015 [Epub ahead of print].

Joda T, Ferrari M, Gallucci G, Wittneben JG, Braegger U. Digital technology in fixed implant prosthodontics. Periodontol 2000. 2016 [Epub ahead of print].

Kapos T, Evans CA. CAD/CAM technology for implant abutments, crowns and superstructures. Int J Oral Maxillofac Implants. 2014 [Epub ahead of print].

Koch GK, Gallucci GO, Lee SJ. Accuracy in the digital workflow: From data acquisition to the digitally milled cast. J Prosth Dent. 2016 [Epub ahead of print].

Miyazaki T, Hotta Y. CAD/CAM systems available for the fabrication of crown and bridge restorations. Austr Dent J. 2011;56 Suppl 1:97-106.

Patel N. Integrating three-dimensional digital technologies for comprehensive implant dentistry. J Am Dent Assoc. 2010;141 Suppl 2:20S-4S.

Schepke U, Meijer HJ, Kerdijk W, Cune MS. Digital versus analog complete-arch impressions for single-unit premolar implant crowns: Operating time and patient preference. J Prosth Dent. 2015;114(3):403-406 e1.

Schoenbaum TR. Dentistry in the digital age: an update. Dent Today. 2012;31(2):108, 10-13 Weston J. Closing the Gap Between Esthetics and Digital Dentistry. Comp Cont Educ Dent. 2016;37(2):84-91.

Yuzbasioglu E, Kurt H, Turunc R, Bilir H. Comparison of digital and conventional impression techniques: evaluation of patients' perception, treatment comfort, effectiveness and clinical outcomes. BMC Oral Health. 2014;14:10.

The advent of CAD CAM technology and digital impression has allowed the realization of a workflow that starts from the oral registration of the anatomical forms to the realization and installation of the prosthesis in the patient's mouth. (Joda T, 2015). However, in relation to the abutment preparation, there are currently no digital technologies capable of replacing the protocols and materials currently in use. Intraoral scanners (IOS) are able to acquire different images of the oral cavity with different technologies and convert them into data that are transformed into files that can be processed with special software (Chochlidakis KM 2016).

Once the impression has been detected, the realization of the prosthesis by means of CAD-CAM technology can be realized wholly or partially with a digital workflow.
Concerning the cementation of the prosthesis there are no current digital technologies able to replace the commonly used protocols and operating materials.

Intra-oral scanner (IOS)

The intra-oral scanners - IOS - (the term used to distinguish them from the other family of scanners, extra-oral or laboratory scanners) are 3D scanners that, through a scanning process, allow to obtain a three-dimensional virtual model starting from a physical object.
The device emits a light - in most cases a structured light or laser beam - that invests the object; thereflection of the lights from the object is acquired and transformed, by means of specific software, in three-dimensional coordinates; these coordinates produce a series of points - point clouds - which are then transformed into triangles (mesh) (Kostiukova VV 2013, Logozzo S 2013).

Software in digital dentistry

The 3D computer graphics is is based on the elaboration of a set of three-dimensional models through algorithms, to produce a photographic and optical likelihood in the final image. In dentistry, it is used for the creation and post-production of prostheses and diagnostic devices. There are many software on the market that can process files obtained from intra-oral scanning or laboratory models in order to create virtual products. These virtual products are converted into real through CAM technology (McEvoy 2003).
At present it is good practice with regard to hardware, software and equipment, to use all those is certified and, if possible, consolidated by scientific evidence.

Dental Digital workflow (DDWF)

The digital workflow is the set of phases that lead to the creation of an artifact. It may start from a traditional impression registered with traditional impression materials or from a digital impression recorded with intra oral scanners. The difference is that in the first case the impression is acquired with an extra-oral scanner or transformed into a working model and then " scanned ", while in the second case a file is directly generated. (Van der Meer WJ 2016, Koch GK 2016, Joda T 2015, Solaberrieta E 2013).

The digital workflow can start from:

- digital impression through intra oral scanner;
- traditional impression scanned with extra-oral scanners;
- plaster model scanned with extra-oral scanners.

In all cases, a file is generated that can be processed by a 3D modeling software.
These files can remain in the dental office and allow a "chair side" work process, or they can be sent to the laboratory for the realization of the prosthesis (Bohner LO 2016).
The impression recorded with an intra oral scanner provides for easy shipping (by e-mail); it does not need special disinfection and storage protocols, like analogic impression.

Digital workflows starting from an analogic impression

The traditional impression does not prevent digital procedures, that can start in the laboratory with an extra oral scanners: the impression is poured and transformed in a model that, after a preparation process involving cleaning and shaping, can be scanned by laboratory scanners and transformed into files.
Some scanners and related management software allow the scanning of a negative: therefore, the impression can be scanned without going through the physical model.
Scanning of the impression can take place in the dental office using intra-oral scanners or in the laboratory using extra-oral scanners (Galhano GÁ 2012).

Digital workflows starting from a digital impression

Differently from the traditional impression, the digital impression allows to immediately have the file to be used with management software, without passing through an impression and the acquisition of the model.
The workflow starts from a file that can be recorded either by a positive model (mouth and teeth) or by a negative (small impression or cap).
The file obtained is sent to the planning software and transformed in a physical object. The product can be semi-finished or finished.

The “semi-finished” is a product to be finalized with ceramics or other material; finalization requires a model that can be realized in the dental office or in the laboratory through specific 3D printers (Gherlone E 2014).
There are several technologies for 3D printing and the main differences consist in the way in which the layers are printed. Some methods use materials that melt or soften to produce layers, e.g. selective laser sintering (SLS) and fused deposition modeling (FDM), while others lay liquid materials that harden by different technologies. In the case of lamination systems, thin layers are cut according to the defined shape and joined together.

The semi-finished product reckons on the realization of a working model that can be obtained in two ways: from the analogic impression or from the digital file.
To produce the models from the file there are two techniques: subtractive (milling) and additive by sintering (3D printers) through a process called stereolithography.
This is a technique that allows the creation of single three-dimensional objects starting from a file that is processed by a CAD / CAM software.
Its main application is rapid prototyping, which allows to produce objects and models.
The finished product is a prosthesis precise and with anatomic shape which, if necessary, requires only superfiby means of a milling machines. These are able to produce finished products with different certified materials.
The digital flow can happen in the dental office without proceeding in the laboratory: this is possible thanks to devices, already mentioned, named "chair side" (Fasbinder DJ 2006).
They are formed of a design unit and a production unit: the design unit consists of a hardware and a planning software. The production unit is a small bench miller able to produce single crowns, small prosthetic bridges and inlays.

In consideration of the above:
digital processing must be carried out with the described workflows and these must be adequately supported by scientific evidence;
working models must be used for the finalization of the semi-finished products in order to guarantee the correct adaptation of the prosthesis in the oral cavity;
in the realization of the directly finished prosthesis, the model can be avoided by entrusting the whole productions to the CAD CAM workflow;
to register the impression with intraoral scanners requires an operating field free from agents that can inhibit the good quality of the impression (saliva, blood etc..).

Bibliography

Adams D. Dentures in the Digital Age. Dent Today. 2016 Jun;35(6):10.

Bassett JL, Roberts M, Digital Design: Predictability, Profitability, and Efficiency. Dent Today. 2016 Jan;35(1):122, 124-6.

Baumgarten HS, Wunsche A, CAD/CAM Fabrication of Definitive Implant Prostheses: A Digital Workflow From Planning to Implant Placement to Final Restoration. Compend Contin Educ Dent. 2015 Nov-Dec;36(10):746-55.

Bohner LO, Neto PT, Ahmed AS, Mori M, Laganá DC, Sesma N, CEREC Chairside System to Register and Design the Occlusion in Restorative Dentistry: A Systematic Literature Review. J Esthet Restor Dent. 2016 Jul;28(4):208-20. doi: 10.1111/jerd.12226. Review.

Brawek PK, Wolfart S, Endres L, Kirsten A, Reich S, The clinical accuracy of single crowns exclusively fabricated by digital workflow--the comparison of two systems. Clin Oral Investig. 2013 Dec;17(9):2119-25.

Chochlidakis KM, Papaspyridakos P, Geminiani A, Chen CJ, Feng IJ, Ercoli C. Digital versus conventional impressions for fixed prosthodontics: A systematic review and meta-analysis. J Prosthet Dent. 2016 Aug;116(2):184-190.e12. doi: 10.1016/j.prosdent.2015.12.017. Review.

Fasbinder DJ. Digital dentistry: innovation for restorative treatment. Compend Contin Educ Dent. 2010;31.

Fasbinder DJ. Materials for chairside CAD/CAM restorations. Compend Contin Educ Dent. 2010 Nov-Dec;31(9):702-4, 706, 708-9. Review.

Fasbinder DJ. Clinical performance of chairside CAD/CAM restorations. J Am Dent Assoc. 2006 Sep;137 Suppl:22S- 31S. Review.

Fasbinder DJ. Computerized technology for restorative dentistry. Am J Dent. 2013 Jun;26(3):115-20. Review.

Fasbinder D. Usingdigitaltechnology to enhance restorative dentistry. Compend Contin Educ Dent. 2012 Oct;33(9):666-8, 670, 672.

Galhano GÁ, Pellizzer EP, Mazaro JV. Optical impression systems for CAD-CAM restorations. J Craniofac Surg. 2012 Nov;23(6):e575-9. doi: 10.1097/SCS.0b013e31826b8043. Review.

Gherlone E, Mandelli F, Capparè P, Pantaleo G, Traini T, Ferrini F. A 3 years retrospective study of survival for zirconia-based single crowns fabricated from intraoral digital impressions. J Dent. 2014 Sep;42(9):1151-5.

Gherlone EF, Ferrini F, Crespi R, Gastaldi G, Capparé P., Digital impressions for fabrication of definitive "all-on- four" restorations. Implant Dent. 2015 Feb;24(1):125-9.

Jäger K, Vögtlin C. Digital workflow with the Lava Chairside Oral Scanner C.O.S. and Lava technique. Schweiz Monatsschr Zahnmed. 2012;122(4):307-24. French, German.

Joda T, Brägger U Complete digital workflow for the production of implant-supported single-unit monolithic crowns. .Clin Oral Implants Res. 2014 Nov;25(11):1304-6.

Joda T, Brägger U. Digital vs. conventional implant prosthetic workflows: a cost/time analysis. Clin Oral Implants Res. 2015 Dec;26(12):1430-5.

Joda T, Brägger U. Time-Efficiency Analysis Comparing Digital and Conventional Workflows for Implant Crowns: A Prospective Clinical Crossover Trial. Int J Oral Maxillofac Implants. 2015 Sep-Oct;30(5):1047-53.

Koch GK, Gallucci GO, Lee SJ. Accuracy in the digital workflow: From data acquisition to the digitally milled cast. J Prosthet Dent. 2016 Jun;115(6):749-54.

Kostiukova VV, Riakhovskiĭ AN, Ukhanov MM. Comparative study of intraoral 3D digital scanners for restorative dentistry. Stomatologiia (Mosk). 2014;93(1):53-9. Review. Russian.

Logozzo S, G Franceschini, A Kilpelä, M Caponi, L Governi, L Blois A Comparative Analysis Of Intraoral 3d Digital Scanners For Restorative Dentistry. The Internet Journal of Medical TechnologyVolume 5Number 1 2013.

Rudolph H, Salmen H, Moldan M, Kuhn K, Sichwardt V, Wöstmann B, Luthardt RG. Accuracy of intraoral and extraoral digital data acquisition for dental restorations. J Appl Oral Sci. 2016 Jan-Feb;24(1):85-94.

Qualtrough AJ, Piddock V. Dental CAD/CAM: a millstone or a milestone? Dent Update. 1995 Jun;22(5):200- 4. Review.

McEvoy SP. The impact of medical technology on office workflow. Orthod Craniofac Res. 2003;6 Suppl 1:156-9.

Radi M. Driscollc. Clinical Applications of Digital Dental Technology. Wiley online library ISBN: 978-1-118-65579-5 2015.

Van der Meer WJ, Vissink A, Ren Y. Full 3-dimensional digital workflow for multicomponent dental appliances: A proof of concept. J Am Dent Assoc. 2016 Apr;147(4):288-91.

Santos GC Jr, Santos MJ Jr, Rizkalla AS, Madani DA, El-Mowafy O. Overview of CEREC CAD/CAM chairside system. Gen Dent. 2013 Jan-Feb;61(1):36-40;

Seelbach P, Brueckel C, Wöstmann B. Accuracy of digital and conventional impression techniques and workflow. Clin Oral Investig. 2013 Sep;17(7):1759-64.

Solaberrieta E, Minguez R, Etxaniz O, Barrenetxea L. Improving the digital workflow: direct transfer from patient to virtual articulator. Int J Comput Dent. 2013;16(4):285-92.

Wiersema EJ, Kreulen CM, Creugers NH. The conventional and the digital impression method for single-unit and multi-unit fixed dental prostheses]. Ned Tijdschr Tandheelkd. 2013 Jul-Aug;120(7-8):401-10. Review.

Zandinejad A, Lin WS, Atarodi M, Abdel-Azim T, Metz MJ, Morton D. Digital workflow for virtually designing and milling ceramic lithium disilicate veneers: a clinical report. Oper Dent. 2015 May-Jun;40(3):241-6.

IMPLANT-PROSTHETIC DESIGN

Modern implantology founds its development on the research of materials, implant surfaces that speed up osseointegration and surgical techniques with reduced invasiveness.

This is accompanied by the evolution and improvement of computer technology applied to diagnosis and to surgical and prosthetic phases.

As described in the paper "Clinical recommendations in odontostomatology, ed. 2014 "in implant-supported prosthesis, a careful clinical and technical preliminary examination is recommended, not only from a surgical, but also from a prosthetic point of view.

The collection of the anamnesis, the objective examination, and the radiographic survey associated with the study of diagnostic models are therefore important (Branemark 1985, Engelman 1996, Taylor 2000). (For more details on the planning and surgical aspects of implant therapy refer to the implantology chapter of "Clinical recommendations in odontostomatology, 2014 edition".

When the clinician judge it appropriate, it will also be possible to trust on computer systems for planning and carrying out the case ("computer-guided" procedures). Surgical guides of different types

can be used to facilitate the correct placing of the implants, whose position will be evaluated, as well as on the basis of anatomical conditions, also referring to biomechanical, occlusal and aesthetic requirements (Basten 1996, Clinical recommendations in odontostomatology ed. 2014).

Along with classical diagnostic-therapeutic protocols - that is, based on analogical instruments, two-dimensional radiographic images and realization of “model based” restorations, there are nowadays new methods that exploit the latest 3D radio-diagnostic technologies (Cone beam computed tomography - CBCT) and programs for the CAD-CAM fabrication of prosthetic elements.

The clinician can, at present, use advanced pre-operative analysis programs for three-dimensional diagnosis. The meticulous and realistic visualization of the anatomical 3D segment simplifies the surgical procedures by guaranteeing the necessary information to program the intervention, reducing the risks and the invasiveness, even with a "flapless" procedure.

Hand in hand with the evolution in the diagnostic field, in recent times we have benefit of a huge development of softwares for the CAD fabrication of the implant-supported prosthesis.

Through the progress in digital imaging techniques, today, DICOM tomographic data and prosthetic design projects in STL format can be compared using the same software: a new era has emerged, in which the design of implants and prosthesis can occur in the same software, in which the data acquired from different sources are merged and compared in a single file (Frisardi G et al 2011, Ganz SD et al., 2008).

This "matching" procedure has fundamental operative implications for the clinician:

1. the use of radiological templates facilitates the transfer of the prosthetic layout within the software implant planning;
2. the planning of the surgery is not limited to the volumetric analysis of the residual bone, but holds account also of the prosthetic components for the load of the implants;
3. it is possible to model, with CAD-CAM technology, a precise surgical template, supported by teeth or mucosa, for the insertion of implants with flapless technique, according to the virtual project;
4. it is possible to realize, by milling or 3D printing, the prosthetic elements designed in the pre-surgical phase, already connected to the implant components (Meloni et al 2013, Lewis et al. 2015);
5. reduction of surgery and prosthetics time with the "immediate load", because the prosthesis can be realized starting from the files made during implant planning (Testori T al al. 2014, Wercruyssen M et al., 2015).

It is therefore evident that this innovative method of interaction between different technologies, in continuous and constant evolution, guarantees the operator an increasingly reduces margin of error, thanks to the greater and more detailed number of information contributing to the real success of the projects carried out in the digital environment (Schneider D et al 2009, Valente F et al., 2009, Van Assche N 2010).

PRE-IMPLANT RADIODIAGNOSTICS

The design of the implant-supported prosthetic rehabilitative intervention follows a standardized procedure. Clinical semeiotics and instrumental investigations are essential to formulate a treatment plan that meets the needs of the patient and offers a sufficient prognosis when compared with other prosthetic solutions.

The instrumental investigation in implantology involves the use of two-dimensional basic radiographic examinations such as endoral rx and orthopantomography.

The preoperative radiographic survey is essential for a good implant placement and has the main purpose of determining the residual bone volume, the health of the peri-implant anatomical structures and the study of the teeth adjacent to the edentulous saddle.

When the anatomical area intended for implant insertion is not sufficiently intelligible by the two-dimensional study, or the level of bone resorption highlighted by the clinical examination appears consistent in the vestibular-lingual direction, the diagnostic exams have to be implemented.

Tomographic scans obtained with spiral CT or volumetric CT scans represent the elective diagnostic investigation to formulate a correct implant plannig. The main advantage of the CT examination is represented by the possibility to visualize the "cross" or parasagittal images that highlight the lingual-vestibular or palatal-vestibular thickness of the bone segment. Compared to the spiral CT the new Cone Beam cone beam (CBCT) devices drastically reduce the ionizing radiation doses and also the equipment are of reduced size and cost compared to the TAC (Ludlow JB et al., 2008).

Programs for FOV reduction (Field Of View) make CBTC even more versatile, further reducing the ionizing dose for the patient. The image quality of the bone component is generally good.

For all the above, the CBCT examination can today be considered the elective instrument for the implant pre-surgical radiodiagnostic survey (Brown AA et al., 2009; Loubele M et al., 2008). However, the use of the tomographic examination in dentistry must take into account the fact that the patient's exposure to ionizing radiation must be the minimum necessary to acquire the necessary diagnostic information, in compliance with the ALARA principle (As Low As Reasonably Achievable) and that the patient may be exposed to ionizing radiation in the absence of other alternative diagnostic methods, only if the diagnostic and therapeutic benefits outweigh the potential damage.

DIGITAL IMPLANTS PLANNING

The original images, generated by the X-ray device, are processed by a specific software that makes them viewable in order to be able to examine them both at the 2D and 3D levels.

The native axial image processing software is not limited to visualizing coronal and sagittal sections, but calculates three-dimensional multiplanar reconstructions (3D). Recently, specific programs of radiodiagnostics have arrived at even more refined image processing, including advanced reconstructions using "volume rendering" techniques. The continuous evolution of the dedicated programs allows today the virtual implant positioning and the transfer of its position in vivo through a surgical guide. There are numerous virtual implant planning programs on the market, containing the libraries of numerous implant brand. All are designed with the aim of transferring the location of the designed implants to surgical guides for "guided" surgery. There are"model based" methods for the milling of plaster models on which to build the templates along with procedures entirely digital without any model. The software must in any case be certified by an institution designated by the Ministry of Health as a Class IIA medical device.

The clinical experience gained over many years of practice with these procedures has led to comforting results. The so-called "guided implantology", or "computer assisted", can be successfully used in implant surgery as an alternative method to classical technique for the design and placement of implants. Indeed, numerous studies have shown the accuracy of the technique.

RADIOLOGICAL TEMPLATE AND CREATION OF THE VIRTUAL PROJECT

Computer assisted implantology allows operators to place implants within residual bone, to establish anatomy in detail.

Technological evolution and research have meant that the tests are increasingly precise in radiographic imaging could be associated with digital modeling programs of prosthetic components.

The coupling of DICOM data with the digital prosthetic layout in STL format - matching or optical fusion - allows the clinician to elaborate a detailed implant positioning project according to the prosthetic connection (abutment) and the position of the programmed dental elements. To achieve reliable coupling, the programs contain automatic "best fit" algorithms that superimpose images from both optical and X-ray scans. The software uses a default image matching method: both double scan techniques (double scan) and the use of specific scan markers are credited as valid methods for file overlay.

The model of work generated represents a realistic projection of both the anatomical situation of the patient including the soft parts and the final position of the designed protein components.

It is important to follow the coupling techniques provided by the software in order to avoid the risk of "misfitting" which could compromise the success of the intervention.

SURGICAL TEMPLATE

The information obtained for the positioning of the fixtures with the implant design is transferred to the surgical guide. Also in this phase various techniques have been followed for the construction of the building. The realization of a precise template is now guaranteed by the opportunities offered by the CAD-CAM technology: the different prosthetic design functions, included in the same program, provide the template design and accurately determine the exact positioning of the cannulae for passage of surgical drills. The precision of the templates, both with dental support and with mucosal support is ensured by the fact that their modeling takes place on STL files obtained by scanning and not only by physical models or radiographic images (Van Assche N et al., 2010).

SURGICAL TECHNIQUES

The intervention for implant placement is done with flapless technique and involves the use of a specific dedicated surgical kit provided by the manufacturer. It is advisable to check that the tolerance between the cutter rod and the guide cannula corresponds to the lowest possible value to avoid a malposition of the fixture with respect to the digital design.

The templates with exclusive mucosal support must be firmly fixed by means of intra-osseous fixation pins or with other devices provided by the method used. Compared to a classic "open sky" intervention, we recommend reaming the neo-alveolus at low rpm, so as to reduce overheating of the otherwise unavoidable bone tissue, due to the lack of irrigation that passes through the cylinder during the phase of preparation.

At the end of the intervention it is possible to restore the implants, in the case of immediate loading of the fixtures, using a temporary file printed directly from the project file.

Bibliography

Basten C, Kois J. The use of barium sulfate for implant templates. Journal Prosthet Dent 1996; 76:451-454.

Brown AA, Scarfe WC, Scheetz JP, Silveira AM, Farman AG. Linear accuracy of cone beam CT derived 3D images. Angle Orthod. 2009 Jan;79(1):150-7.

Brånemark PI, Zarb GA, Albrektsson T. Tissue-Integrated Prosthesis. Chicago, Quintessence Publishing Co, 1985.16. Engelman MJ. Clinical decision making and treatment planning in ossointegration. Quintessence Books, Chicago, 1996.

Frisardi G, Chessa G, Barone S, Paoli A, Razionale A, Frisardi F. Integration of 3D anatomical data obtained by CT imaging and 3D optical scanning for computer aided implant surgery. BMC Med Imaging. 2011 Feb 21;11:5 .

Ganz SD. Computer aided desing/computer aided manufacturing applications using CT and Cone Beam scannig technology. Dent Clin Nordh Am. 2008 Oct;52(4):777-888.

Lewis RC, Harris BT, Sarno R, Morton D, Llop DR, Lin WS. Maxillary and mandibular immediately loaded implant-supported interim complete fixed dental prostheses on immediately placed dental implants with a digital approach: A clinical report. J Prosthet Dent. 2015 Sep;114(3):315-22.

Loubele M, Van Assche N, Carpentier K, Maes F, Jacobs R, van Steenberghe D, Suetens P. Comparative localized linear accuracy of small-field cone-beam CT and multislice CT fore alveolar bone measurements. Oral Surg Oral Med Oral Pathol Oral Radiol Endod. 2008 Apr;105(4):512-8.

Ludlow JB, Ivanovic M. Comparative dosimetry of dental CBCT devices and 64-slice CT for oral and maxillofacial radiology. Oral Surg Oral Med Oral Pathol Oral Radiol Endod. 2008 Jul;106(1):106-14.

Schneider D, Marquardt P, Zwahlen M, Jung RE A systematic review on the accuracy and the clinical outcome of computer-guided template-based implant dentistry. Clin Oral Res. 2009 Sept;20 Suppl 4:73-86

Taylor TD, Agar JR, Vogiatzi T. Implant prosthodontics: Current perspective and future directions. Int J Oral Maxillofac Implants 2000;15(1):66-75.

Testori T, Robiony M, Parenti A, Luongo G, Rosenfeld AL, Ganz SD, Mandelaris GA, Del Fabbro M, Evaluation of accuracy and precision of a new guided surgery system: a multicenter clinical study. Int J Periodontics Restorative Dent 2014; 34 Suppl 3:s59-69.

Valente F, Schiroli G, Sbrenna A. Accuracy of computer-aided oral implant surgery: a clinical and radiographic study. Int J Oral Maxillofac Implants. 2009 Mar-Apr;24(2):234-42.

Meloni SM, De Riu G, Pisano M, Lolli FM, Deledda A, Campus G, Tullio A . Implant restoration of edentulous jaws with 3D Software planning guided surgery, immediate loading, and CAD-CAM full arch frameworks. Int J Dent. 2013

Van Assche N, Van Steenberghe D, Quirynen M, Jacobs R. Accuracy assessment of computer-assisted flapless implant placement in partial edentulism. J Clin Periodontol.2010 Apr;37(4):398-403.

Van Assche N, Quirynen M. Tollerance within a surgical guide. Tollerance within a surgical guide. Clin Oral Implants Res. 2010 Apr 1;21(4):455-8.

Wercruyssen M, Cox C, Neart I, Jacobs R, Teughels W, Quirynen M. Accuracy and patient-centered outcome variables in guided implant surgery: a RTC comparing immediate with delayed loading. Clin Oral Implants Res. 2015 Mar 28.

TREATMENT PLANNING

The planning phase that precedes a prosthetic treatment allows for the best elaboration, by the clinician, of the prosthetic plan that has to be accomplished according to standardized prosthetic criteria and esthetic rules. (Rufenacht 1990; Goldstein 1976 , Goleman 1987). This phase also makes it possible to give more information to the patient, for a better understanding of the treatment planned.

An additional goal of the diagnostic and prosthetic planning phase is to realize a "trial mock-up", useful both for aesthetic and communication purposes. It could also be useful during the preparation of the teeth, as a guide to the preparation depth for the maximum preservation of the dental substance.

Today a trial mock up can be realized both with traditional methods and with digital methods, by CAD-CAM procedures (Gurrea et al., 2014, Magne et al., 2015, Simon 2008, Reshad et al., 2008, Gurel 2012, McLaren 2013, Cattoni et al., 2016).

The traditional flow of planning and realization of "mock-up" includes:

- intra and extra oral visit and radiographic evaluation;
- recording of extra oral and intraoral images;
- phonetic evaluation with specific tests;
- evaluation of the static and dynamic occlusal status and evaluation and of the actual vertical dimension (VDO) and possible needs for its modification;
- esthetic evaluation of the face, according to fundamental aesthetic criteria such as, for example, the study of the midline and of the bi-pupillary line, the inclination of the incisal plane, and of the occlusal plane, of the shape and size of the teeth;
- recording of preliminary impressions;
- recording of a facebow for the correct positioning of the models in the articulator;
- realization of a plaster model defined as an aesthetic model, usually cast in extra-hard plaster for the evaluation of details;
- correct positioning of the models in the articulator;
- realization of a wax-up, based on the observation of the clinician, on the occlusal status, on functional and phonetic tests. The wax up mimics the new situation proposed with the treatment plan.
- discussion and evaluation of the diagnostic wax up with the patient;
- fabrication of templates or molding guides for the "mock up";
- "mock up" imprint using the silicone template made on the diagnostic wax-up as a guide for the addition of a dual composite material and the positioning in the patient's mouth to mimic the desired final shape.

The digital flow of planning and realization of " mock-up" contemplates:

- intra and extra oral visit and radiographic evaluation;
- recording of extra oral and intraoral images;
- phonetic evaluation with specific tests;
- evaluation of the static and dynamic occlusal status and evaluation and of the actual vertical dimension (VDO) and possible needs for its modification;

- esthetic evaluation of the face, according to fundamental aesthetic criteria such as, for example, the study of the midline and of the bi-pupillary line, the inclination of the incisal plane, and of the occlusal plane, of the shape and size of the teeth;
- registration with an intraoral scanner of a digital impression of the complete upper and lower arch and of the occlusal relationship;
- drawing of the new shape of the teeth using dedicated software, according to the protocol of the manufacturing companies
- discussion and evaluation of the virtual project (2D) with the patient;
- realization through CAD-CAM technology of the planned shape, by transferring STL planning file from 2D to 3D software, matched with the file obtained from the optical impression, and then to CAM for the milling / molding of the test "mock up".

Bibliography

Abbott FB. Psychological assessment of the prosthodontic patient before treatment. Dent Clin of North Am 1984; 28: 361-367.

Abrams RA, Ayers CS, Vogt Petterson M. Quality assessment of dental restorations: a comparison by dentists and patients. Community Dent Epidemiol 1986;14: 317-319.

Bader JD, Shugars DA. Variation in dentists' clinical decision. J Public Health Dent 1995; 55: 181-188.

Cattoni F, Mastrangelo F, Gherlone EF, Gastaldi G. A New Total Digital Smile Planning Technique (3D-DSP) to Fabricate CAD-CAM Mockups for Esthetic Crowns and Veneers.Int J. Dent. 2016 Jul 10.

Friedman JW. Development of criteria and standards for dental care. Dent Clin North Am, 1985: 29: 465-475.

Goldstein RE. Esthetic in dentistry, Philadelphia , Lippincott 1976.

Goleman D Goleman TB Beauty's hidden equation. Ann Health 1987; March.

Gurrea J, Bruguera A. Wax-up and mock-up. A guide for anterior periodontal and restorative treatments; Int J Esthet Dent 2014 Summer;9(2):146-62.

Gurel G, Morimoto S, Calamita MA, Coachman C, Sesma N.Int J Periodontics Restorative Dent. 2012 Dec;32(6):625-35.Clinical performance of porcelain laminate veneers: outcomes of the aesthetic pre-evaluative temporary (APT) technique.

Hall WB, Roberts EW, LaBarre EE. Decision making in dental treatment planning. Mosby- Year Book, 1994. Kress G. Improving patient satisfaction. International Dental Joumal 1987; 37: 117-122.

Magne P.A New approach to the learning of dental morphology, function, and esthetics: the "2D-3D-4D" concept. Int J Esthet Dent; 2015 Spring;10(1):32-47.

McLaren E. Bonded Functional Esthetic Prototype: an alternative pre-treatment mock-up technique and cost-effective medium-term esthetic solution,. Compend Contin Educ Dent. 2013 Sep;34(8):596-607.

Reshad M1, Cascione D, Magne P, J Prosthet Dent. 2008 May;99(5):333-9.Diagnostic mock-ups as an objective tool for predictable outcomes with porcelain laminate veneers in esthetically demanding patients: a clinical report.

Rosenberg MM, Kay HB, Keough BE, Holt RL. Periodontal and prosthetic management for advanced cases. Quintessence Publishing Co., 1988.

Shugars DA, D. Bader. Practice Parameters in Dentistry: Where do we stand? JADA, 1995; 126: 1134-1143.

Simon H., Magne P. Clinically based diagnostic wax-up for optimal esthetics: the diagnostic mock-up. j Calif Dent Assoc 2008 May;36(5):355-62.

Sondell K., Soderfeldt B. Dentist-patient communication: A review of relevant models. Acta Odontol Scand 1997; 55: 116-126.

Tedesco L, Garlapo DA. Social and economic factors in prosthodontic practice and education. Joumal of Prosthetic Dentistry 1994; 71:310-315.

Wilkinson MD. Treatment plans and cost estimates. Br Dental J 1990; 168 (12): 446-458

The use of the aforementioned technology, finds today, an effective application in direct restorations which can be performed in a single operative session, without any lengthening of working time, of waiting time and of the number of sessions (Otto T., 2015). These are "chair side" digital direct restorations that include, in a single session, the preparation of the dental element, the registration of the digital impression, the design and processing of the image, the milling of the product, the try-in and the definitive clinical cementation of the product in the mouth.
However, with this technology it is possible to produce both indirect or semi-direct dental restorations.
For the former, all the DDWF is delegated out of the dental office, therefore to dental laboratories or dedicated production centers. The dentist sends the impression obtained with traditional techniques (trays and impression materials) in the laboratory where a master model is prepared and scanned for the DDWF. The restoration is then designed in the laboratory, then milled in the laboratory itself or sent to an external production center. For the production of semi-directs, a digital impression is registered in the dental office through an intraoral scanner, sent to the laboratory that will realize the restoration. The laboratory can choose whether to realize the whole process " in house" or send part of the digital workflow to external production centers (Bauer F 2008).

The realization of direct digital restorations so called "chair - side", directly in the patient 's oral cavity, is entrusted to those qualified to practice the dental profession, according to the current legal provisions.

With the "chair -side" technology it is possible to realize:

- partial intra and extracoronal reconstructions: inlays, onlays, overlays;
- full and / or partial crowns;
- aesthetic facets or veneering;
- "bridge" prosthetic elements up to three elements;
- single crowns on implants;
- diagnostic impression for orthodontic treatment plans and masticatory function above all if through aligners digitally planned;

- diagnostic impression aimed to the aesthetic treatment plan (smile design) (Zimmermann M 2015)
- diagnostic impression for the realization of acrylic resin devices for guided implant surgery.

The materials * that can be used for the definitive or temporary restoration of the above are (Ametzl GV 2012):

- materials for final restorations: reinforced composite resins, feldspathic ceramics, diescast glass ceramics, lithium disilicate ceramics, zirconia oxide ceramics;
- materials for temporary restorations: polymethylmethacrylate resins;
- acrylic resins (templates for guided implant surgery).

* all the materials mentioned above are specifically produced for the "chair side" of direct, indirect and semi-rigid type in rigid form, in cubes of different sizes and widths, with relative support.

Any direct "chair side" treatment plan, based onto a correct diagnosis, requires:

- **that the oral cavity is in good health and that the periodontium of the teeth close to or involved in the rehabilitation is free of disease;**
- **all the measures must be used to obtain the minimum invasiveness and the greatest economy in biological tissue (Boitelle P 2016);**
- **that all the parameters of digital execution (scanning / optical impression, functional morphology design, milling of the selected material for the restoration) favor the production of a manufactured article that guarantees the precision of the margins and of the occlusal morphology (Tapie L 2015);**
- **that the perfect adhesion of the restoration to the treated dental element is ensured as well as the full biological compliance of the underlying tissues**

It is possible to carry out "chair side" direct restorations, even complex, in a single clinical appointment.

The clinical time to perform a complex restoration, such as a total crown, in high-quality lithium disilicate material, can be estimated over two hours, two hours and thirty, depending on the operator's skills.

By way of example and with reference to operating times, the construction of a complex artifact such as the one indicated above, borne by a first molar of both the upper and lower arch, provides:

- anesthesia, preoperative XRays
- preparation of the dental element
- relief of the optical impression
- CAD phase design
- grinding of the DSL block in CAM phase
- test in the mouth of the prepared item
- DSL crown characterization
- oven firing for ceramics and cooling:
- adhesive cementation
- finishing and occlusal and XRays controls

Bibliography

Ametzl GV , Ametzl G. Reliability of nonretentive all-ceramic CAD/CAM overlays. Int J. Comput dent. 2012; 15(3): 185-97.

Bauer F, Schweiger J, Edelhoff D, Digital dentistry: an overview of recent developments for CAD/CAM generated restorations. Brit. Dent J. 2008; 204; 505-511.

Bindl A, MormannWH. Marginal and Internal fitof all ceramic CAD/CAM crowns copings on chamfer preparation. J.Oral Rehabil 2005; 32: 441-447.

Boitelle P, Tapie L, Mawussi B, Fromentin O, 3D fitting accuracy evaluation of CAD /CAM copings- comparison with spacer design settings. Int J. Comp Dent. 2016; 19(1) : 27-43.

Duret F. Empreinte Optique. Faculté d'Odntologie. MSc Thesis. Lyon:Claude bernarde University, 1973: 1-400.

Duret F. Analysis of Holographic dental image, optical print, CAD and CAM for dental Robotic prosthesis. Revue Sciences et techniques Biomedicale. 1976; 1-8.

Ender, A. Mehl, "In- vitro evaluation of the accuracy of conventional and digital methods of obtaining full-arch dental impressions", Quintessence International, vol 46, no 1, pp. 9-17. 389

Fasbinder DJ: The Cerec System: 25 years of chairside CAD/CAM Dentistry. J. Am Dent. Assoc. 2010: 141 (supl 2): 3s-4s.

Frankenberger R, Hartmann VE, Krech M, Krämer N, Reich S, Braun A, Roggendorf M. Adhesive luting of new CAD/CAM materials. Int J Comput Dent. 2015;18(1):9-20.

G. Krugel, "Impression-taking: conventional methods remain steadfast as digital technology progresses", Compendium of Continuing Education in Dentistry, vol. 35, no.3, pp. 202-203, 2014.

Mormann WH, Brandestini M. Process for the manufacture of medical and dental, alloplastic,endoprosthetic and exoprosthetic fittings. EP0054785B1, priority date 24 dec 1980.

Mormann WH, Bindl A. , Luthy H., Rathke A. Effectsof preparation and luting system on all ceramic computer- generated crowns. Int. J. Prosthod. 1998; 11: 333-339.

Otto T., Schneider D. : Long term clinical results of chairside Cerec CAD/CAM inlays and onlays: a cases series. Int. J. Prosthodont. 2008 Jan-Feb; 21 (1): 53-9.

Otto T, Mormann WH, Clinical performance of Chairside CAD/CAM feldsphatic ceramicposterior shoulder crowns and endocrowns up to 12 years. Int,J.of Comp. Dent. 2015; 18(2): 147-161.

Posselt A., Kerschbaum T. Longevity of 2328 chairside Cerec inlays and onlays. Int J. Comput dent. 2003 Jul;(3): 231- 48.

Reiss B. Clinical results of Cerec inlays in a dental practice over a period of 18 years. Int.J Comput dent 2006 Jan; 9(1):11-22.

Schleyer TK. Why integration is key for dental office technology. J Am Dent Assoc 2004;135(suppl):4S-9S.

Tapie L., Lebon N., Mawussi B., Fron Chabouis H., Duret F., Attal JP. Understanding dental CAD/CAM for restorations-the digital workflow from a mechanical engineering viewpoint. Int J of Comp Dent 2015; 18(1):21-44.

Van Noort R. The future of dental devices is digital. Dent Mater 2012; 28:3-12.

Widhahan K., Fritzsche G., Widhahan C, Schenk O. Zirconia crowns – the new standard for single-visit dentistry? Int J. Comp. Dent. 2016; 19(1): 9 – 26.

Zimmermann M, Mehl A.: Virtual smile design-Systems: a current review. Int. J. of Comp Dent. 2015; 18 (4) : 303-317.